

AN INCIDENTALLY DETECTED CASE OF ATYPICAL BRONCHIAL CARCINOID IN  
STRESS MYOCARDIAL PERFUSION SPECT/CT

Komal Bishnoi<sup>1</sup>, Girish Kumar Parida<sup>1</sup>, Ralph Emerson<sup>1</sup>, Kanhaiyalal Agrawal<sup>1</sup>, Amit Kumar Adhya<sup>2</sup>

Author affiliations:

<sup>2</sup>Department of Nuclear Medicine, All India Institute of Medical Sciences, Bhubaneswar, India

<sup>1</sup>Department of Pathology and Lab Medicine, All India Institute of Medical Sciences, Bhubaneswar, India

Corresponding Author:

Dr Girish Kumar Parida, MD.

Assistant Professor

Department of Nuclear Medicine

All India Institute of Medical Sciences

Bhubaneswar- 751019, India

Phone: 91-9968856817

Email: grishh135@hotmail.com

- Manuscript type – Case report

Running title – Bronchial carcinoid in stress MPI

- No funding received from any organization for this study.
- The authors declare that there is no conflict of interest.

## Abstract

Myocardial perfusion imaging (MPI) is primarily done to look for stress induced perfusion defects in patients suspected of coronary artery disease. However, the rotating raw images can provide a significant information regarding surrounding structures. The lungs lie in close proximity to heart and any abnormality showing increased uptake can be seen on MPI. We report a case of 52-year-old man, with history of Diabetes for last five years, who presented to cardiac outpatient department (OPD) for occasional chest pain and dyspnea. Electrocardiogram (ECG) and echocardiography showed no significant abnormality. Patient was referred to nuclear medicine department for stress induced myocardial perfusion scintigraphy. The raw <sup>99m</sup>Tc sestamibi images were showing abnormal uptake in right lung hilar region which on subsequent investigations was diagnosed as a case of atypical bronchial carcinoid tumor.

Keywords: Myocardial perfusion imaging, <sup>99m</sup>Tc sestamibi, Atypical bronchial carcinoid tumor

## *Introduction*

Myocardial perfusion imaging (MPI) using single photon emission computed tomography (SPECT) continues to be an important non-invasive tool for clinicians to evaluate suspected or known CAD, often used in conjunction with other screening measures. However, in addition to the cardiac findings, extra-cardiac incidental findings can also be seen on the rotating raw SPECT images and/or the CT used for attenuation correction when utilized. There are case reports on such incidental findings during MPI. These findings may lead to an early diagnosis and treatment of disease at very early stage. Sestamibi uptake in lung cancer, breast cancer, lymphoma, peripheral soft tissue, bone sarcoma, etc. has been reported in literature, but very rarely reported in carcinoid tumors [1,2]. We present a case of atypical carcinoid, incidentally detected on the stress MPI.

## *Case Report*

Fifty-two-year-old man with history of diabetes, since last five years, presented to cardiology OPD with occasional midline chest pain and dyspnea. The physician ordered cardiac investigations including cardiac markers, ECG, echocardiography which revealed no significant abnormality. Subsequently stress MPI was advised to rule out inducible ischemia. The patient underwent exercise stress test and the raw images showed 99m-Tc sestamibi uptake in right hemithorax adjacent to the myocardial uptake (arrows in Figure 1A, 1B) . The NCCT images which were acquired for attenuation correction showed soft tissue density lesion in close relation to right main bronchus (arrow in Figure 1C). The patient underwent video bronchoscopy which showed growth at right main bronchus occluding the lumen. The bronchoscopic biopsy at first was suggestive of a typical carcinoid tumor. Then, the patient underwent right upper lobectomy for the same. The final surgical HPE was suggestive of atypical carcinoid tumor (Figure 1D : Section shows respiratory epithelium and a tumor is seen in the subepithelium. H & E stain, 200x; Figure E: The tumor cells are arranged in nests, rosettes, trabeculae and cords. H & E stain, 400x) involving right main bronchus without adjacent lung parenchymal invasion.

## *Discussion*

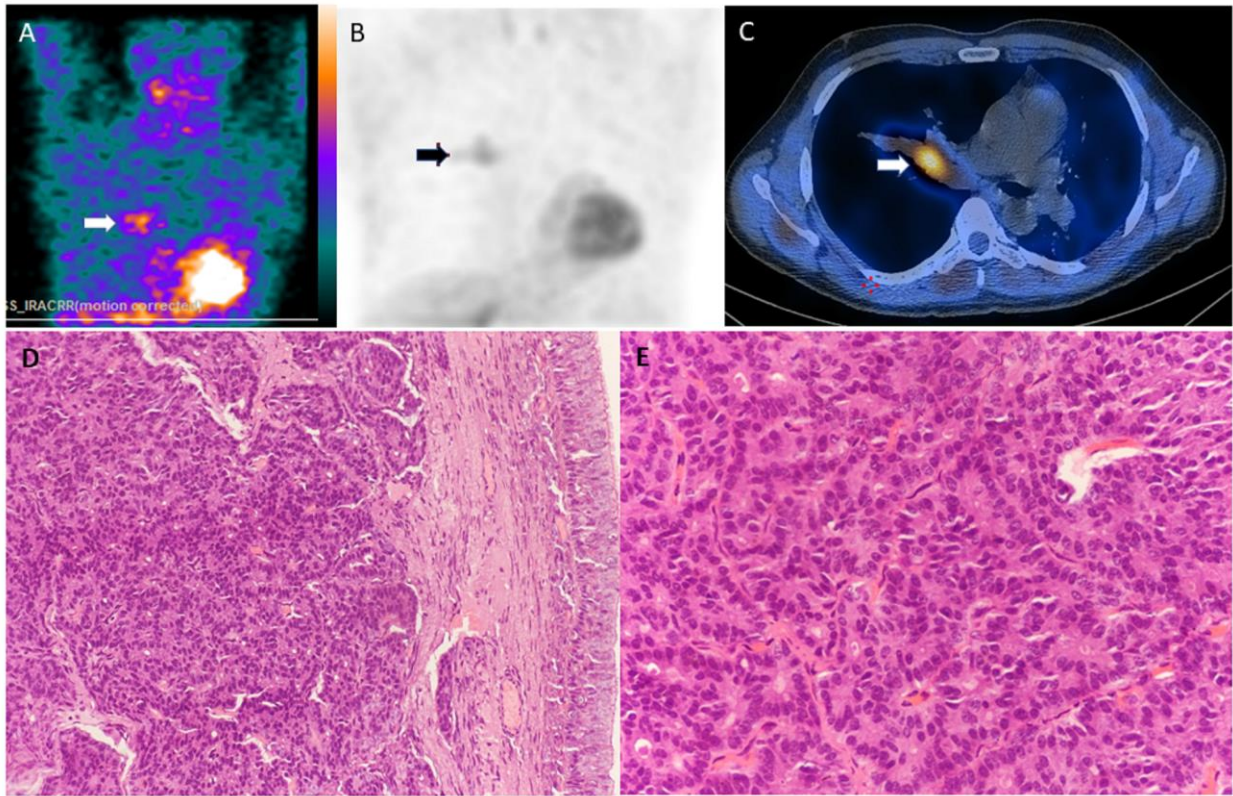
There are three main areas of origin for carcinoid tumors: foregut carcinoid tumors start in the lungs, bronchi, or stomach; midgut carcinoid tumors start in the small intestine, appendix, or proximal large bowel; and hindgut carcinoid tumors start in the distal colon or rectum. The

appendix is the most common site of carcinoid tumors, followed by the rectum, ileum, lungs, bronchi, and stomach (3). The main treatment options include surgery, chemotherapy, and radiation with somatostatin analogues such as octreotide (Sandostatin) or alpha-interferon. Importantly, the most common cause of carcinoid syndrome is metastatic liver disease arising from a small bowel carcinoid tumor. For these patients, the prognosis is uniformly poor. Meta-iodobenzylguanidine (MIBG) is a structural analogue to norepinephrine, and I-labelled MIBG can be used for the detection of neuroendocrine tumors (5). However, the tumor is mostly asymptomatic, delaying the diagnosis. Incidentally diagnosed carcinoid tumors on sestamibi scan are rarely reported (1,2). In the present case report, we had an incidental finding of atypical carcinoid tumor of lung on rotating raw SPECT images of patient undergoing Myocardial perfusion imaging (MPI) with <sup>99m</sup>Tc-sestamibi. These findings may lead to an early diagnosis requiring further treatment and a possibly improved prognosis of the patient. Therefore, careful evaluation of non-cardiac findings needs to be performed.

*References:*

1. Malik D, Sood A, Parmar M, Sood A, Radotra B, Mittal B. Incidental detection of bronchial carcinoid on Tc-99m sestamibi SPECT/CT myocardial perfusion scintigraphy. *J Nucl Cardiol.* 2017;24:319-22.
2. Gedik GK, Ergu'n EL, Asian M, Caner B. Unusual extracardiac findings detected on myocardial perfusion single photon emission computed tomography studies with Tc-99m sestamibi. *Clin Nucl Med.* 2007;32:920-26.
3. Godwin JD II. Carcinoid tumors. An analysis of 2,837 cases. *Cancer.* 1975;36:560–69.
4. de Vries H, Verschueren RC, Willemse PH, Kema IP, de Vries EG. Diagnostic, surgical and medical aspect of the midgut carcinoids. *Cancer Treat Rev.* 2002;28:11–25.
5. Horton KM, Kamel I, Hofmann L, Fishman EK. Carcinoid tumors of the small bowel: a multitechnique imaging approach. *AJR Am J Roentgenol.* 2004;182:559–67.

## Figure legend



A & B : SPECT images, showing focal tracer uptake in the right hemithorax adjacent to the myocardium. C: Fused SPECT/CT image showing tracer avid intrabronchial soft tissue density lesion in right main bronchus. D: Section shows respiratory epithelium. A tumor is seen in the subepithelium. H & E stain, 200x. E: The tumor cells are arranged in nests, rosettes, trabeculae and cords. H & E stain, 400x.