

Rare Multisystem Histiocytic Sarcoma on F18-FDG PET/CT

Matthew Harwood¹, M.D., Fiona E. Craig, M.D.², Ming Yang, M.D.¹

Department of Radiology¹ and Laboratory Medicine and Pathology²

Mayo Clinic Arizona

Corresponding Author:

Ming Yang, M.D.

Department of Radiology

Mayo Clinic Arizona

13400 E. Shea BLVD

Scottsdale, AZ 85259

Tel: 480-342-0988

Email: Yang.ming@mayo.edu

Disclosure: This case report did not receive funding, and the authors have no conflicts of interest to disclose.

Manuscript Word Count: 744

Running title: Multisystem Histiocytic Sarcoma on PET/CT

Abstract:

Histiocytic sarcoma (HS) is a rare malignancy with morphological and immunophenotypic features indicating histiocytic differentiation. We present a case of histiocytic sarcoma with multisystem involvement, including an obstructing pancreatic head mass. F18-FDG PET/CT is a valuable tool in staging and assessment of response to therapy in this rare entity. Knowing the diverse metastatic pattern of HS will help avoid imaging pitfalls for the diagnosis after pathologic diagnosis is made.

Key words: histiocytic sarcoma, FDG, PET/CT, pancreas

Introduction:

Histiocytic sarcoma is a rare neoplasm of myeloid-derived macrophages. The exact etiology is unclear. It occurs predominantly in adults and is associated with poor survival (1). Histiocytic sarcoma may involve lymph nodes and many organs, and hypermetabolic on F18-FDG PET/CT. Diagnosis of HS relies on demonstration of histopathological evidence of histiocytic differentiation, i.e., CD68 and CD163, and exclusion of other malignancies, including large B-cell lymphoma, T/NK-cell lymphoma, and other histiocytic and dendritic neoplasms.

Case Report:

A 51-year-old woman presented with progressively worsening back pain. Thoracic spine MRI demonstrated a large mass centered at T7 level and infiltrating the bilateral T7 and T8 neural foramen, as well as adjacent ribs. The patient underwent T6-T8 decompression and tumor debulking to relieve back pain. Histopathological evaluation of the intraspinal, extradural mass lesion demonstrated large anaplastic cells, mitotic activity, and admixed lymphocytes and eosinophils. Immunohistochemical stains showed the large tumor cells to be positive for CD4, CD10, CD45, CD68, CD163, and negative for markers of a plasma cell neoplasm (CD 138 immunoglobulin light chain negative), Hodgkin lymphoma (CD30, CD15), Langerhans cell sarcoma (CD1a) or dendritic cell sarcoma (CD21, CD35). A diagnosis of histiocytic sarcoma (HS) was established.

Shortly after surgery, the patient presented with acute right upper quadrant and epigastric pain, which worsened after meals, as well as jaundice and pruritus. Contrast-enhanced CT scan showed an ill-defined pancreatic head mass with bile duct dilation and main pancreatic duct dilation. On F18-FDG PET/CT, there were multiple hypermetabolic lesions including the pancreatic head mass (Fig. 1). The patient underwent three cycles of chemotherapy under the

CHOP regimen (cyclophosphamide, doxorubicin, vincristine and prednisolone) and demonstrated favorable response to therapy.

Discussion:

Histiocytic sarcoma (HS) is a rare histiocyte disorder with a slight male predominance (2). Since HS may involve multisystem, its clinical manifestation varies and may present as multifocal hypermetabolic extra-nodal disease on F18-FDG PET/CT (2-4). Pancreatic involvement in HS is extremely rare and may mimic other pancreatic malignancies. Ultimate diagnosis of HS relies on histopathological evidence of histiocytic differentiation within involved tissue and exclusion of other malignancies, including large B-cell lymphoma and other histiocytic and dendritic neoplasms (5). There is no standard treatment for HS and CHOP regimen might be acceptable for multifocal disease. Although HS might exhibit favorable response to chemotherapy, the long-term survival rate is poor (1). F18-FDG PET/CT may allow us to delineate the extent of HS, guide biopsy and assess treatment response.

Conclusion:

It is important to be familiar with the widespread multisystem pattern of histiocytic sarcoma. F18-FDG PET/CT is valuable tool in staging and surveillance of this rare entity.

References:

1. Takahashi E, Nakamura S. Histiocytic sarcoma: an updated literature review based on the 2008 WHO classification. *J Clin Exp Hematop.* 2013;53:1-8.
2. Saboo SS, Krajewski KM, Shinagare AB, Jagannathan JP, Hornick JL, Ramaiya N. Imaging features of primary extranodal histiocytic sarcoma: Report of two cases and a review of the literature. *Cancer Imaging.* 2012;12:253-258.
3. Fernández-Aceñero MJ, Pérez Alonso P, Díaz del Arco C. Histiocytic sarcoma with bladder involvement: Case report and literature review. *Rev Esp Patol.* 2018;51:23-26.
4. Makis W, Ciarallo A, Derbekyan V, Lisbona R. Histiocytic sarcoma involving lymph nodes: Imaging appearance on Gallium-67 and F-18 FDG PET/CT. *Clin Nucl Med.* 2011;36:e37-e38.
5. Swerdlow SH, Campo E, Harris NL et al. *WHO Classification of Tumours of Haematopoietic and Lymphoid Tissues.* Revised 4th Edition, 2011.

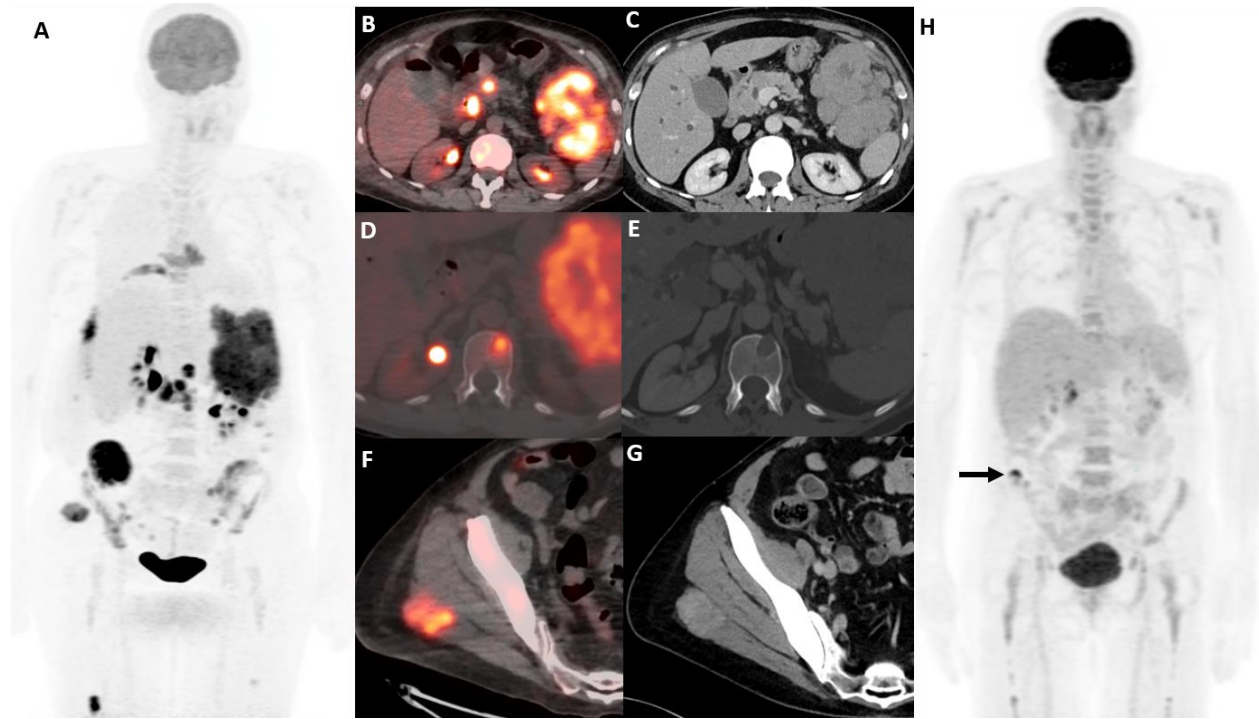


Figure 1. On the staging F18-FDG PET/CT MIP image (A), there are multiple hypermetabolic metastases, including an obstructive pancreatic head mass, large left upper quadrant mass, lytic lesion in the T12 vertebral body, and right gluteus maximus muscle lesion on PET/CT fusion (B, D & F) and corresponding contrast enhanced diagnostic CT (C, E, G). After three cycles of chemotherapy, follow-up F18-FDG PET/CT showed near-complete response and a small residual tracer-avid focus in the right iliac wing (arrow in H).