

Case Study: FDG and Amyloid PET in Dementia

Lance D Burrell MS, CNMT, PET, RT(CT)¹, Dawn Holley, BSc, CNMT, RT(N)(CT)²

¹Center for Quantitative Cancer Imaging, Huntsman Cancer Institute, University of Utah,

²Stanford University

For correspondence contact: Lance Burrell, 2000 Circle of Hope, Salt Lake City, UT 84112 USA

Email: lance.burrell@hci.utah.edu

Word Count: 695

Abstract

We present a case of memory loss and aphasia in a 72-y-old male, and discuss how PET imaging supported a diagnosis of Alzheimer's dementia despite conflicting clinical findings.

Introduction

PET imaging of the brain is useful for the clinical evaluation of dementia (1). Amyloid PET imaging adds information to current standard of FDG PET metabolic imaging (2).

Case Report

A 72-y-old male presented with complaints of memory loss, aphasia and involuntary movements. Neuropsychological testing reported multiple areas of cognitive deficits and the indication of functional decline. These findings supported a diagnosis of an early dementia with an unclear etiology. Some indicators suggested Alzheimer's disease (AD) as the pathological condition, while others suggested frontotemporal dementia (FTD). Relatively early onset of the cognitive symptoms is more suggestive of FTD than AD.

CT imaging revealed global atrophy of the cerebrum and cerebellum without evidence of lobar pattern dementia (Figure 1). The second clinical visit report stated that this patient had an atypical dementia syndrome with prominent language deficits. Included in the differential diagnosis were language predominant AD and progressive aphasia due to FTD. Cognitive decline had been present for at least 6 months. A dementia syndrome was present and clinical criteria were met for both AD and FTD.

An FDG PET scan was ordered. The patient fasted for 6 hours and the resulting blood glucose was 84 mg/dl. 9.58 mCi of 18-F FDG was injected intravenously. 30 minutes later, a 30-minute PET/CT scan of the brain was obtained. The FDG PET report indicated that the observed metabolic pattern was not classic for a specific neurodegenerative process. Early FTD could not be totally excluded, but was unlikely. The lack of a metabolic reduction in the frontal and anterior temporal cortex made the diagnosis of primary progressive aphasia, a subtype of FTD, unlikely. Early AD was a possible diagnosis due to the metabolic reductions noted in the left lateral temporal, parietal and precuneus cortex (Figure 2).

To further delineate the characteristics of this patient's dementia, a beta amyloid PET scan was ordered. 4.79 mCi of Vizamyli™ (flutemetamol F-18 Injection) was injected intravenously. 90 minutes later, a 20-minute PET/CT scan of the brain was acquired. The scan was positive for cortical beta amyloid with diffuse prominent uptake throughout the cerebral cortex and basal ganglia (Figure 3).

Discussion

PET imaging is useful in atypical cases where clinical evaluation, neuropsychological testing and anatomical imaging point to more than one potential diagnosis. PET imaging should be leveraged in the appropriate clinical scenario. In this case study, the patient clinically had symptoms of both AD and FTD. ¹⁸FDG PET imaging added information about the metabolic changes that aligned better with AD, and the beta amyloid PET imaging further supported this diagnosis. This high degree of clinical diagnostic certainty based on PET imaging, despite an atypical presentation, allowed clinicians to initiate proactive care planning.

Conclusion

Clinical symptoms of cognitive impairment can point to a variety of diagnoses. Appropriate use of advanced PET imaging can support clinical decision making and lead to the most accurate diagnosis for the patient.

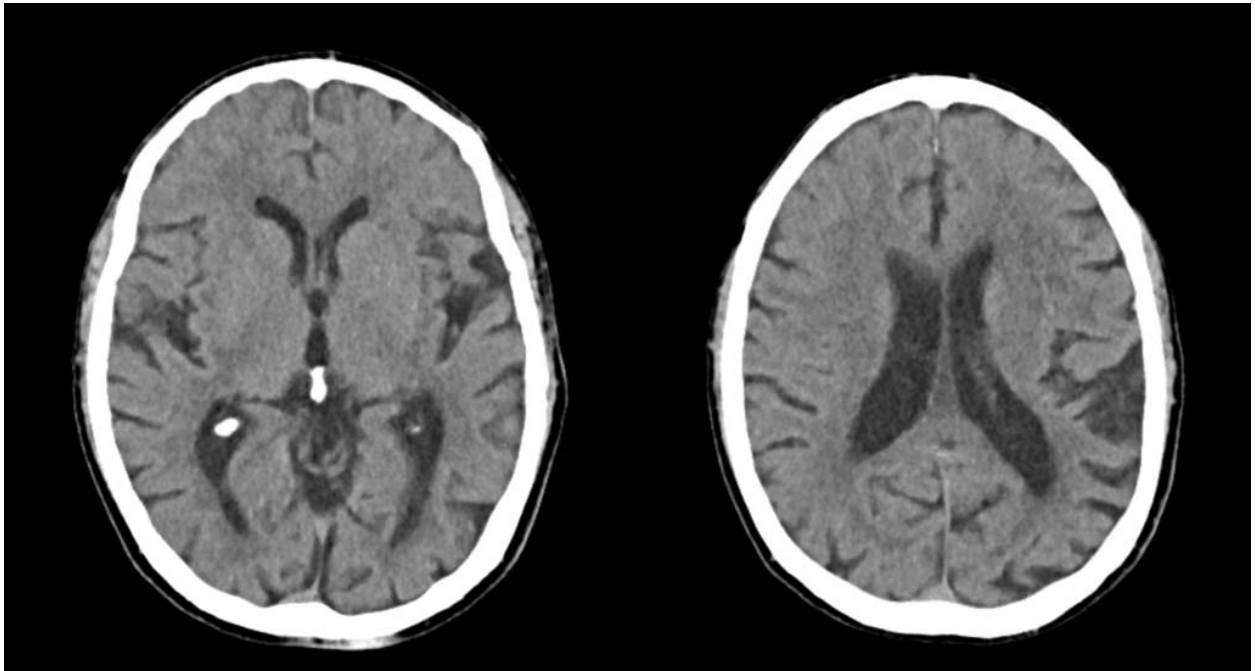
Acknowledgments

This case study was prepared as part of the Brain Tech TIME initiative of the SNMMI-TS.

References

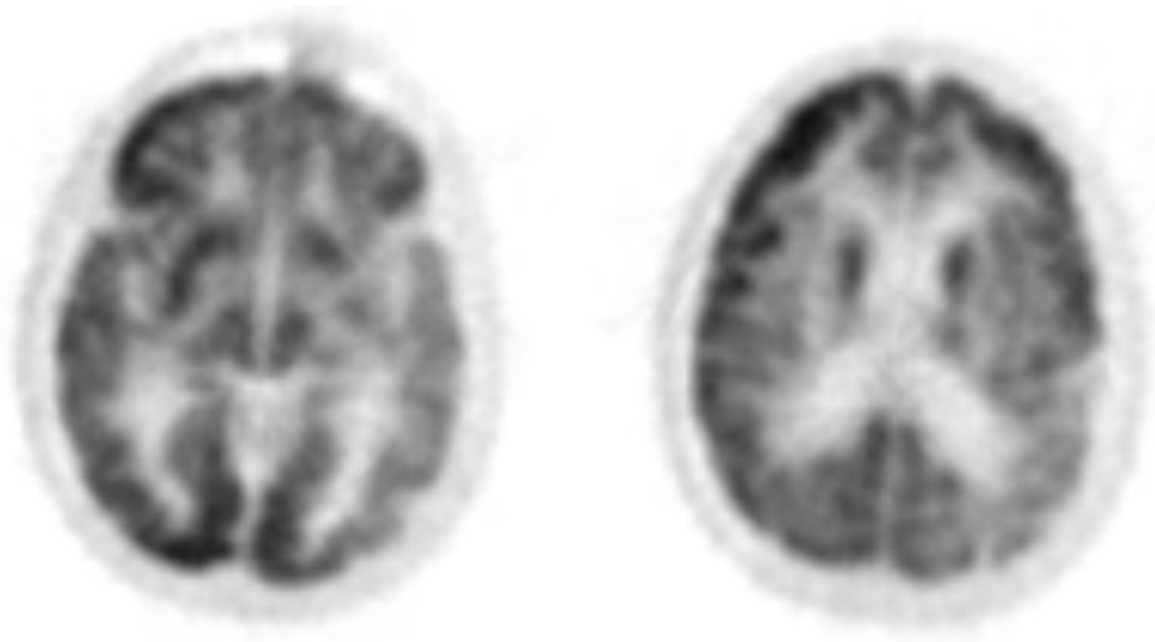
1. Bohnen N, Djang D, Herholz K, Anzai Y, and Minoshima S. Effectiveness and Safety of 18F-FDG PET in the Evaluation of Dementia: A Review of the Recent Literature. *J Nucl Med*. 2012;53:59-71.
2. Johnson K, Minoshima S, Bohnen N, et al. Appropriate Use Criteria for Amyloid PET: A Report of the Amyloid Imaging Task Force, the Society of Nuclear Medicine and Molecular Imaging, and the Alzheimer's Association. *J Nucl Med*. 2013;54:476-490.

Figure 1



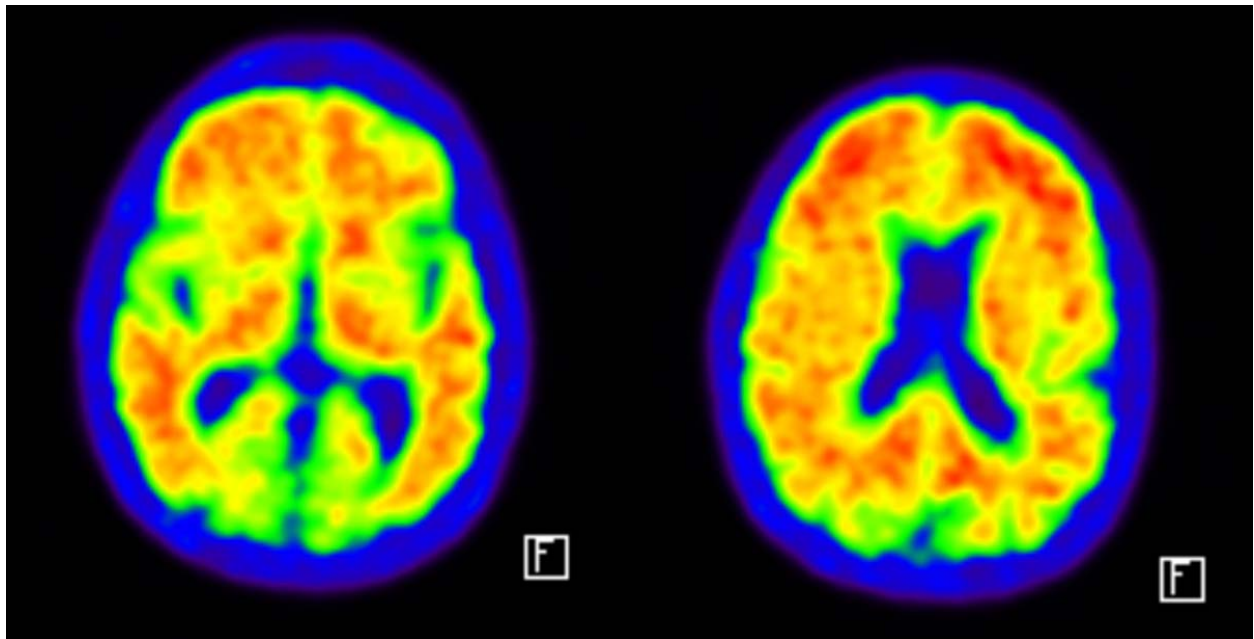
Midline axial CT images of the brain showing cerebral atrophy.

Figure 2



Midline axial ^{18}F FDG PET images of the brain showing cortical metabolic reductions.

Figure 3



Midline axial ^{18}F -Flutemetamol PET images of the brain demonstrating the presence of beta amyloid plaques.