

**Title page**

**Malignant peripheral nerve sheath tumours of the pericardium in a patient with Neurofibromatosis type 1: The diagnostic value of 18F-FDG PET-CT and I-123 MIBG SPECT-CT**

Mathieu Charest, MD<sup>1</sup>, Josephine Pressacco, MD<sup>2</sup>, Jaramie Thomas-Gittens, BSc, MD, CM<sup>3</sup>

1. Nuclear Medicine Department, Hôpital du Sacré-Coeur de Montréal, Montréal, Canada
2. Radiology Department, Hôpital du Sacré-Coeur de Montréal, Montréal, Canada
3. Radiology Department, Université de Montréal, Montréal, Canada

**This manuscript has not been published previously nor is it under consideration by any other journal**

**Correspondence information:** Mathieu Charest, MD, FRCPC  
Phone: 1-514-338-2222  
Fax: 1-514-338-3686  
mathieu.charest@gmail.com  
Hôpital du Sacré-Coeur de Montréal  
5400, boul. GouinOest  
Montréal, Québec, Canada, H4J 1C5

**Funding:** none

**Key Words:** Malignant peripheral nerve sheath tumours, neurofibromatosis type 1, pericardium, anterior mediastinum, FDG, PET-CT, MIBG, SPECT-CT

**Compliance with Ethical Standards**

Conflict of Interest: The authors declare that they have no conflict of interest.

All procedures performed in studies involving human participants were in accordance with the ethical standards of the institutional and/or national research committee and with the 1964 Helsinki declaration and its later amendments or comparable ethical standards.

For this type of study formal consent is not required.

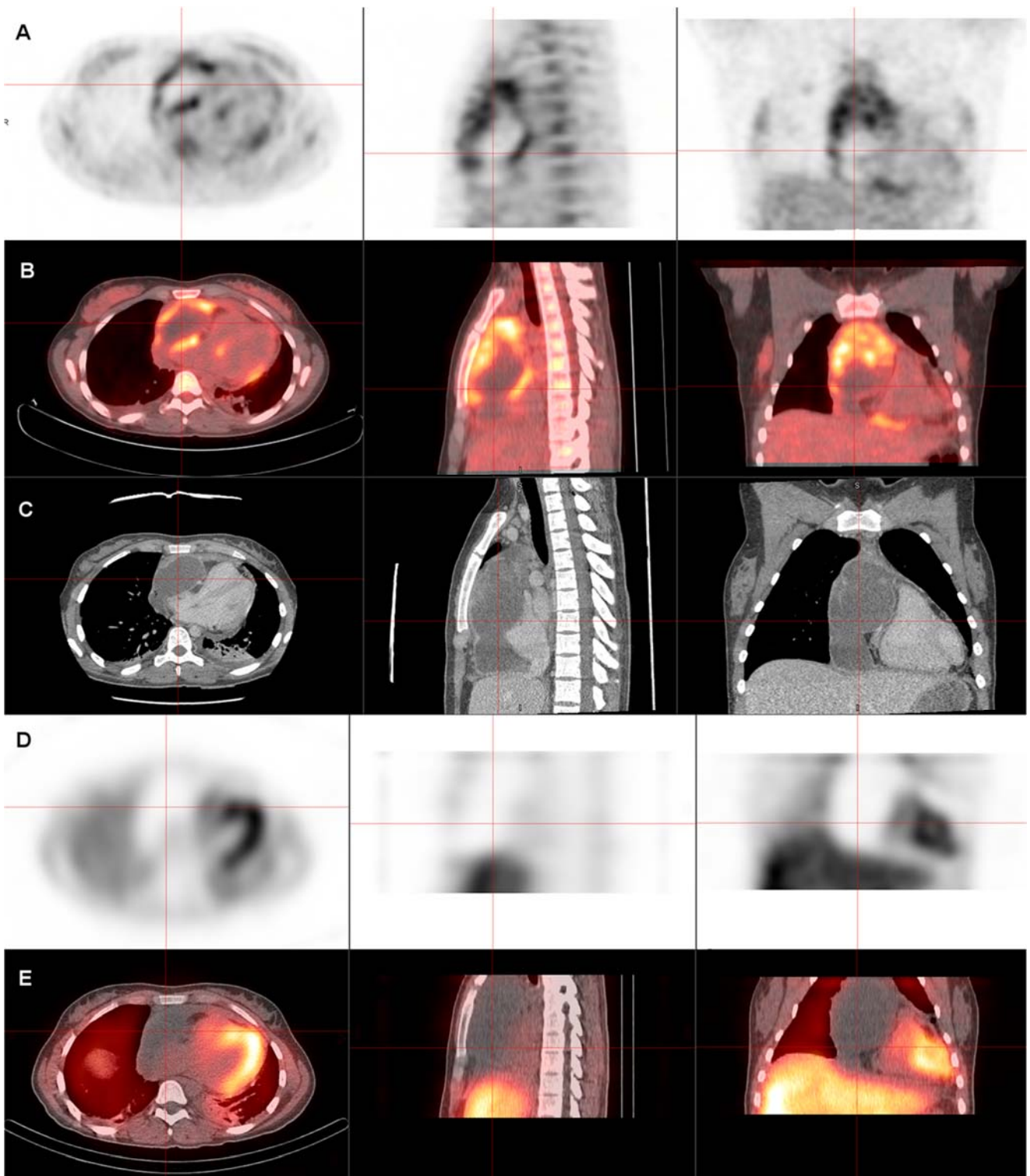
Running title: MPNST of the pericardium

## **Abstract**

A 25 year old female with known neurofibromatosis type 1 with a large anterior mediastinal mass was investigated. 18F-FDG PET-CT revealed a radiotracer avid anterior mediastinal mass with SUVmax of 4.3 and demonstrating a hypoactive center. The Iodine-123 MIBG SPECT-CT study performed subsequently did not demonstrate any uptake, thereby excluding for the most part the diagnoses of paraganglioma or neuroblastoma. At final pathology, a malignant peripheral nerve sheath tumour (MPNST) of the pericardium with areas of chondrosarcomatous and angiosarcomatous differentiation was diagnosed.

### **Case report**

A 25 year old female with known neurofibromatosis type 1 (NF1) came to the emergency room complaining of palpitations and chest pain. The initial work-up including thoracic computed tomography revealed a large pericardial collection. Subsequent to the pericardiocentesis, a large anterior mediastinal mass was demonstrated by cardiac ultrasound, that then lead to further investigation.



18F-FDG PET-CT images (Figure 1-A and 1-B) along with corresponding slices of a contrast-enhanced thoracic computed tomography (Figure 1-C) revealed a radiotracer avid anterior mediastinal mass with SUVmax of 4.3 and demonstrating a hypoactive center. The tumor-to-liver ratio was measured at 2.85. The mediastinal mass was deemed malignant based on these findings. No distant active lesion was detected.

The Iodine-123 MIBG SPECT-CT study (Figure 1-D and 1-E) performed subsequently did not demonstrate any radiotracer uptake by the mediastinal mass, thereby excluding for the most part the diagnoses of paraganglioma or neuroblastoma.

At final pathology from the surgical resection of the lesion, a malignant peripheral nerve sheath tumour (MPNST) of the pericardium with areas of chondrosarcomatous and angiosarcomatous differentiation was diagnosed.

**Discussion:**

Although very rare in the general population (less than 0.1%), neurofibromatosis patients carry up to 10% lifetime risk of developing MPNST (1). 18F-FDG PET-CT was found to be highly sensitive and specific for the diagnosis of MPNST in NF1 patients (1), (2),(3). Warbey et al. reported a sensitivity of 0.97 and specificity of 0.87 using a cut-off SUVmax of 3.5 (4). Salamon et al. proposed a tumour-to-liver ratio of > 2.6 as being more specific (5). Both of these criteria were met in our case.

**Conclusion:**

The combination of 18F-FDG and Iodine-123 MIBG allowed us to correctly orient the diagnosis toward a primary malignant tumour of the pericardium and characterise its heterogeneity.

## References

1. Benz MR, Czernin J, Dry SM, et al. Quantitative F18-fluorodeoxyglucose positron emission tomography accurately characterizes peripheral nerve sheath tumors as malignant or benign. *Cancer*. 2010;116:451-458.
2. Khiewvan B, Macapinlac HA, Lev D, et al. The value of <sup>18</sup>F-FDG PET/CT in the management of malignant peripheral nerve sheath tumors. *Eur J Nucl Med Mol Imaging*. 2014;41:1756-1766.
3. Maurer AH, Burshteyn M, Adler LP, Steiner RM. How to differentiate benign versus malignant cardiac and paracardiac 18F FDG uptake at oncologic PET/CT. *Radiographics*. 2011;31:1287-1305.
4. Warbey VS, Ferner RE, Dunn JT, Calonje E, O'Doherty MJ. [<sup>18</sup>F]FDG PET/CT in the diagnosis of malignant peripheral nerve sheath tumours in neurofibromatosis type-1. *Eur J Nucl Med Mol Imaging*. 2009;36:751-757.
5. Salamon J, Veldhoen S, Apostolova I, et al. 18F-FDG PET/CT for detection of malignant peripheral nerve sheath tumours in neurofibromatosis type 1: tumour-to-liver ratio is superior to an SUVmax cut-off. *Eur Radiol*. 2014;24:405-412.