

Use of SPECT/CT with ^{99m}Tc -MDP Bone Scintigraphy to Diagnose Sacral Insufficiency Fracture

Zaid al-Faham, John N. Rydberg, and Ching-Yee Oliver Wong

Department of Diagnostic Radiology and Molecular Imaging, Oakland University William Beaumont School of Medicine and Health System, Royal Oak, Michigan

Bone SPECT/CT offers additional information on pelvic insufficiency fractures, especially when there is incomplete formation of the H-sign on planar bone scanning.

Key Words: bone; SPECT/CT; Honda sign; sacral insufficiency fracture; SPECT

J Nucl Med Technol 2014; 42:1-2

DOI: 10.2967/jnmt.114.137547

In this report, we present an elderly man with lower back pain secondary to sacral insufficiency fracture. We demonstrate the rare Honda sign that allowed diagnosis of this important clinical abnormality on bone scanning with limited SPECT/CT to the lumbar spine region and sacral region.

CASE REPORT

A 74-y-old man with a history of L1 through L4 laminectomy and fusion within the past year who had undergone high-dose brachytherapy for prostate cancer 2 y ago presented with complaints of lower back pain for the past 3 mo. There was no reported history of a traumatic event. A bone scan was ordered to evaluate the cause of the pain. After intravenous administration of 1,010 MBq (27.3 mCi) of ^{99m}Tc -medronate, anterior and posterior whole-body bone scans were obtained. SPECT/CT imaging was also performed to include the regions of the lumbar spine and sacrum. The bone scan and SPECT/CT images showed vertical linearly increased uptake in the medial to bilateral sacroiliac joint and

[Fig. 1] horizontal increased uptake connecting the vertical lines (H-shaped uptake) in the sacral region (Figs. 1 [planar bone scan] and 2 [SPECT/CT bone scan]).

DISCUSSION

Sacral insufficiency fracture is a type of stress fracture that occurs when a weakened bone with decreased elastic resistance undergoes normal or physiologic stress (*1*). Sacral insufficiency fractures are most common in elderly women with lower back

pain. Severe back pain can be caused by insufficiency fractures involving the sacrum; it is important to identify this abnormality, as it is treatable and often underreported (*2*). Possible risk factors for sacral insufficiency fracture include but are not limited to osteoporosis, rheumatoid arthritis, prolonged corticosteroid treatment, and pelvic irradiation (*2*).

The use of MR imaging, CT scanning, PET/CT, and bone scintigraphy to diagnose sacral insufficiency fractures has been described in literature (*3*). However, bone scanning is one of the most sensitive techniques for detecting such fractures. Unlike highly sensitive planar imaging, SPECT/CT scanning directly correlates bone scan findings with anatomic structures. This is particularly important when there is an incomplete Honda sign or coexisting sacroiliitis. The H-shaped (Honda sign) uptake is diagnostic for sacral insufficiency fracture in the proper clinical settings (*4*). The classic H pattern is formed when there are fractures of both sacral alae and a horizontal component involving the sacral body (*2*). To our knowledge, this is the first case report that has described the H-shaped pattern of sacral insufficiency fracture by SPECT/CT. Recognition of the Honda sign is important when reporting the findings for bone scanning with SPECT/CT to avoid misinterpretation of the uptake.

CONCLUSION

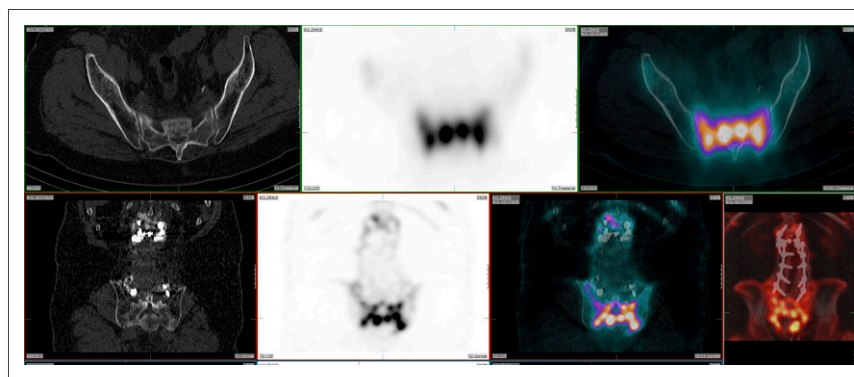
We have demonstrated a rare case in which the Honda sign on bone scanning with SPECT/CT led to the diagnosis of sacral insufficiency fracture. This case suggests that a sacral

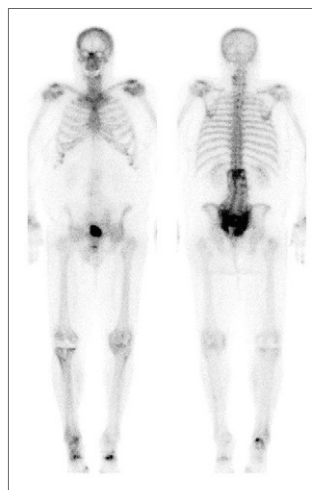

FIGURE 1. Anterior (left) and posterior (right) whole-body bone scan images showing classic H-sign in posterior view of pelvis. Some postoperative changes are noted in lumbar screws and right knee prosthesis, and degenerative changes are also seen in cervical spine and appendicular joints.

Received Jan. 15, 2014; revision accepted Feb. 18, 2014.
For correspondence or reprints contact: Zaid Al-Faham, William Beaumont Hospital, 3601 W. 13 Mile Rd., Royal Oak, MI 48073.
E-mail: zaid.al-faham@beaumont.edu
Published online
COPYRIGHT © 2014 by the Society of Nuclear Medicine and Molecular Imaging, Inc.

FIGURE 2. CT, SPECT, SPECT/CT images including lumbar spine region and sacral region area. In top row, from left to right, axial CT shows normal findings and corresponding SPECT and fused SPECT/CT images show intense bone uptake. In bottom row, from left to right, screws are seen on coronal CT, corresponding intense pelvic uptake is seen on SPECT and fused SPECT/CT, and spinal screws are seen on fused SPECT/CT.



RGB

insufficiency fracture should be suspected when a similar pattern is encountered. Recognition of the sign may help in the early detection and management of sacral insufficiency fracture.

DISCLOSURE

No potential conflict of interest relevant to this article was reported.

REFERENCES

1. Davies AM. Stress lesions of bone. *Curr Imaging*. 1990;2:209–216.
2. Peh WC, Khong PL, Yin Y, et al. Imaging of pelvic insufficiency fractures. *Radiographics*. 1996;16:335–348.
3. Tsuchida T, Kosaka N, Sugimoto K, Itoh H. Sacral insufficiency fracture detected by FDG-PET/CT: report of 2 cases. *Ann Nucl Med*. 2006;20:445–448.
4. Schneider R, Yacovone J, Ghelman B. Unsuspected sacral fractures: detection by radionuclide bone scanning. *AJR*. 1985;144:337–341.