

# Steroid-Induced Activated White Adipose Tissue Detected on $^{18}\text{F}$ -FDG PET/CT

Tejasvini Singhal, Girish Kumar Parida, Parneet Singh, Pramit Kumar, Ralph Emerson, and Kanhaiyalal Agrawal

Department of Nuclear Medicine, All India Institute of Medical Sciences, Bhubaneswar, India

White adipose tissue (WAT) usually shows negligible  $^{18}\text{F}$ -FDG uptake due to negligible glucose utilization. However, corticosteroids alter the biodistribution of  $^{18}\text{F}$ -FDG and increase uptake in WAT. Here, we present a case of diffusely increased  $^{18}\text{F}$ -FDG uptake in WAT secondary to high-dose corticosteroid therapy for nephrotic syndrome.

**Key Words:** corticosteroid; white adipose tissue;  $^{18}\text{F}$ -FDG PET/CT

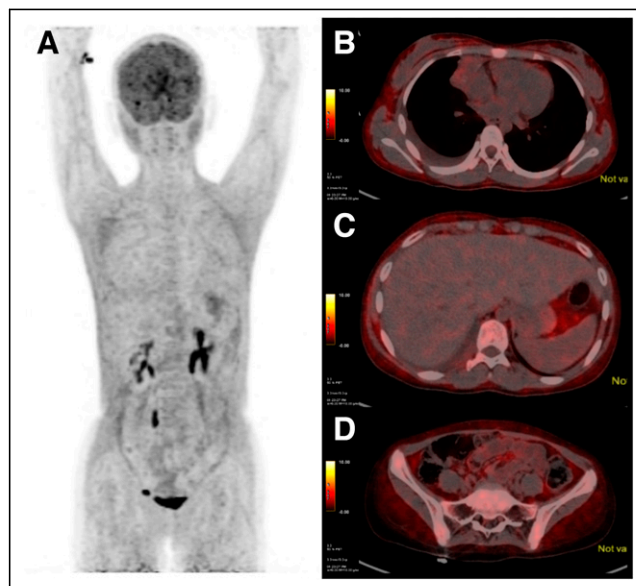
**J Nucl Med Technol 2023; 51:158–159**

DOI: 10.2967/jnmt.122.265320

**A** 12-y-old girl with a known case of lymphoma was referred to the Department of Nuclear Medicine for end-of-treatment PET/CT after 4 cycles of chemotherapy (doxorubicin, bleomycin, vinblastine, and dacarbazine). The patient had also been receiving prednisolone (2 mg/kg of body weight per day) for 2 wk for nephrotic syndrome. The patient was prepared for  $^{18}\text{F}$ -FDG PET/CT with overnight fasting. On the day of the scan, the fasting glucose level was 105 mg/dL, and PET/CT was performed 45 min after intravenous administration of 148 MBq (4 mCi) of  $^{18}\text{F}$ -FDG. Maximum-intensity projections (Fig. 1) revealed diffuse  $^{18}\text{F}$ -FDG uptake throughout the body, reduced uptake in physiologic sites such as liver, and no site of pathologically increased uptake to suggest residual disease. The transaxial slices revealed that the uptake was localized in the subcutaneous white adipose tissue (WAT), and there was a complete metabolic response to treatment, with a Deauville score of 1. Normally, WAT shows minimal  $^{18}\text{F}$ -FDG uptake, but our patient showed increased  $^{18}\text{F}$ -FDG uptake within the WAT. This unusual finding has been reported in the literature in patients receiving high-dose corticosteroid treatments (1–3) and in HIV patients with lipodystrophy on antiretroviral therapy (4–6).

WAT is metabolically inert, serves to provide the body with the energy substrate by undergoing lipolysis, and has negligible glucose uptake, thus showing negligible  $^{18}\text{F}$ -FDG uptake (3,7). However, corticosteroids are known to induce adipocyte hypertrophy (i.e., anabolic lipogenesis) and adipocyte

hyperplasia in WAT, as well as catabolic lipolysis, ultimately leading to a cushingoid habitus (3,4). Steroids induce adipocyte differentiation and increased glycolytic metabolism in the mitochondria, aided by steroid-induced hyperglycemia, secondary hyperinsulinemia, and increased expression of insulin-sensitive glucose transporters on WAT, leading to increased localization of  $^{18}\text{F}$ -FDG within WAT. Steroids are also believed to induce a proinflammatory milieu and increased macrophage recruitment within WAT, further enhancing  $^{18}\text{F}$ -FDG localization within WAT (8). This increased localization can affect the interpretation of PET/CT images. It can alter semiquantitative parameters such as SUV and metabolic tumor volume and can obscure superficial lesions, especially in neoplasms with limited  $^{18}\text{F}$ -FDG avidity. The present case demonstrates these molecular effects of steroids on lipid homeostasis by revealing increased  $^{18}\text{F}$ -FDG



**FIGURE 1.**  $^{18}\text{F}$ -FDG PET/CT images of 12-y-old girl with lymphoma being evaluated for treatment response. (A) Maximum-intensity projection reveals diffuse uptake throughout body, with reduced uptake in physiologic sites such as liver and no site of pathologically increased uptake (B, C, and D) Transaxial thoracic, abdominal, and pelvic slices, respectively, show uptake localized to subcutaneous and visceral WAT. Cause of this unusual finding was determined to be corticosteroid therapy for nephrotic syndrome.

Received Dec. 13, 2022; revision accepted Feb. 7, 2023.  
For correspondence or reprints, contact Girish Kumar Parida (grish135@gmail.com).  
Published online May 16, 2023.  
COPYRIGHT © 2023 by the Society of Nuclear Medicine and Molecular Imaging.

accumulation in WAT secondary to high-dose prednisolone treatment for nephrotic syndrome.

## DISCLOSURE

No potential conflict of interest relevant to this article was reported.

## REFERENCES

1. Bansal H, Ravina M, Nanda S, Lukose TT, Krishna S. Diffuse white adipose tissue  $^{18}\text{F}$ -FDG uptake: an unusual finding on  $^{18}\text{F}$ -FDG PET/CT. *Clin Nucl Med*. 2021;46:e513–e514.
2. Kong MC, Nadel HR.  $^{18}\text{F}$ -FDG PET/CT with diffusely high FDG uptake throughout subcutaneous adipose tissues. *Clin Nucl Med*. 2018;43:762–763.
3. Pattison DA, Hofman MS, Lau E, Ware R, Hicks RJ. Enhanced white adipose tissue metabolism in iatrogenic Cushing's syndrome with FDG PET/CT. *J Clin Endocrinol Metab*. 2014;99:3041–3042.
4. Hwang DY, Lee JW, Lee SM, Kim S. Causes of  $^{18}\text{F}$ -FDG uptake on white adipose tissue. *Hell J Nucl Med*. 2016;19:7–9.
5. Zade A, Rangarajan V, Purandare N, et al. Hypermetabolic subcutaneous fat in patients on highly active anti-retroviral therapy treatment: subtle finding with implications. *Indian J Nucl Med*. 2012;27:183–184.
6. Sathekege M, Maes A, Kgomo M, Stolz A, Ankrah A, Van De Wiele C. Evaluation of glucose uptake by skeletal muscle tissue and subcutaneous fat in HIV-infected patients with and without lipodystrophy using FDG-PET. *Nucl Med Commun*. 2010;31:311–314.
7. Hofman MS, Hicks RJ. White fat, factitious hyperglycemia, and the role of FDG PET to enhance understanding of adipocyte metabolism. *EJNMMI Res*. 2011;1:2.
8. Staack SO, Rosenthal AC, Cook CB, Yang M. Glucocorticoid-induced hypermetabolism in white adipose tissue in Cushing syndrome. *J Nucl Med Technol*. 2020;48:285–286.

## Erratum

In the article “Evaluation of Data-Driven Respiration Gating in Continuous Bed Motion in Lung Lesions,” by Nii et al. (*J Nucl Med Technol*. 2023;51:32–37), affiliation 2 was inadvertently left out for first author Takeshi Nii. The correct affiliations for Dr. Nii should read: Takeshi Nii<sup>1,2</sup>; <sup>1</sup>Division of Radiological Technology, Department of Medical Technology, University Hospital, Kyoto Prefectural University of Medicine, Kyoto, Japan; <sup>2</sup>Department of Radiation Science, Graduate School of Health Sciences, Hirosaki University, Hirosaki, Japan. We regret the error.