

# <sup>18</sup>F-FDG PET/CT in the Evaluation of Bing–Neel Syndrome

Odile Ajuria Illarramendi<sup>1</sup>, Lesley Flynt<sup>2</sup>, and Franklin Wong<sup>2</sup>

<sup>1</sup>Hospital Universitario Ramon y Cajal, Madrid, Spain; and <sup>2</sup>M.D. Anderson Cancer Center, Houston, Texas

Waldenström macroglobulinemia is an indolent B-cell lymphoproliferative disorder. When there is involvement of the central nervous system, Waldenström macroglobulinemia is known as Bing–Neel syndrome. We present a case of Bing–Neel syndrome in a patient who presented with confusion and left orbital pain. <sup>18</sup>F-FDG PET/CT was utilized in making the diagnosis.

**Key Words:** Bing–Neel syndrome; FDG PET/CT; central nervous system

**J Nucl Med Technol 2019; 47:343–344**

DOI: 10.2967/jnmt.118.225565

**T**his case study demonstrates the ability of <sup>18</sup>F-FDG PET/CT to aid in diagnosing Bing–Neel syndrome.

## CASE REPORT

A 76-y-old man with known Waldenström macroglobulinemia, currently in remission, presented with left eye pain and altered mental status and was admitted to the hospital for further evaluation. Because of concern about possible Bing–Neel syndrome or cerebral fungal infection, and because of contraindications to MRI (the patient had a pacemaker), <sup>18</sup>F-FDG PET/CT was performed. The images revealed 2 hypermetabolic paraventricular lesions: one within the left lateral frontal horn, with an SUV<sub>max</sub> of 10.2 (Fig. 1A), and the other along the lateral margin of the right lateral ventricle, with an SUV<sub>max</sub> of 16.1 (Fig. 1C). There was also an <sup>18</sup>F-FDG-avid lesion in the inferior aspect of the left orbit measuring 1.8 × 0.8 cm, with an SUV<sub>max</sub> of 22.8 (Fig. 1B). These findings are consistent with central nervous system involvement of Waldenström macroglobulinemia, or Bing–Neel syndrome (1). Subsequent lumbar puncture revealed atypical lymphocytosis and cytomorphologic findings consistent with involvement of Waldenström macroglobulinemia (2). The patient subsequently received ultralow-dose radiation therapy to the whole brain and left-eye, as well as 4 cycles of rituximab systemic therapy, with follow-up studies demonstrating resolution of the central nervous system lesions (Fig. 2B).

Received Dec. 28, 2018; revision accepted Mar. 4, 2019.

For correspondence or reprints contact: Odile Ajuria Illarramendi, Hospital Universitario Ramon y Cajal, Carretera Colmenar Viejo Km. 9,100, Madrid 28034, Spain.

E-mail: odileajuria@gmail.com

Published online Jun. 10, 2019.

COPYRIGHT © 2019 by the Society of Nuclear Medicine and Molecular Imaging.

## DISCUSSION

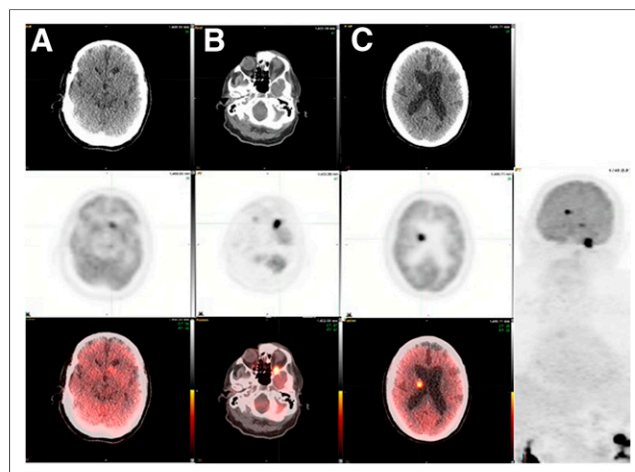
Bing–Neel syndrome is a rare and often late manifestation of central nervous system involvement of Waldenström macroglobulinemia (2). This syndrome can manifest even during remission of Waldenström macroglobulinemia and tends to have a worse prognosis in that case than when appearing as the first manifestation of the disease (2,3).

Two categories of central nervous system involvement have been described—the diffuse form and the tumoral form—and these can be either unifocal or (as in this case) multifocal (3). In order for patients to receive optimal treatment, an appropriate evaluation is necessary to exclude other diseases, such as the hyperviscosity syndrome, which can present with similar neurologic deficits (4). Although gadolinium-enhanced MRI should be performed when Bing–Neel syndrome is suspected (5), in this case it could not be performed because of the prior pacemaker placement.

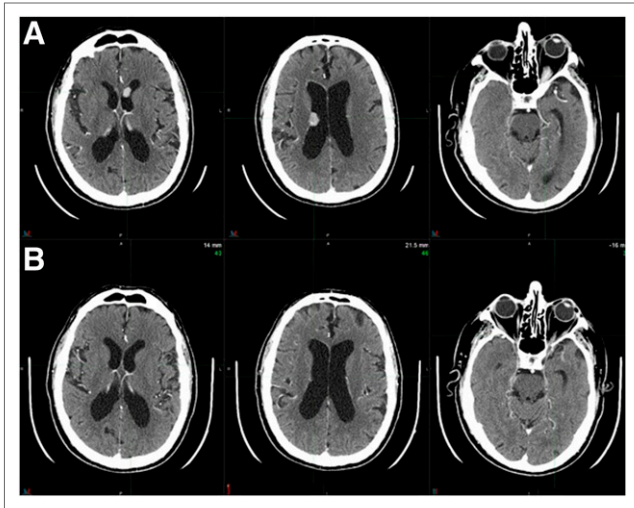
As demonstrated in this case, <sup>18</sup>F-FDG PET/CT can be useful in both identifying and localizing active disease while simultaneously allowing for evaluation of the rest of the body (4).

## CONCLUSION

Bing–Neel syndrome is a rare and often underdiagnosed disease. <sup>18</sup>F-FDG PET/CT can help in the diagnosis and



**FIGURE 1.** Axial CT (top), <sup>18</sup>F-FDG PET (middle), and <sup>18</sup>F-FDG PET/CT (bottom) images of paraventricular left lateral frontal horn lesion (A), left orbit lesion (B), and right lateral paraventricular lesion (C).



**FIGURE 2.** Contrast-enhanced axial CT images before (A) and after (B) treatment. Complete response is seen after treatment.

precise localization of Bing–Neel syndrome. Its use should therefore be considered as an addition to MRI or as an alternative when MRI cannot be performed.

#### DISCLOSURE

No potential conflict of interest relevant to this article was reported.

#### REFERENCES

1. Stacy RC, Jakobic FA, Hochberg FH, Hochberg EP, Cestari DM. Orbital involvement in Bing-Neel syndrome. *J Neuroophthalmol.* 2010;30:255–259.
2. Simon L, Fitsiori A, Lemal R, et al. Bing-Neel syndrome, a rare complication of Waldenstrom's macroglobulinemia: analysis of 44 cases and review of the literature—a study on behalf of the French Innovative Leukemia Organization (FILO). *Haematologica.* 2015;100:1587–1594.
3. Minnema MC, Kimby E, D'Sa S, et al. Guideline for the diagnosis, treatment and response criteria for Bing-Neel syndrome. *Haematologica.* 2017;102:43–51.
4. Castillo JJ, Treon SP. Initial evaluation of the patient with Waldenström Macroglobulinemia. *Hematol Oncol Clin North Am.* 2018;32:811–820.
5. Ly KI, Fintelman F, Forghani R, Schaefer PW, Hochberg EP, Hochberg FH. Novel diagnostic approaches in Bing–Neel syndrome. *Clin Lymphoma Myeloma Leuk.* 2011;11:180–183.