
¹⁸F-FDG PET/CT Can Predict Development of Thyroiditis Due to Immunotherapy for Lung Cancer

Naghmehossadat Eshghi¹, Linda L. Garland², Emily Nia³, Robert Betancourt⁴, Elizabeth Krupinski⁵, and Phillip H. Kuo⁶

¹Department of Medical Imaging, Banner University Medical Center, Tucson, Arizona; ²Department of Medicine, Section of Hematology and Medical Oncology, Banner University Medical Center, Tucson, Arizona; ³Breast Imaging Section, Department of Radiology, University of Texas M.D. Anderson Cancer Center, Houston, Texas; ⁴Department of Medicine, Banner University Medical Center, Tucson, Arizona; ⁵Department of Radiology and Imaging Sciences, Emory University School of Medicine, Atlanta, Georgia; and ⁶Departments of Medical Imaging and Medicine, Banner University Medical Center, and Department of Biomedical Engineering, University of Arizona, Tucson, Arizona

Our primary purpose was to determine whether increased ¹⁸F-FDG uptake in the thyroid gland predicts development of thyroiditis with subsequent hypothyroidism in patients undergoing immunotherapy with nivolumab for lung cancer. Secondly, we determined whether ¹⁸F-FDG uptake in the thyroid gland correlates with number of administered cycles of nivolumab.

Methods: Retrospective chart review over 2 y found 18 lung cancer patients treated with nivolumab who underwent ¹⁸F-FDG PET/CT before and during therapy. SUV_{mean}, SUV_{max}, and total lesion glycolysis of the thyroid gland were measured. SUVs were also measured for the pituitary gland, liver, and spleen. Patients underwent monthly thyroid testing. PET/CT parameters were analyzed by unpaired *t* testing for differences between 2 groups (patients who developed hypothyroidism and those who did not). Correlation between development of thyroiditis and number of cycles of nivolumab was also tested.

Results: Six of 18 patients developed hypothyroidism. The *t* test comparing the 2 groups demonstrated significant differences in SUV_{mean} (*P* = 0.04), SUV_{max} (*P* = 0.04), and total lesion glycolysis (*P* = 0.02) of the thyroid gland. Two of 4 patients who developed thyroiditis and had increased ¹⁸F-FDG uptake in the thyroid gland had a normal TSH level at the time of follow-up ¹⁸F-FDG PET/CT. Patients who developed thyroiditis with subsequent hypothyroidism stayed longer on therapy (10.6 cycles) than patients without thyroiditis (7.6 cycles), but the trend was not statistically significant. No significant difference in PET/CT parameters was observed for pituitary gland, liver, or spleen.

Conclusion: ¹⁸F-FDG PET/CT can predict the development of thyroiditis with subsequent hypothyroidism before laboratory testing. Further study is required to confirm the positive trend between thyroiditis and duration of therapy.

Key Words: molecular imaging; oncology; lung; PET/CT; ¹⁸F-FDG-PET/CT; immunotherapy; lung cancer; thyroiditis

J Nucl Med Technol 2018; 46:260–264

DOI: 10.2967/jnmt.117.204933

Received Nov. 13, 2017; revision accepted Jan. 4, 2018.

For correspondence or reprints contact: Naghmehossadat Eshghi, Department of Medical Imaging, Banner University Medical Center, 1501 N. Campbell Ave., P.O. Box 245067, Tucson, AZ 85724.

E-mail: neshghi@radiology.arizona.edu

Published online Mar. 29, 2018.

COPYRIGHT © 2018 by the Society of Nuclear Medicine and Molecular Imaging.

Immunotherapy agents that target programmed cell death protein-1 (PD-1) or -2 (PD-2) and interrupt tumor-induced immune tolerance have improved outcomes for patients with a variety of malignancies (1–4). PD-1 is expressed on the surface of T cells and binds to PD-1 and PD-2 ligands. This intercellular protein interaction modulates T-cell activation, proliferation, and cytokine production (5,6). The activated T cells kill tumor cells either directly or indirectly by producing cytokines.

Nivolumab is an IgG4 PD-1 immune checkpoint inhibitor antibody that interrupts cancer-induced immune tolerance by disrupting the interaction of PD-1 with PD-1 ligand and PD-2 ligand (7). Nivolumab initially demonstrated longer progression-free survival as a first-line treatment in patients with metastatic or unresectable melanoma (8,9). Further studies demonstrated the efficacy of nivolumab as a second-line therapy for non-small cell lung cancer (1,2,10). The same mechanism as used to reduce immune tolerance to tumors can trigger immunity-related adverse events (irAEs) in the form of various autoimmune syndromes (11). One of the most common endocrine side effects is thyroid dysfunction. Studies on different cancers reported that 8%–22% of patients treated with nivolumab developed thyroiditis and hypothyroidism (11–13). Given this frequency, detecting and treating thyroid dysfunction is critical in patients undergoing therapy with nivolumab and other checkpoint inhibitors. Hepatitis and hypophysitis are less common adverse events related to immunotherapy (14–16).

¹⁸F-FDG PET/CT plays a paramount role in oncologic staging and monitoring of response to therapy. ¹⁸F-FDG is a radioactive glucose analog that is injected intravenously and taken up into cells through glucose transporters. The PET scanner maps the distribution of ¹⁸F-FDG in the body, and the simultaneous CT provides anatomic correlation (17,18).

Numerous ¹⁸F-FDG PET/CT parameters such as the SUV are used as imaging biomarkers to quantify the uptake of ¹⁸F-FDG in malignant tissues and in inflammatory disorders (19–22). Hypothetically, activation of the immune system can result in increased ¹⁸F-FDG activity in the spleen, and

hypophysitis and hepatitis can show increased ^{18}F -FDG uptake from inflammation in the pituitary gland and liver, respectively. Therefore, increased ^{18}F -FDG uptake in these organs may potentially serve as markers for activation of the immune system by nivolumab. In this study, we evaluated this hypothesis by comparing the SUV parameters of these organs before and during therapy.

Inflammation of the thyroid gland associated with autoimmune thyroiditis can result in increased uptake of ^{18}F -FDG in the thyroid gland (23,24). We hypothesized that measuring ^{18}F -FDG uptake as a marker for inflammation in the thyroid gland may allow imaging to predict thyroid dysfunction before the results of thyroid function tests become abnormal. Additionally, we evaluated the correlation between development of thyroiditis and greater duration of therapy with nivolumab.

MATERIALS AND METHODS

Patient Selection

This retrospective study was approved by the institutional Human Subjects Protection Program. After approval by the U.S. Food and Drug Administration in October 2015 for use in advanced non-small cell lung cancer, nivolumab was implemented into the standard of care at our institution. In total, 382 patients with lung cancer were treated between October 2015 and February 2017. Of those 382, 25 with advanced non-small cell lung cancer failed to respond to conventional treatment and received immunotherapy with nivolumab. Each cycle of therapy lasted 4 wk and included 2 intravenous infusions of nivolumab at a standard dose of 240 mg over 60 min every 2 wk. Serum thyroid-stimulating hormone (TSH) was measured as the standard of care approximately every month. Hypothyroidism was defined as a TSH level higher than the upper limit of normal (normal institutional TSH range, 0.35–4.0 mIU/L). Of these 25 patients, 18 met the additional inclusion criteria of having received at least 2 cycles of therapy and ^{18}F -FDG PET/CT scans both before and during therapy. All 18 patients were followed until discontinuation of nivolumab because of progression of disease or intolerable irAEs.

PET/CT Scanning

A minimum of 4 h of fasting before the intravenous administration of ^{18}F -FDG was standard for all patients. Fingertick blood glucose levels of the patients were measured before intravenous injection of ^{18}F -FDG at a weight-based dose of 3.7 MBq (0.1 mCi)/kg with a range of 185 MBq (5 mCi) to 370 MBq (10 mCi). After injection of ^{18}F -FDG, the patients sat quietly awake for approximately 60 min. ^{18}F -FDG PET/CT was performed from vertex to thigh using the GE Healthcare 690 time-of-flight scanner. A matching low-dose CT scan was obtained without intravenous contrast material and with oral contrast material before the PET acquisition. If possible, all patients were scanned with arms up. The acquisition time was 2.5 min per bed position, and 7–8 bed positions were obtained, depending on the height of the patient. The PET data were reconstructed using ordered-subsets expectation maximization (28 subsets, 2 iterations).

Analysis of PET/CT Scans

The ^{18}F -FDG PET/CT scans obtained before and 10–16 wk after initiation of nivolumab were analyzed. Ten to 16 wk correlates to approximately 2–4 cycles of nivolumab therapy. The ^{18}F -FDG PET/CT scans of these patients were analyzed for ^{18}F -FDG

uptake in the thyroid gland, pituitary gland, liver, and spleen. SUV_{max} , SUV_{mean} , and total lesion glycolysis (TLG) were measured using ^{18}F -FDG PET/CT software from Mirada XD, version 3.6.5.28 (Oxford). For measuring the TLG for the thyroid gland, a 3-dimensional region of interest (ROI) was drawn around the larger lobe, since some patients had asymmetric glands with one lobe too small to accurately and reproducibly quantify. Activity in the thyroid gland greater than in the blood pool was deemed as increased visually. For the pituitary gland, an ROI was drawn to encompass the entire gland. For the liver and spleen, a 3-cm spheric ROI was drawn in the center of the organ. Thresholding of the ROIs was performed as necessary for optimal contouring. The resultant SUV_{max} , SUV_{mean} , and TLG were recorded in a Microsoft Excel spreadsheet.

Statistical Analysis

Patients were divided into 2 groups: patients who developed irAE thyroiditis (hypothyroidism) and those who did not. For the thyroid, liver, spleen, and pituitary gland, PET/CT parameters before and during therapy were analyzed with an unpaired *t* test to assess for significant differences between the 2 groups. Correlation analysis with *z* tests for significance was used to assess the relationships among PET/CT parameters, development of irAE thyroiditis, and number of cycles of nivolumab.

RESULTS

Eighteen patients with advanced non-small cell lung cancer were treated with nivolumab between October 2015 and February 2017 and met the inclusion criteria for this study. The mean age of the patients was 69 y (range, 31–86 y). Eleven patients (61%) were female. Fourteen (78%) presented with adenocarcinoma of the lung, and 4 (22%) presented with squamous cell lung carcinoma. The average blood glucose level before injection of ^{18}F -FDG was 99 mg/dL, with a range of 64–180 mg/dL. The average uptake time of ^{18}F -FDG was 60 min, with a range of 50–80 min.

Chart review of the monthly thyroid testing divided the patients into 2 groups: patients who developed immune-related thyroiditis with subsequent hypothyroidism ($n = 6$) and those who did not ($n = 12$). Sixteen of the 18 patients had a normal TSH level before initiation of the immunotherapy. Two patients had a history of hypothyroidism before starting nivolumab and were already on thyroid hormone replacement; however, adding or removing these 2 patients did not affect overall statistical significance. Five of the 6 patients who developed hypothyroidism were female. The average onset of hypothyroidism was after 3 cycles (range, 3–6 cycles) of nivolumab. The timing of serum TSH measurements was within 2 wk before or after the ^{18}F -FDG PET/CT examination. Four of 6 patients who developed hypothyroidism during the course of therapy had a normal TSH level at the time of follow-up ^{18}F -FDG PET/CT. In the 6 patients who developed irAE thyroiditis with subsequent hypothyroidism, the average serum TSH at the time of follow-up ^{18}F -FDG PET/CT was just slightly higher (4.31 mIU/L; range, 0.3–12.15 mIU/L) than the upper limit of normal (0.35–4.0 mIU/L). Two of 4 patients with irAE thyroiditis with subsequent hypothyroidism and increased

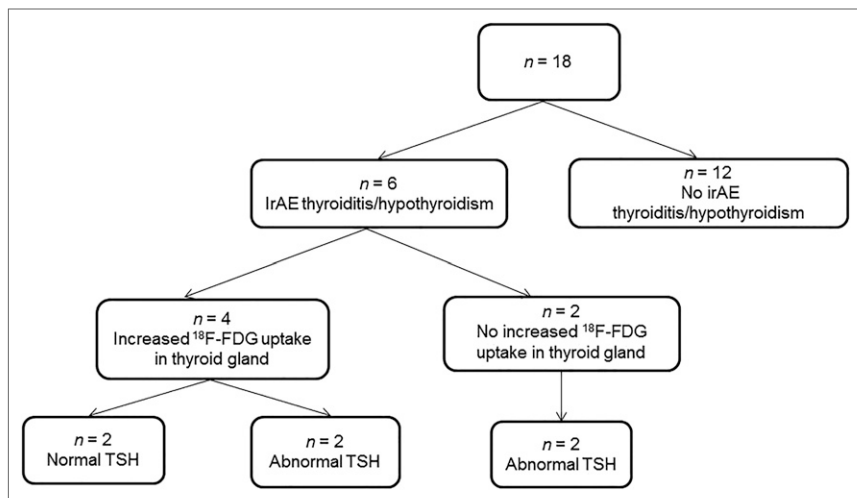


FIGURE 1. Flow chart showing distribution of patients by development of thyroiditis, ^{18}F -FDG uptake in thyroid gland, and value of TSH at time of PET/CT.

^{18}F -FDG uptake in the thyroid gland had a normal TSH level at the time of follow-up ^{18}F -FDG PET/CT. In the 2 patients with an elevated serum TSH level at the time of follow-up ^{18}F -FDG PET/CT and increased ^{18}F -FDG uptake in the thyroid gland, the serum TSH average was 9.2 mIU/L, with range of 6.18–12.15 mIU/L (Fig. 1).

The average number of cycles of nivolumab received was 8.6 (range, 3–20), with each cycle lasting 4 wk. The patients who developed hypothyroidism stayed longer on therapy (10.6 cycles) than the patients who had no immunity-related thyroid dysfunction (7.6 cycles) during the nivolumab treatment, but the trend was not statistically significant. Table 1 provides the characteristics of the study population.

Diffusely increased ^{18}F -FDG uptake in the thyroid gland during nivolumab therapy was seen visually in 4 of 6 patients who developed thyroiditis with subsequent hypothyroidism (Fig. 2). Two of 6 patients who developed immune-related hypothyroidism by laboratory analysis demonstrated no increased ^{18}F -FDG uptake in the thyroid gland during nivolumab therapy (Fig. 3). Table 2 provides SUV_{mean} , SUV_{max} , and TLG for patients who developed hypothyroidism during the nivolumab therapy.

TABLE 1
Overview of Patient Characteristics

Characteristic	Total (n = 18)	Thyroid irAE (n = 6)	No thyroid irAE (n = 12)
Age (y)			
Mean	69	65	72
Range	31–86	31–79	51–86
Sex (n)			
Female	11 (61%)	5 (83%)	6 (50%)
Male	7 (39%)	1 (17%)	6 (50%)
Therapy cycles (n)			
Mean	8.6	10.6	7.6
Range	3–20	6–20	3–15

therapy showed no significant differences in SUV_{mean} (-0.07 , $P = 0.57$) or SUV_{max} (-0.33 , $P = 0.26$). Similarly, the spleen displayed no significant differences in SUV_{mean} (-0.33 , $P = 0.86$) or SUV_{max} (-0.43 , $P = 0.41$). Review of the medical records revealed no evidence of autoimmune disorders of these organs.

DISCUSSION

To our knowledge, this was the first study evaluating ^{18}F -FDG PET/CT parameters of the thyroid gland, pituitary gland, liver, and spleen in patients with advanced non-small cell lung cancer before and during therapy with nivolumab. The percentage of patients who developed thyroiditis with subsequent hypothyroidism during the immunotherapy (33%, 6/18) was high compared with prior studies (11,25). The onset of hypothyroidism during therapy occurred between the third and sixth cycles of therapy, as was in line with prior published studies (25,26). Like the study from Filette et al. (26), most patients who developed hypothyroidism during the immunotherapy were female. Presumably, this finding is

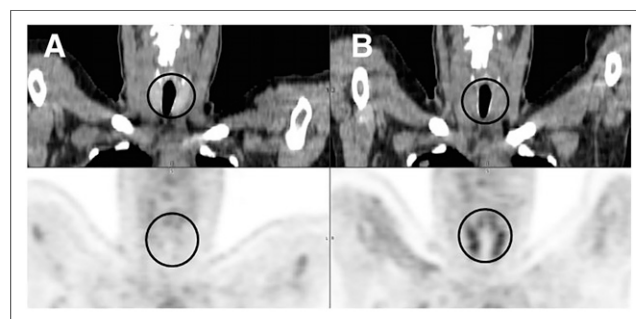


FIGURE 2. Patient with increased ^{18}F -FDG uptake in thyroid gland during nivolumab therapy. (A) Coronal CT (top) and ^{18}F -FDG PET (left) images before therapy show normal uptake in thyroid gland, with SUV_{max} of 1.7. (B) Coronal CT (top) and ^{18}F -FDG PET (bottom) images during therapy show increased thyroid uptake, with SUV_{max} of 4.3. Region of thyroid gland is encircled.

Between patients who developed irAE thyroiditis with subsequent hypothyroidism and those who did not, the pretherapy ^{18}F -FDG PET/CT scans showed no statistical difference in SUV_{mean} (0.28 , $P = 0.23$), SUV_{max} (0.28 , $P = 0.28$), or TLG (0.43 , $P = 0.13$). PET/CT during therapy showed statistically significant differences between the 2 groups for SUV_{mean} (0.77 , $P = 0.04$), SUV_{max} (0.96 , $P = 0.04$), and TLG (0.96 , $P = 0.02$). Table 3 displays the ^{18}F -FDG uptake parameters and statistical analysis.

Measurements of the pituitary gland before and during therapy demonstrated no significant differences in SUV_{mean} (-0.10 , $P = 0.63$) or SUV_{max} (-0.19 , $P = 0.33$). The liver before and during

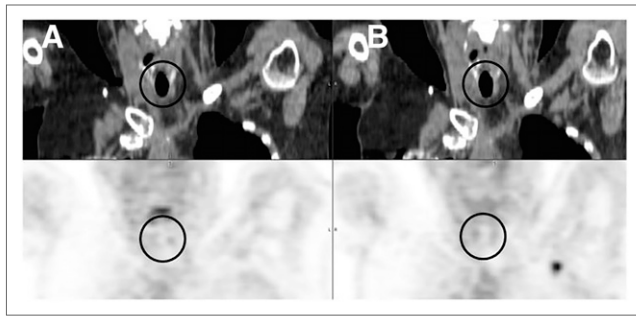


FIGURE 3. Patient with normal ^{18}F -FDG uptake in thyroid gland during nivolumab therapy. (A) Coronal CT (top) and ^{18}F -FDG PET (left) images before therapy show normal uptake in thyroid gland, with SUV_{max} of 2.2. (B) Coronal CT (top) and ^{18}F -FDG PET (bottom) images during therapy show stable, normal thyroid uptake, with SUV_{max} of 1.8. Region of thyroid gland is encircled.

related to the higher prevalence of autoimmune thyroid disease in women (27).

^{18}F -FDG PET/CT is a critical imaging modality for staging and assessing response to therapy for lung cancer (28,29). Studies and case reports have demonstrated the use of ^{18}F -FDG PET/CT in monitoring of response after immunotherapy (30–33). The ability of ^{18}F -FDG PET/CT to detect the irAE thyroiditis in melanoma patients treated with pembrolizumab was reported in a study from Filette et al. In our study, visually increased FDG uptake in the thyroid gland on the PET/CT images during therapy was observed in 4 of 6 patients who developed hypothyroidism. The SUV_{max} of the thyroid gland in these 4 patients ranged from 2.4 to 4.5. Comparing the patients who developed irAE thyroiditis and those who did not, statistically significant differences in SUV_{mean} , SUV_{max} , and TLG were demonstrated in the thyroid gland on PET/CT during therapy. Correlation with serum TSH level checked monthly demonstrated a normal TSH level at the time of follow-up ^{18}F -FDG PET/CT in 2 of 4 patients who had increased ^{18}F -FDG uptake in the thyroid gland and developed thyroiditis with subsequent hypothyroidism later while on therapy. Diffusely increased ^{18}F -FDG uptake is consistent with inflammation of the thyroid gland associated with autoimmune thyroiditis (23,24). This study demonstrated the ability of ^{18}F -FDG PET/CT to detect irAE thyroiditis before elevation of serum TSH. Therefore, detecting an increase in

activity in the thyroid gland on ^{18}F -FDG PET/CT can alert the oncologist and patient to be more vigilant for signs or symptoms of hypothyroidism.

Hepatitis and hypophysitis are also adverse events related to immunotherapy (14–16). Hypothetically, activation of the immune system could result in increased ^{18}F -FDG activity in the spleen. Comparing the patients who developed irAE thyroiditis and those who did not, ^{18}F -FDG uptake in liver and spleen demonstrated no significant change. Likewise, no significant changes in ^{18}F -FDG uptake in the pituitary gland were seen, also decreasing the likelihood of secondary hypothyroidism due to hypophysitis from immunotherapy.

One of the strengths of this study was the long duration of follow-up. A potentially vital finding of this study was the trend that patients who developed irAE thyroiditis received more cycles of nivolumab therapy than patients without irAE thyroiditis. At our institution, patients are continued on nivolumab as long as disease is stable or improved and side effects are tolerable. The number of cycles of nivolumab that a patient received may be considered a surrogate for progression-free survival.

The development of irAEs, including thyroid dysfunction, may be a marker of concomitant activation of the immune system against tumor. A similar correlation of good response with the occurrence of irAEs was observed in patients with metastatic melanoma treated with immunotherapy (34). A limitation of our study was the relatively small sample size. Although our study was statistically significant for the ability of ^{18}F -FDG PET/CT to predict development of irAE thyroiditis, a larger number of patients would have been required to establish statistical significance for predicting response to nivolumab, and such a study is ongoing. If subsequently proven, ^{18}F -FDG PET/CT could potentially detect the irAE thyroiditis before blood testing and therefore act as an early predictor for good response to immunotherapy.

This study had limitations with regard to the assessment of thyroid status. A euthyroid state does not exclude the diagnosis of thyroiditis, because hypothyroidism is a relatively late consequence of thyroiditis. Because biopsy of the thyroid gland to evaluate for inflammation is impractical, determining euthyroid or hypothyroid state by TSH is the most clinically relevant method for grouping patients. When the patients stopped immunotherapy, the oncologist also stopped checking

TABLE 2
 ^{18}F -FDG Uptake in Thyroid Gland in Patients Who Developed Thyroiditis

Patient no.	Before therapy			During therapy			Difference		
	SUV_{mean}	SUV_{max}	TLG	SUV_{mean}	SUV_{max}	TLG	SUV_{mean}	SUV_{max}	TLG
1	1.5	1.5	0.7	3.3	4.1	3.5	1.8	2.6	2.8
2	1.7	2.1	1.5	3.7	4.5	2.9	2	2.4	1.4
3	1.3	1.7	0.9	3.5	4.3	2.3	2.2	2.6	1.4
4	0.9	1.1	0.7	1.9	2.4	1.6	1	1.3	0.9
5	2.4	2.8	1.9	1.6	1.8	1.6	-0.8	-1	-0.3
6	2	2.2	0.2	1.6	1.8	0.3	-0.4	-0.4	0.1

TABLE 3

Comparison of Thyroid ¹⁸F-FDG Uptake During Therapy Between Groups That Did and Did Not Develop Thyroiditis

Parameter	Thyroid irAE (n = 6)	No thyroid irAE (n = 12)	Difference
SUV _{mean}	2.41 (1.04)	1.64 (0.44)	0.77 (P = 0.04)
SUV _{max}	2.96 (1.28)	2.00 (0.5)	0.96 (P = 0.04)
TLG	1.96 (1.05)	1.00 (0.47)	0.96 (P = 0.02)

Data are mean followed by SD in parentheses.

TSH levels. Therefore, the analysis would miss the unlikely scenario of a patient developing subclinical hypothyroidism after discontinuing immunotherapy.

CONCLUSION

Because lung cancer patients treated with immunotherapy are staged and followed with ¹⁸F-FDG PET/CT, standard-of-care use of this imaging could predict the development of the irAE thyroiditis before laboratory testing. Thus, oncologists and patients can be more vigilant for signs or symptoms of early hypothyroidism and initiate thyroid hormone replacement optimally. Further work is required to establish more strongly the predictive power of finding increased ¹⁸F-FDG activity in the thyroid and progression-free survival.

DISCLOSURE

Phillip H. Kuo is a consultant or speaker for Endocyte, GE Healthcare, Imaging Endpoints, inviCRO, Lilly, MD Training at Home, Molecular Neuroimaging Institute, and Progenics; an investigator for clinical trials with Astellas, Endocyte, GE Healthcare, and Merck; and a recipient of educational and investigator-initiated grants from GE Healthcare. No other potential conflict of interest relevant to this article was reported.

ACKNOWLEDGMENT

We thank Carol Stuehm, our research specialist, for helping us with figures and data coding.

REFERENCES

- Borghaei H, Paz-Ares L, Horn L, et al. Nivolumab versus docetaxel in advanced nonsquamous non-small-cell lung cancer. *N Engl J Med.* 2015;373:1627–1639.
- Brahmer J, Reckamp K, Baas P, et al. Nivolumab versus docetaxel in advanced squamous-cell non-small-cell lung cancer. *N Engl J Med.* 2015;373:123–135.
- Motzer RJ, Escudier B, McDermott DF, et al. Nivolumab versus everolimus in advanced renal-cell carcinoma. *N Engl J Med.* 2015;373:1803–1813.
- Kasamon YL, de Claro RA, Wang Y, Shen YL, Farrell AT, Pazdur R. FDA approval summary: nivolumab for the treatment of relapsed or progressive classical Hodgkin lymphoma. *Oncologist.* 2017;22:585–591.
- Bennett F, Luxenberg D, Ling V, et al. Program death-1 engagement upon TCR activation has distinct effects on costimulation and cytokine-driven proliferation: attenuation of ICOS, IL-4, and IL-21, but not CD28, IL-7, and IL-15 responses. *J Immunol.* 2003;170:711–718.
- Parry RV, Chemnitz JM, Frauwirth KA, et al. CTLA-4 and PD-1 receptors inhibit T-cell activation by distinct mechanisms. *Mol Cell Biol.* 2005;25:9543–9553.

- Sharma P, Wagner K, Wolchok JD, Allison JP. Novel cancer immunotherapy agents with survival benefit: recent successes and next steps. *Nat Rev Cancer.* 2011;11:805–812.
- Topalian SL, Sznol M, McDermott DF, et al. Survival, durable tumor remission, and long-term safety in patients with advanced melanoma receiving nivolumab. *J Clin Oncol.* 2014;32:1020–1030.
- Larkin J, Chiarion-Sileni V, Gonzalez R, et al. Combined nivolumab and ipilimumab or monotherapy in untreated melanoma. *N Engl J Med.* 2015;373:23–34.
- de Mello RA, Veloso AF, Esrom CP, Nadine S, Antoniou G. Potential role of immunotherapy in advanced non-small-cell lung cancer. *Onco Targets Ther.* 2016;10:21–30.
- Torino F, Corsello SM, Salvatori R. Endocrinological side-effects of immune checkpoint inhibitors. *Curr Opin Oncol.* 2016;28:278–287.
- Tanaka R, Fujisawa Y, Maruyama H, et al. Nivolumab-induced thyroid dysfunction. *Jpn J Clin Oncol.* 2016;46:575–579.
- Orlov S, Salari F, Kashat L, Walfish PG. Induction of painless thyroiditis in patients receiving programmed death 1 receptor immunotherapy for metastatic malignancies. *J Clin Endocrinol Metab.* 2015;100:1738–1741.
- van der Hiel B, Blank CU, Haanen JB, Stokkel MP. Detection of early onset of hypophysitis by ¹⁸F-FDG PET-CT in a patient with advanced stage melanoma treated with ipilimumab. *Clin Nucl Med.* 2013;38:e182–e184.
- Brilli L, Danielli R, Ciuoli C, et al. Prevalence of hypophysitis in a cohort of patients with metastatic melanoma and prostate cancer treated with ipilimumab. *Endocrine.* 2017;58:535–541.
- Koelzer VH, Glatz K, Bubendorf L, et al. The pathology of adverse events with immune checkpoint inhibitors. *Pathologie.* 2017;38:197–208.
- Cohade C, Wahl RL. Applications of positron emission tomography/computed tomography image fusion in clinical positron emission tomography-clinical use, interpretation methods, diagnostic improvements. *Semin Nucl Med.* 2003;33:228–237.
- Townsend DW, Beyer T, Blodgett TM. PET/CT scanners: a hardware approach to image fusion. *Semin Nucl Med.* 2003;33:193–204.
- Basu S, Zhuang H, Torigian DA, Rosenbaum J, Chen W, Alavi A. Functional imaging of inflammatory diseases using nuclear medicine techniques. *Semin Nucl Med.* 2009;39:124–145.
- Cheng G, Alavi A, Del Bello CV, Akers SR. Differential washout of FDG activity in two different inflammatory lesions: implications for delayed imaging. *Clin Nucl Med.* 2013;38:576–579.
- Nahmias C, Wahl LM. Reproducibility of standardized uptake value measurements determined by ¹⁸F-FDG PET in malignant tumors. *J Nucl Med.* 2008;49:1804–1808.
- O JH, Jacene H, Luber B. Quantitation of cancer treatment response by FDG PET/CT: multi-center assessment of measurement variability. *J Nucl Med.* 2017; 58:1429–1434.
- Yasuda S, Shohtsu A, Ide M, et al. Chronic thyroiditis: diffuse uptake of FDG at PET. *Radiology.* 1998;207:775–778.
- Agrawal K, Weaver J, Ngu R, Krishnamurthy Mohan H. Clinical significance of patterns of incidental thyroid uptake at ¹⁸F-FDG PET/CT. *Clin Radiol.* 2015;70: 536–543.
- Osorio JC, Ni A, Chaft JE, et al. Antibody-mediated thyroid dysfunction during T-cell checkpoint blockade in patients with non-small-cell lung cancer. *Ann Oncol.* 2017;28:583–589.
- de Filette J, Jansen Y, Schreuer M, et al. Incidence of thyroid-related adverse events in melanoma patients treated with pembrolizumab. *J Clin Endocrinol Metab.* 2016;101:4431–4439.
- Manji N, Carr-Smith JD, Boelaert K, et al. Influences of age, gender, smoking, and family history on autoimmune thyroid disease phenotype. *J Clin Endocrinol Metab.* 2006;91:4873–4880.
- Chen HH, Chiu NT, Su WC, Guo HR, Lee BF. Prognostic value of whole-body total lesion glycolysis at pretreatment FDG PET/CT in non-small cell lung cancer. *Radiology.* 2012;264:559–566.
- Sheikhbahaee S, Mena E, Yanamadala A, et al. The value of FDG PET/CT in treatment response assessment, follow-up, and surveillance of lung cancer. *AJR.* 2017;208:420–433.
- Koo PJ, Klingensmith WC, Lewis KD, Bagrosky BM, Gonzalez R. Anti-CTLA4 antibody therapy related complications on FDG PET/CT. *Clin Nucl Med.* 2014; 39:e93–e96.
- Covington MF, Curiel CN, Lattimore L, Avery RJ, Kuo PH. FDG-PET/CT for monitoring response of melanoma to the novel oncolytic viral therapy talimogene laherparepvec. *Clin Nucl Med.* 2017;42:114–115.
- Wachsmann JW, Ganti R, Peng F. Immune-mediated disease in ipilimumab immunotherapy of melanoma with FDG PET-CT. *Acad Radiol.* 2017;24:111–115.
- Wong AN, McArthur GA, Hofman MS, Hicks RJ. The advantages and challenges of using FDG PET/CT for response assessment in melanoma in the era of targeted agents and immunotherapy. *Eur J Nucl Med Mol Imaging.* 2017;44:67–77.
- Attia P, Phan GQ, Maker AV, et al. Autoimmunity correlates with tumor regression in patients with metastatic melanoma treated with anti-cytotoxic T-lymphocyte antigen-4. *J Clin Oncol.* 2005;23:6043–6053.