
The Evaluation of Cardiac Sarcoidosis with ^{18}F -FDG PET

Zaid Al-Faham, Prashant Jolepalem, and Ching Yee Oliver Wong

Department of Diagnostic Radiology and Molecular Imaging, William Beaumont School of Medicine and Beaumont Health System, Oakland University, Royal Oak, Michigan

Cardiac involvement in sarcoidosis is associated with poor prognosis. ^{18}F -FDG PET can detect the presence of cardiac sarcoidosis, assess disease activity, and serve as a means to monitor treatment response in patients with cardiac sarcoidosis.

Key Words: ^{18}F -FDG PET; myocardial sarcoidosis; cardiac MR imaging

J Nucl Med Technol 2016; 44:92–93

DOI: 10.2967/jnmt.115.158857

Cardiac involvement occurs in 20%–30% of patients who had systemic sarcoidosis as shown in pathology examinations and is associated with poor prognosis (1,2). Although myocardial granulomas can be identified in almost 25%–79% of autopsy examinations, only 25% of all patients with sarcoidosis have clinical manifestations of cardiac involvement (1). In this report, ^{18}F -FDG PET helped in diagnosing a patient with suspected cardiac sarcoidosis, classifying the disease activity, and monitoring the response to treatment.

CASE REPORT

A 68-y-old man with a history of cutaneous sarcoidosis presented to the cardiology clinic with progressive dyspnea. Physical examination revealed +4-pitting edema. Electrocardiography showed complete heart block. The results of cardiac MR imaging suggested an infiltrative process. The patient was instructed to take a high-fat low-carbohydrate diet the day before imaging, without an additional overnight fast. With a baseline blood glucose level of 93 mg/dL, the patient was injected with 3.94 Bq (10.67 mCi) of ^{18}F -FDG, and after a 1-h delay, multiple metabolic tomographic images of the myocardium were obtained. The ^{13}N -ammonia perfusion images (Fig. 1, bottom) demonstrated defects in the mid to basal inferior wall, basal anterior walls, and anteroseptal and inferoseptal areas, as indicated by a correspondingly increased level of ^{18}F -FDG

uptake in these regions. This finding was consistent with active sarcoid infiltration of the myocardium. The calculated ejection fraction was 24%. The patient completed a 6-mo trial of high-dose steroids, after which a follow-up myocardial PET study (Fig. 2) demonstrated moderate improvement of the perfusion defects (whereas the ^{18}F -FDG portion demonstrated only blood-pool activity without myocardial trapping). The ejection fraction improved to 37%. These findings indicated an excellent response to treatment of the existing inflammation, although clinical improvement depends on the extent of previous damage.

DISCUSSION

Cardiac sarcoidosis represents the cause of death in 13%–25% of fatal cases of sarcoidosis (1). A definitive diagnosis of cardiac sarcoidosis can be made by endomyocardial biopsy, with sensitivity being less than 20% (2). For a definitive diagnosis and management, all patients will likely benefit from an echocardiogram and either cardiac MR imaging or ^{18}F -FDG PET (1). Cardiac MR imaging is usually performed as the initial test in patients with suspected cardiac sarcoidosis. Gadolinium-enhanced cardiac MR imaging with delayed imaging has the benefit of high sensitivity and spatial resolution without radiation exposure. If the MR results are negative, ^{18}F -FDG PET can be avoided. If the MR results suggest cardiac involvement, ^{18}F -FDG PET imaging may be performed to establish baseline disease activity, assess the need for initiation of medical therapy, and monitor response to treatment over time. In patients with contraindications to cardiac MR imaging, ^{18}F -FDG PET can be used as the first-line imaging method (1). Usually, cardiac MR imaging shows scarring, and thus chronic disease, whereas ^{18}F -FDG PET identifies active involvement. Typical radionuclide protocols for imaging cardiac sarcoidosis include ^{18}F -FDG PET for imaging inflammation combined with SPECT or PET myocardial perfusion imaging (1).

The myocardial perfusion assessment can be performed with $^{99\text{m}}\text{Tc}$, ^{201}Tl , ^{13}N -ammonia, or ^{82}Rb -based radiotracers using standard protocols. Attenuation correction should be applied to SPECT myocardial perfusion imaging whenever possible. In the absence of coronary artery abnormalities, perfusion defects seen on PET scanning in a patient with sarcoidosis strongly suggest that the heart is involved

Received Apr. 6, 2015; revision accepted Jul. 1, 2015.

For correspondence or reprints contact: Zaid Al-Faham, Beaumont Health System, OUWB School of Medicine, Nuclear Medicine Division, 3601 W. 13 Mile Rd., Royal Oak, MI 48703.

E-mail: zaidfaham@gmail.com.

Published online Aug. 13, 2015.

COPYRIGHT © 2016 by the Society of Nuclear Medicine and Molecular Imaging, Inc.

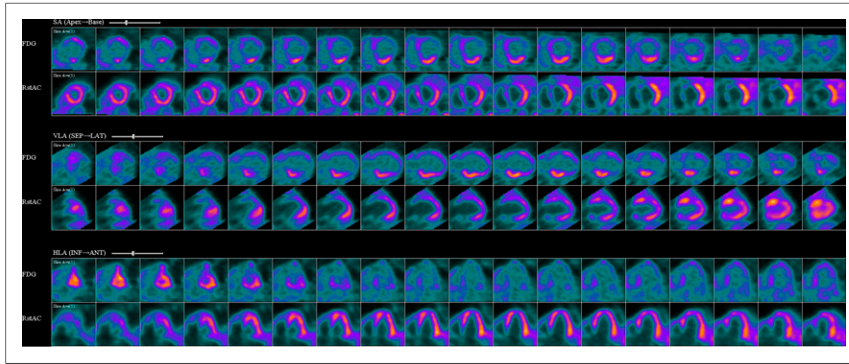


FIGURE 1. Perfusion images demonstrating defects in mid to basal inferior wall, basal anterior walls, and anteroseptal and inferoseptal areas, as indicated by correspondingly increased ^{18}F -FDG uptake in these regions.

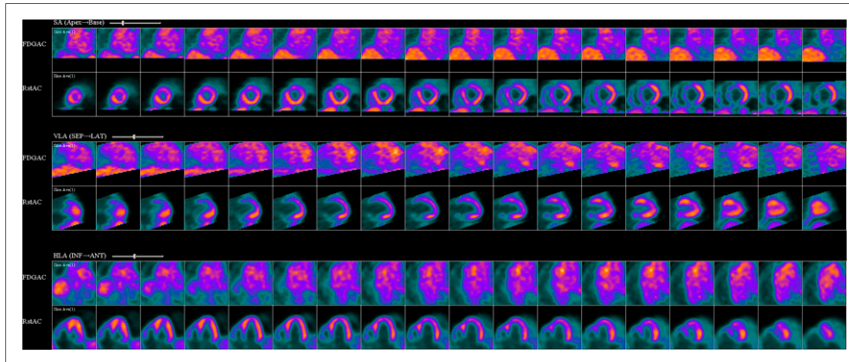


FIGURE 2. Improvement of perfusion defects as indicated by only blood-pool activity being seen on ^{18}F -FDG images.

(2). One way to describe the pattern in cardiac sarcoidosis on PET scans is to compare the degree of perfusion abnormality with the intensity of ^{18}F -FDG uptake: normal (normal perfusion/normal ^{18}F -FDG), early stage (mild perfusion defect/increased ^{18}F -FDG), progressive stage (moderate perfusion defect/increased ^{18}F -FDG), progressive myocardial impairment stage (severe perfusion defect/increased ^{18}F -FDG), and fibrosis stage (severe perfusion defect/minimal or no ^{18}F -FDG uptake) (1). We used this method, and the results were descriptive of the progressive myocardial impairment stage (Fig. 1). Our patient showed clinical improvement after 6 mo of treatment, and the PET findings resolved. ^{18}F -FDG uptake was consistent with subsided inflammation, although clinical improvement (Fig. 2) is ultimately limited by the previous damage.

CONCLUSION

^{18}F -FDG PET can detect the presence of cardiac sarcoidosis, assess disease activity, and monitor treatment response in patients.

DISCLOSURE

No potential conflict of interest relevant to this article was reported.

REFERENCES

1. Skali H, Schulman AR, Dorbala S. ^{18}F -FDG PET/CT for the assessment of myocardial sarcoidosis. *Curr Cardiol Rep.* 2013;15:352.
2. Sekhri V, Sanal S, Delorenzo LJ, Aronow WS, Maguire GP. Cardiac sarcoidosis: a comprehensive review. *Arch Med Sci.* 2011;7:546–554.