

# Prostate Cancer Metastases to Inguinal Lymph Nodes Detected by Attenuation-Corrected $^{11}\text{C}$ -Acetate PET/CT

Veer A. Shah<sup>1</sup>, Allison Rixey<sup>2</sup>, and Reginald Dusing<sup>1</sup>

<sup>1</sup>Department of Radiology, University of Kansas Medical Center, Kansas City, Kansas; and <sup>2</sup>University of Kansas School of Medicine, Kansas City, Kansas

The inguinal lymph nodes are an unusual site of metastases for prostate adenocarcinoma. We present a case in which a 61-year-old man with biochemically recurrent prostate cancer underwent attenuation-corrected  $^{11}\text{C}$ -acetate PET/CT, which demonstrated multiple foci of increased activity in the left inguinal, left iliac chain, and right inguinal regions. The attenuation-corrected CT portion of the scan also showed anterior wall thickening of the rectum. The imaging findings were suggestive of metastatic involvement of the rectum below the dentate line with subsequent spread to the inguinal lymph nodes.

**Key Words:** prostate cancer;  $^{11}\text{C}$ -acetate PET/CT; AC; inguinal; lymph nodes

**J Nucl Med Technol 2016; 44:46–48**

DOI: 10.2967/jnmt.115.157594

**L**ymphatic spread of prostatic cancer rarely involves the inguinal region. In a patient presenting with inguinal lymphadenopathy, careful consideration of the routes of lymphatic drainage may allow sites of metastasis to be identified. A variety of imaging modalities have been used with variable success to identify and localize sites of recurrence.

## CASE REPORT

The institutional review board approved this study, and the requirement to obtain informed consent was waived. A 61-year-old man with a history of prostate cancer (Gleason score 7) was found to have a prostate-specific antigen level of 8.0 ng/mL 20 mo after brachytherapy treatment. A radionuclide bone scan had normal findings. A subsequent CT scan of the abdomen and pelvis revealed multiple enlarged left inguinal lymph nodes, with the two largest measuring 2.3 and 2 cm and several other mildly enlarged nodes measuring less than 1 cm. On the basis of these results, the patient was then referred for an attenuation-corrected  $^{11}\text{C}$ -acetate scan PET/CT scan.

Received Mar. 19, 2015; revision accepted May 26, 2015.

For correspondence or reprints contact: Veer A. Shah, Radiology Research, Department of Radiology, Mail Stop 4032, 3901 Rainbow Blvd., Kansas City, KS.

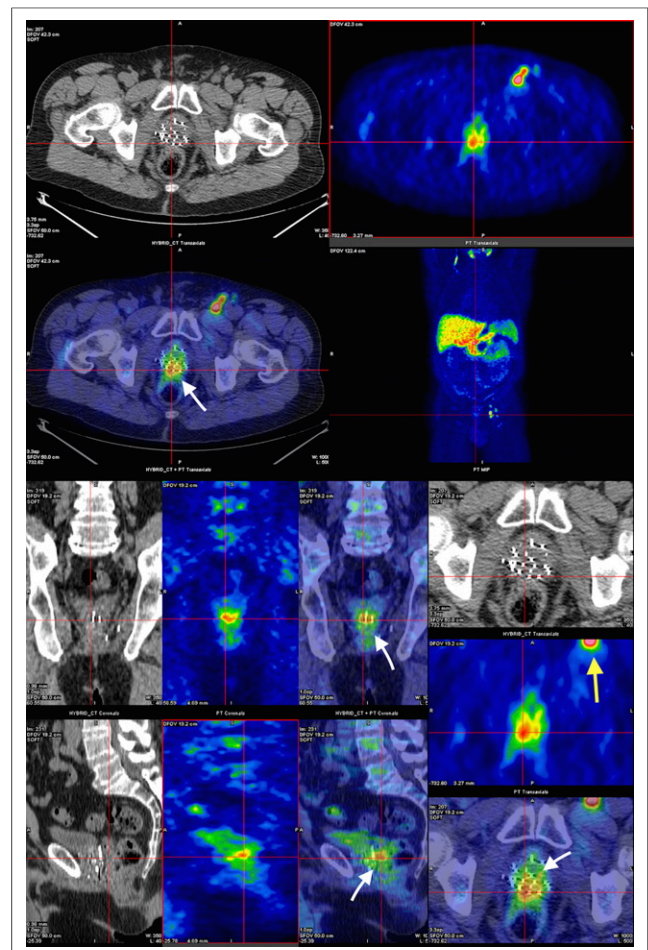
E-mail: vshah@kumc.edu

Published online Jun. 25, 2015.

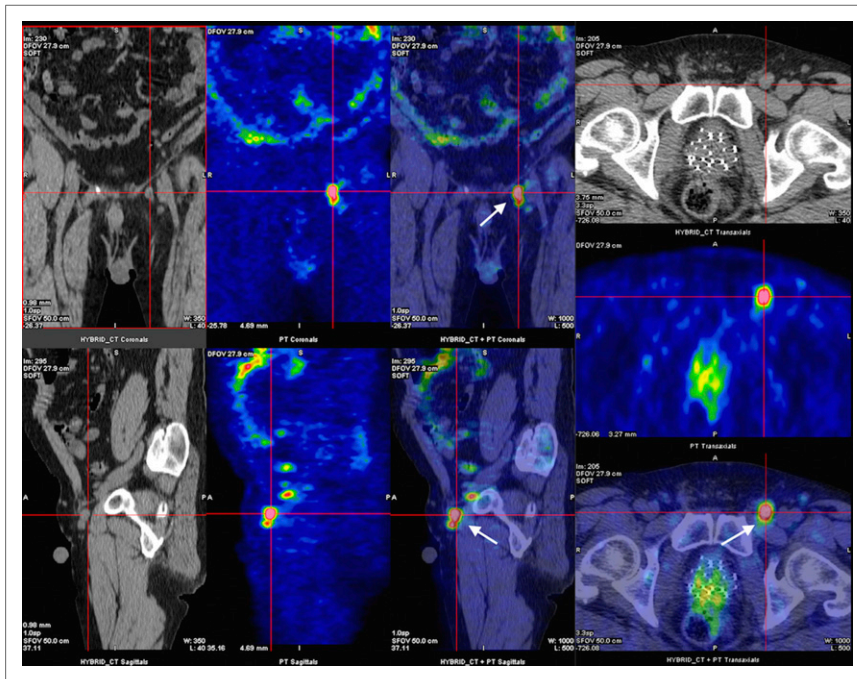
COPYRIGHT © 2016 by the Society of Nuclear Medicine and Molecular Imaging, Inc.

The scan demonstrated a focal concentration of increased metabolic activity ( $\text{SUV}_{\text{max}}$  3.92) in the posterior region of the prostate at the interface of the anterior wall of the rectum (Fig. 1). Associated thickening of the anterior wall of the rectum was also demonstrated on the CT portion of the scan.

Extensive hypermetabolic lymphadenopathy was noted in the left inguinal region ( $\text{SUV}_{\text{max}}$  2.28, 6.11, 4.51, and 5.05) (Fig. 2) and external iliac chain ( $\text{SUV}_{\text{max}}$  5.42, 2.28, and 3.39)



**FIGURE 1.** Attenuation-corrected PET/CT images in axial, coronal, and sagittal views demonstrating increased metabolic activity in posterior region of prostate at interface with anterior wall of rectum (white arrows) ( $\text{SUV}_{\text{max}}$  3.92), as well as spread to left inguinal node (yellow arrow).



**FIGURE 2.** Attenuation-corrected  $^{11}\text{C}$ -acetate PET/CT images in axial, coronal, and sagittal views showing uptake within large left inguinal lymph node (arrows) ( $\text{SUV}_{\text{max}}$  6.11).

(Figs. 3 and 4), with a smaller lymph node in the right inguinal area anterior to the femoral neurovascular bundle ( $\text{SUV}_{\text{max}}$  1.91).

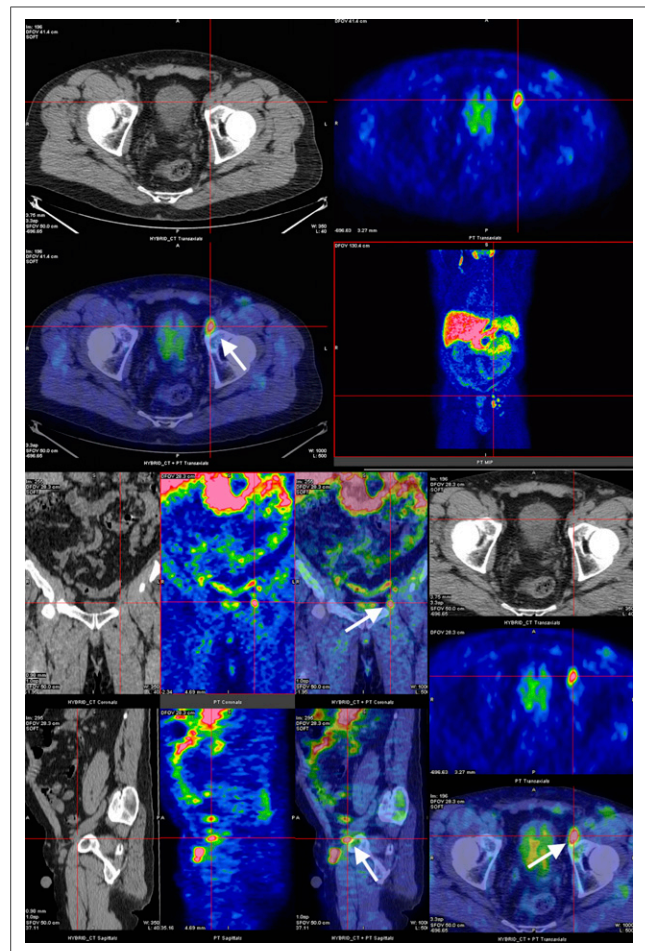
No osseous metastases were seen. The patient declined biopsy and chose to undergo salvage therapy with intensity-modulated radiation.

## DISCUSSION

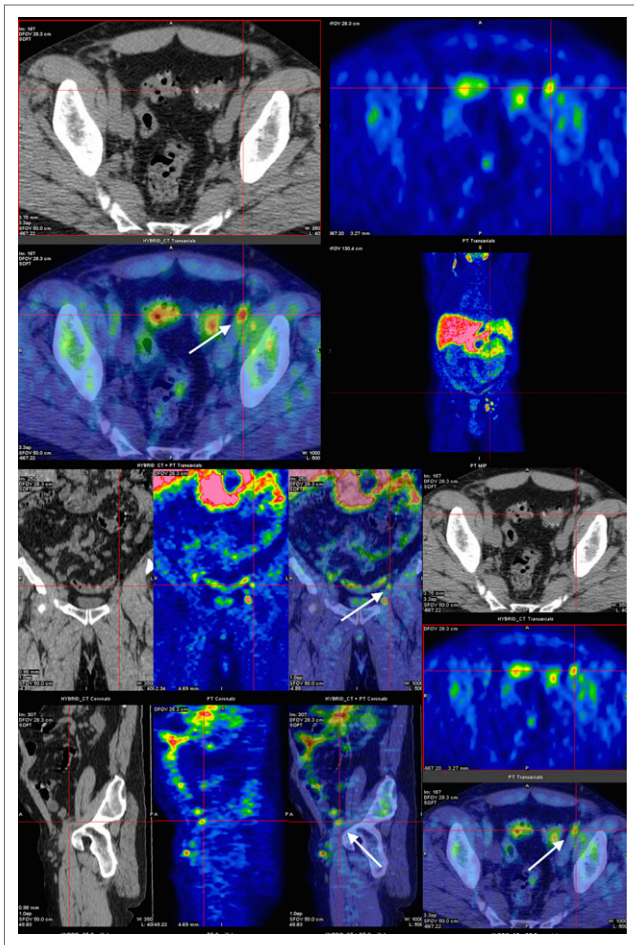
In the anal canal, the dentate line is the landmark for two different systems of lymphatic drainage: above, to the inferior mesenteric and internal iliac nodes, and below, to the superficial inguinal nodes (*1*). In prostate cancer, the external and internal iliac, obturator, presacral, and paraaortic lymph nodes are most often involved in primary lymphatic spread (*2*). Although inguinal lymphadenopathy is rare in prostate carcinoma, involvement of the rectum below the dentate line can be the source of metastasis to inguinal lymph nodes (*3,4*).

Identification of the precise anatomic location of all involved lymph nodes is mandatory if salvage therapy with intensity-modulated radiation or surgery is to be considered.  $^{11}\text{C}$ -acetate, like  $^{11}\text{C}$ -choline and  $^{18}\text{F}$ -choline, is a radioisotope that has been shown to have a strong positive correlation on attenuation-corrected PET/CT imaging with prostate cancer metastases. Once the patient has achieved a prostate-specific antigen threshold of 1.24 ng/mL or a prostate-specific antigen doubling time of less than 6 mo, the scan achieves a putative sensitivity and specificity of 86.6% and 65.8%, respectively (*5*). Currently, the best application of attenuation-corrected  $^{11}\text{C}$ -acetate PET/CT lies in detecting prostate cancer metastasis after biochemical recurrence or in detecting extraprostatic spread before surgery.

Other metabolic imaging, such as attenuation-corrected  $^{18}\text{F}$ -FDG PET/CT, was not performed, as prostate cancer



**FIGURE 3.** Attenuation-corrected PET/CT images in axial, coronal, and sagittal views demonstrating increased  $^{11}\text{C}$ -acetate uptake within left external iliac chain in node of Cloquet (arrows) ( $\text{SUV}_{\text{max}}$  5.42).



**FIGURE 4.** Attenuation-corrected PET/CT images in axial, coronal, and sagittal views showing  $^{11}\text{C}$ -acetate uptake in proximal left external iliac lymph node (arrows) ( $\text{SUV}_{\text{max}}$  3.39).

cells are not particularly glucose-avid and studies have shown the superiority of attenuation-corrected  $^{11}\text{C}$ -acetate PET/CT (5). Similarly, although multiparametric MR imaging has shown tremendous potential in detecting locally recurrent prostate cancer, further studies are needed to elucidate its usefulness in detecting lymph node metastases.

## CONCLUSION

Prostate cancer metastases to the inguinal nodes are rare. In this case, attenuation-corrected  $^{11}\text{C}$ -acetate PET/CT effectively demonstrated prostate cancer recurrence with inguinal node uptake, suggestive of metastatic involvement of the rectum below the dentate line.

## DISCLOSURE

No potential conflict of interest relevant to this article was reported.

## REFERENCES

1. Kaiser AM, Ortega AE. Anorectal anatomy. *Surg Clin North Am.* 2002;82:1125–1138.
2. Jackson AS, Sohaib SA, Staffurth JN, et al. Distribution of lymph nodes in men with prostatic adenocarcinoma and lymphadenopathy at presentation: a retrospective radiological review and implications for prostate and pelvis radiotherapy. *Clin Oncol (R Coll Radiol).* 2006;18:109–116.
3. Huang E, Teh BS, Mody DR, Carpenter LS, Butler EB. Prostate adenocarcinoma presenting with inguinal lymphadenopathy. *Urology.* 2003;61:463.
4. Hamano T, Homma Y, Otsuki Y, Shimizu S, Kobayashi H, Kobayashi Y. Inguinal lymph node metastases are recognized with high frequency in rectal adenocarcinoma invading the dentate line: the histological features at the invasive front may predict inguinal lymph node metastasis. *Colorectal Dis.* 2010;12:e200–e205.
5. Dusing RW, Peng W, Lai SM, et al. Prostate-specific antigen and prostate-specific antigen velocity as threshold indicators in  $^{11}\text{C}$ -acetate PET/CTAC scanning for prostate cancer recurrence. *Clin Nucl Med.* 2014;39:777–783.