

# Incidental Diagnosis of an Asymptomatic Hydatid Cyst Through Low-Grade $^{18}\text{F}$ -FDG Uptake in the Peripheral Rim

Nandigam S. Kumar<sup>1</sup>, Ketaki Barve<sup>2</sup>, Jyotsna Joshi<sup>2</sup>, and Sandip Basu<sup>1</sup>

<sup>1</sup>Radiation Medicine Centre (BARC), Tata Memorial Hospital Annexe, Parel, Mumbai, India; and <sup>2</sup>Department of Pulmonary Medicine, T.N. Medical College, B.Y.L. Nair Hospital, Mumbai, India

Here we present a case of an untreated, asymptomatic, pulmonary hydatid cyst incidentally diagnosed on the basis of atypically low-grade  $^{18}\text{F}$ -FDG uptake in the peripheral rim and a minimal increase in uptake on dual-point  $^{18}\text{F}$ -FDG PET/CT. The patient underwent  $^{18}\text{F}$ -FDG PET/CT for characterization of a solitary lung lesion found on chest radiography and inconclusive findings on contrast-enhanced CT. Although the diagnosis was confirmed by a serum indirect hemagglutination assay positive for *Echinococcus granulosus*, the low-grade  $^{18}\text{F}$ -FDG uptake in the context of the asymptomatic presentation was noteworthy, as it could be related to minimal active inflammation. Our case, together with similar previously published findings, leads to the hypothesis that inflammatory  $^{18}\text{F}$ -FDG uptake may be an additional determinant of the cause of symptoms in these patients.

**Key Words:**  $^{18}\text{F}$ -FDG PET/CT; echinococcus; hydatid cyst; inflammation

**J Nucl Med Technol 2015; 43:292–294**  
DOI: 10.2967/jnmt.115.155408

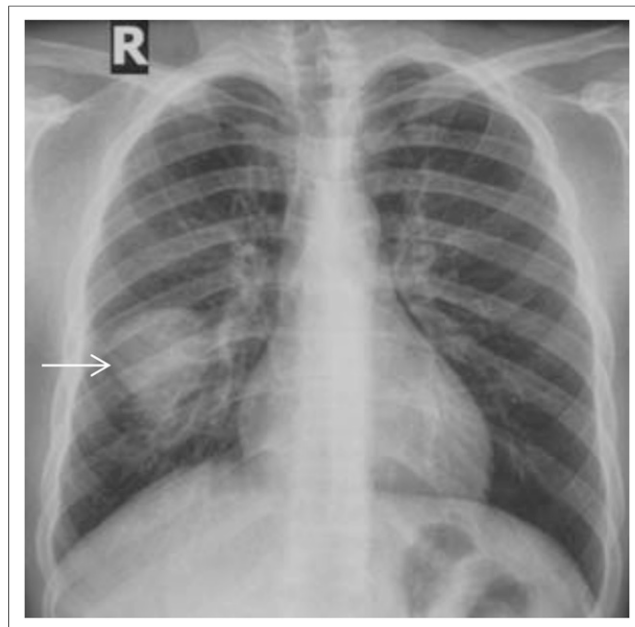
**H**ydatic disease is a parasitic infestation caused by *Echinococcus granulosus*. Hydatid cysts are common in the Mediterranean countries, the Middle and Far East, Europe, Asia, South America, and Australia. It presents as a solitary lesion, multiple cystic lesions, or giant cystic lesions in the lung and liver. A higher proportion of lung cases are discovered incidentally on routine radiographs; most infected people remain asymptomatic until the cyst enlarges sufficiently to cause symptoms. Most symptoms are caused by a mass effect from the cyst volume. The development of complications caused by the cysts changes the clinical presentation. The principal complication is cyst rupture, producing cough, chest pain, and hemoptysis. Diagnosis is through imaging evaluation (a chest radiograph or CT scan), supported by serology in most cases. Chest radiography and CT are the conventional diagnostic modalities applied. However, in this

case study we report that inflammatory activity assessed by  $^{18}\text{F}$ -FDG PET/CT imaging may also be a potential determinant of the cause of symptoms in an individual.

## CASE REPORT

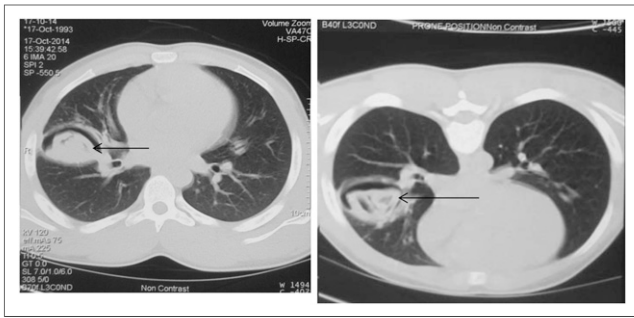
A 21-y-old man living in a village was referred to our institution for further evaluation of a cystic lesion detected incidentally on a chest radiograph obtained as part of a routine preemployment medical examination. On enquiry, he said that for the past 10 d he had been experiencing a mild cough with a salty mucoid expectoration. He was not an addict, and he had no history of respiratory disease or therapy for respiratory disease. He also reported that since childhood, he had frequently been exposed to cattle in the fields of his village. The findings of his general physical and systemic examination were within normal limits.

Chest radiography revealed a cystic lesion in the right lower lobe (Fig. 1). Contrast-enhanced CT of the thorax (Fig. 2) revealed a smooth cavity measuring  $4.8 \times 3.3$  cm in the right lobe of the lung, and both supine and prone images showed a round, dependent soft-tissue mass suggestive of



**FIGURE 1.** Chest radiograph showing homogeneous round opacity (arrow) in right lower lobe.

Received Feb. 11, 2015; revision accepted Apr. 13, 2015.  
For correspondence or reprints contact: Sandip Basu, Radiation Medicine Centre, Bhabha Atomic Research Centre, Tata Memorial Hospital Annexe, Jeebhai Wadia Rd., Parel, Mumbai, Maharashtra, India.  
E-mail: drsanb@yahoo.com  
Published online Jun. 25, 2015.  
COPYRIGHT © 2015 by the Society of Nuclear Medicine and Molecular Imaging, Inc.



**FIGURE 2.** Supine (left) and prone (right) CT scans showing cavity with mobile soft tissue within it.

a fungal ball or the detached membranes of a hydatid cyst. Microscopic examination of sputum showed no evidence of structures resembling scolices or cysts of *E. granulosus*.

The  $^{18}\text{F}$ -FDG PET/CT scan was performed at our institution with 305 MBq of  $^{18}\text{F}$ -FDG and a whole-body full-ring dedicated lutetium yttrium orthosilicate–based time-of-flight scanner (Gemini TF; Philips Healthcare). Images were acquired using a 3-dimensional PET protocol, and data were reconstructed using an iterative row-action maximum-likelihood algorithm and corrected for attenuation using low-dose CT. Dual-point images were acquired with baseline images at 1 and 3 h after injection. The baseline PET/CT scan showed a  $3.3 \times 4.5 \times 4.3$  cm soft-tissue lesion with a central cavitation and a peripheral rim of  $^{18}\text{F}$ -FDG uptake (maximum SUV, 2.56 g/mL). There was evidence of communication between the cyst and the right bronchus (Figs. 3 and 4). Low-grade  $^{18}\text{F}$ -FDG uptake in the right and left axillary lymph nodes with maintenance of fatty hilum was seen. Dual-point imaging after 3 h showed the peripheral rim of  $^{18}\text{F}$ -FDG uptake minimally increased (maximum SUV, 2.98 g/mL). The imaging findings led to a diagnosis of hydatid cyst. A serum indirect hemagglutination assay was positive for

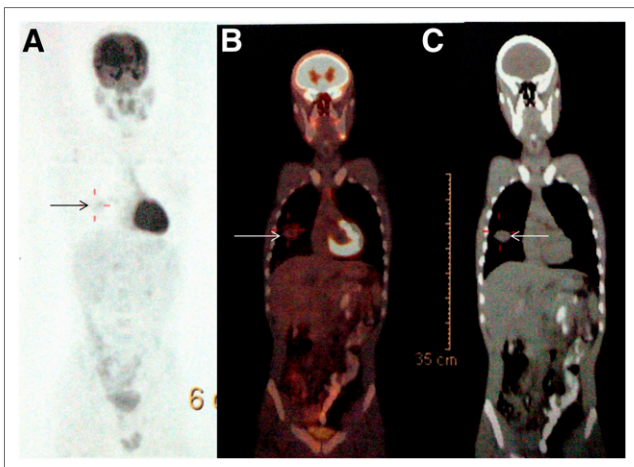
*E. granulosus*. The patient was advised to start treatment with albendazole tablets, 400 mg orally once daily for 12 mo.

## DISCUSSION

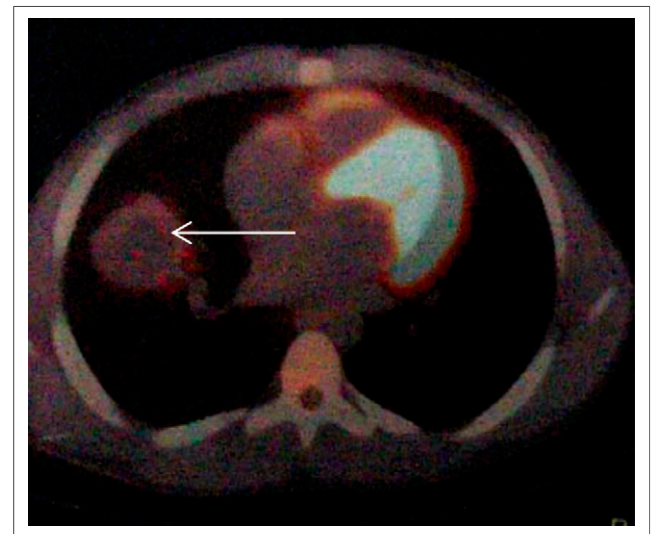
$^{18}\text{F}$ -FDG PET/CT is a relatively new diagnostic imaging modality commonly used in oncology. In nononcologic practice also, the evidence base for the use of PET/CT in various clinical indications is being gathered (1). PET/CT with  $^{18}\text{F}$ -FDG has the advantage of defining the function of a pathologic finding, such as inflammatory activity (1). When there is no other modality to specifically characterize an undiagnosed disease, studies are regularly repeated to support the findings of the prior studies.

In our case, the radiography features were not typical and the CT features were suggestive of a hydatid cyst. Characteristic contrast-enhanced CT signs of a hydatid cyst such as the air-bubble sign, water lily sign, or meniscus sign were not seen in this case. Sputum examination was negative for *E. granulosus* remnants.

PET/CT played an important role in characterizing this lesion by revealing its doughnut characteristics. This case also reinforces that a history of exposure to cattle can assist in affirming a suspected hydatid cyst in the right clinical context. The serum indirect hemagglutination and PET/CT findings strongly supported the diagnosis in our case, for which the chest radiography and contrast-enhanced CT features were not typical. Several studies (2–7) have reported the  $^{18}\text{F}$ -FDG PET/CT appearance of hydatid cyst, with most of them demonstrating intense  $^{18}\text{F}$ -FDG uptake in the periphery. A case record of Kadam et al. (2) for hydatid cyst described the doughnut sign, which matched the PET/CT findings in our case. However, there was a striking difference in the intensity of  $^{18}\text{F}$ -FDG activity between our case and theirs. Demir et al. (3) described a liver lesion with peripheral



**FIGURE 3.** (A) PET scan showing peripheral low-grade  $^{18}\text{F}$ -FDG uptake (arrow) with central area of photopenia (doughnut sign). (B) PET/CT scan showing central cavitory lesion (arrow) on CT portion of image. (C) CT scan showing peripheral  $^{18}\text{F}$ -FDG uptake (arrow) and central cavitory hypodense area.



**FIGURE 4.** Transaxial fused PET/CT scan showing peripheral  $^{18}\text{F}$ -FDG uptake (arrow) and central hypodense area with cavitation. Lesion appears to be communicating with bronchus.

<sup>18</sup>F-FDG uptake, central photopenia, and hypodense areas on PET/CT images. After resection of the lesion, it proved to be a hydatid cyst. On the other hand, Kurt et al. (4) reported no <sup>18</sup>F-FDG uptake in pulmonary nodules that, after resection, proved to be a hydatid cyst.

## CONCLUSION

Along with its use in assessing disease extent and treatment response, <sup>18</sup>F-FDG PET/CT can play a role in establishing a diagnosis of hydatid cyst (ruptured or infected or both). Detection of the inflammatory component through this modality can help determine the diagnosis.

## DISCLOSURE

No potential conflict of interest relevant to this article was reported.

## REFERENCES

1. Basu S, Yadav M, Joshi JM. Potential of FDG-PET and PET/CT in non-malignant pulmonary disorders: much more than currently perceived? Making the case from experience gained in Indian scenario. *Nucl Med Commun.* 2014;35:689–696.
2. Kadam SG, Basu S, Joshi JM. Doughnut sign on FDG-PET scan in a ruptured lung hydatid cyst. *Indian J Chest Dis Allied Sci.* 2012;54:185–187.
3. Demir H, Halac M, Yilmaz S, Isgoren S, Sonmezoglu K, Uslu I. A doughnut sign of a hydatid cyst of the liver on F-18 FDG PET/CT. *Clin Nucl Med.* 2008;33: 876–877.
4. Kurt Y, Sücüllü I, Filiz AI, Urhan M, Akin ML. Pulmonary echinococcosis mimicking multiple lung metastasis of breast cancer: the role of fluoro-deoxy-glucose positron emission tomography. *World J Surg Oncol.* 2008;6:7.
5. Basu S, Baghel NS. FDG PET in ruptured pulmonary hydatid cyst: assessing disease extent and tracking the path of drainage. *Clin Nucl Med.* 2010;35: 471–472.
6. Rangarajan V, Dua S, Purandare NC, Shah S, Sharma AR. Pulmonary hydatid cyst detected on FDG PET-CT. *Clin Nucl Med.* 2010;35:298–299.
7. Abhyankar A, Joshi J, Basu S. FDG uptake in unilateral breast related to breast-feeding practice in a patient of pulmonary hydatid cyst. *Clin Nucl Med.* 2012;37: 676–678.