

---

---

# Dynamic Observation of $^{18}\text{F}$ -FDG Uptake After Oral Administration in a Healthy Subject

Kaixiu Zhang<sup>1</sup>, Xuemei Wang<sup>1</sup>, Linjun Hao<sup>2</sup>, Zhenfeng Zhao<sup>1</sup>, and Chunlei Han<sup>3</sup>

<sup>1</sup>Department of Nuclear Medicine, Affiliated Hospital of Inner Mongolia Medical University, Huhehaote, China; <sup>2</sup>Department of Health Center, Affiliated Hospital of Inner Mongolia Medical University, Huhehaote, China; and <sup>3</sup>Turku PET Center, Turku University Hospital, Turku, Finland

---

PET with  $^{18}\text{F}$ -FDG is a widely used imaging modality in cancer patients. Traditionally,  $^{18}\text{F}$ -FDG is administered intravenously. However, patients with difficult venous access are not rare in clinical practice. The purpose of the current study was to investigate the dynamic process of  $^{18}\text{F}$ -FDG distribution after oral administration in order to determine the optimal imaging acquisition time in human subjects. On the basis of tissue time-activity curves, we determined the time that was required to reach 90% of the maximal uptake in target organs. In a 50-year-old healthy subject with oral  $^{18}\text{F}$ -FDG administration, we found that  $^{18}\text{F}$ -FDG uptake maximized at 60 min for most organs except for the gray matter of the brain, which continued to accumulate  $^{18}\text{F}$ -FDG after 60 min. Time to 90% was 22 min for liver, 36 min for kidneys, 48 min for myocardium, 50 min for bladder, 56 min for sigmoid colon, and greater than 61 min for gray matter of the brain. We suggest that PET images be acquired at around 60 min after oral  $^{18}\text{F}$ -FDG administration for most organs. For the brain, a longer interval is required before acquisition.

**Key Words:** oral; dynamic; FDG; PET

**J Nucl Med Technol 2013; 41:78–80**

DOI: 10.2967/jnmt.112.116533

---

**P**ET imaging with  $^{18}\text{F}$ -FDG has been shown to be sensitive and cost-effective for evaluating cancer patients at various phases such as diagnosis, staging, and therapy assessment. Typically,  $^{18}\text{F}$ -FDG is administered to patients intravenously.  $^{18}\text{F}$ -FDG venous injection is simple and useful in clinical routine, but venous access cannot be established in all patients, such as cancer patients with a history of extensive chemotherapy.

Oral administration of  $^{18}\text{F}$ -FDG has been considered, but only a few clinical reports on this topic have been published so far. Franc et al. (1) reported a patient with pulmonary nodules in whom oral administration of  $^{18}\text{F}$ -FDG clearly

showed the nodules, which then were confirmed by tissue biopsy. In another report, by Nair et al. (2), 7 patients with lung cancer, non-Hodgkin lymphoma, or a thyroid nodule underwent PET imaging after both oral and intravenous administration of  $^{18}\text{F}$ -FDG.  $^{18}\text{F}$ -FDG uptake into lesions after oral administration was comparable to that after intravenous administration. These clinical reports and some animal studies (3,4) revealed that oral administration of  $^{18}\text{F}$ -FDG may be an alternative to intravenous injection for patients with difficult venous access.

Clinically, routine  $^{18}\text{F}$ -FDG PET scanning is usually performed at 50–60 min after intravenous injection for patients with tumors. But the optimal time point for performing PET imaging after oral administration of  $^{18}\text{F}$ -FDG is not yet known. We thus report a case here in which we determined the optimal time point to acquire clinical PET images through dynamic observation after oral  $^{18}\text{F}$ -FDG administration to a healthy subject.

## CASE REPORT

A 50-year-old healthy female volunteer was enrolled into this study at the first affiliated hospital of Inner Mongolia Medical University. She gave informed consent to participate in this study. Before the PET examination, she fasted for 24 h. The PET/CT scanner was a Discovery ST8 (GE Healthcare). The oral  $^{18}\text{F}$ -FDG dosage was 11.1 MBq/kg (2 times higher than the intravenous dosage). Whole-body PET/CT imaging was performed at 5, 20, 35, 55, and 70 min after oral  $^{18}\text{F}$ -FDG administration (Fig. 1). The PET images were decay-corrected. During and after the PET/CT examination, the volunteer did not have any discomfort. PET/CT images were analyzed using Carimas2.6 (a medical image visualization and analysis packaged developed in Turku PET Centre of Finland [http://www.turkupetcentre.fi/carimas]). Dynamic images in transverse, sagittal, and coronal views are shown in Figure 2A. Regions of interest were drawn on the gray matter of the brain, the blood pool of the left ventricular cavity, and the myocardium, oropharynx, stomach, kidneys, small intestine, bladder, sigmoid colon, and liver. Mean standardized uptake values were calculated, and tissue time-activity curves were obtained for each region of interest as shown in Figure 2B. Furthermore, time-activity curves were normalized by

---

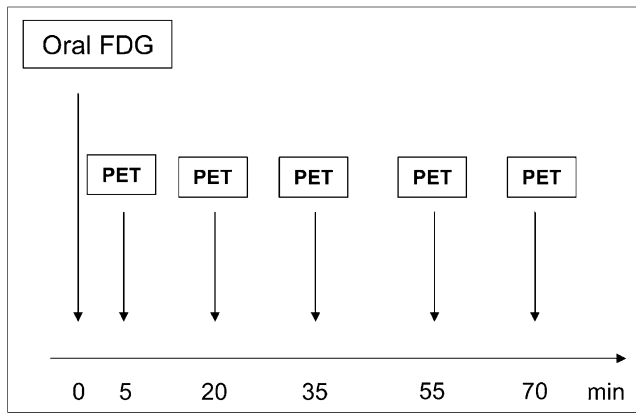
Received Jan. 17, 2013; revision accepted Mar. 6, 2013.

For correspondence contact: Xuemei Wang, Department of Nuclear Medicine, Affiliated Hospital of Inner Mongolia Medical University, Hohhot 010050, China.

E-mail: wangxuemei2260@yahoo.com.cn

Published online Apr. 22, 2013.

COPYRIGHT © 2013 by the Society of Nuclear Medicine and Molecular Imaging, Inc.



**FIGURE 1.** PET/CT imaging protocol.

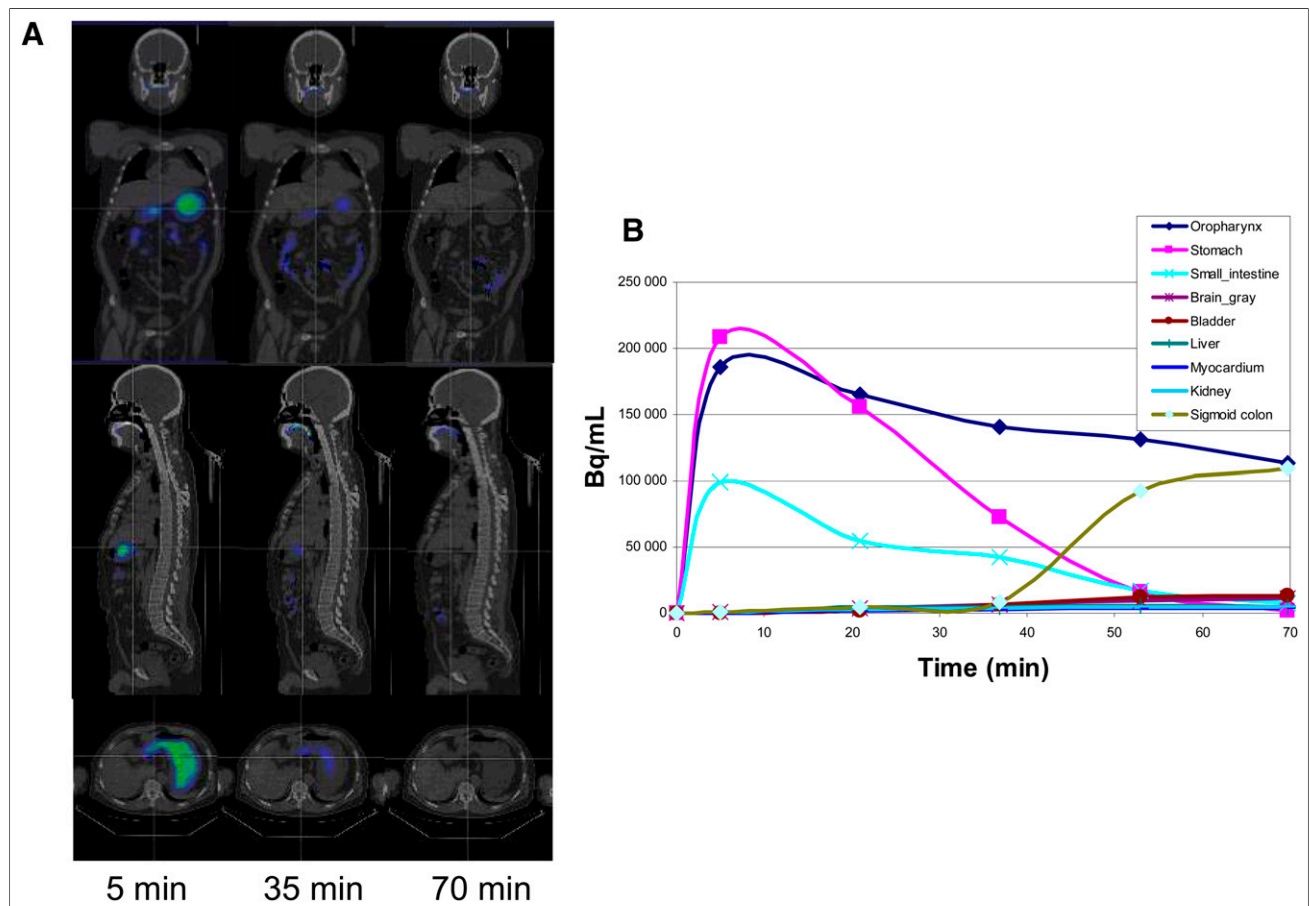
maximal uptake for each region of interest as shown in Figure 3A. Normalized time–activity curves were fitted by a cubic spline line. The optimal time required for  $^{18}\text{F}$ -FDG uptake in the target organ was defined as the period between oral administration and 90% maximal uptake based on the normalized time–activity curve. This optimal time includes the interval required for  $^{18}\text{F}$ -FDG to be transported to and accumulate in the target organ after oral

administration and should be the best time for PET scanning. In our volunteer, this optimal time was 22 min for liver, 36 min for kidneys, 48 min for myocardium, 50 min for bladder, 56 min for sigmoid colon, and greater than 61 min for gray matter of the brain, as shown in Figure 3B. Figure 2 indicates that in the gray matter of the brain,  $^{18}\text{F}$ -FDG uptake had not yet peaked by 75 min. Therefore, on the basis of this one case, it seems that for all target organs but the brain, PET scanning can be performed at 50–60 min after oral  $^{18}\text{F}$ -FDG administration, similar to intravenous injection. A longer uptake interval may be needed before brain scanning.

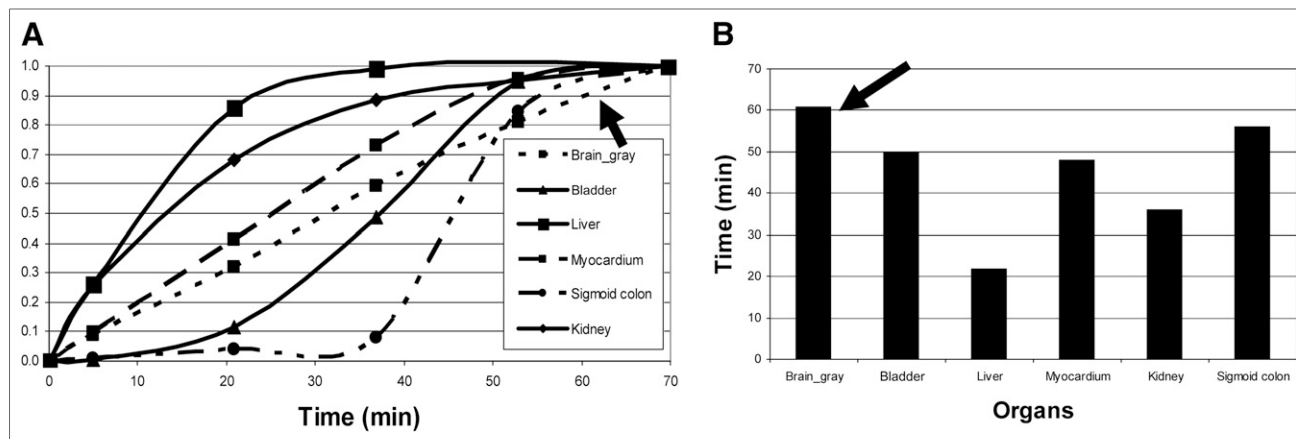
## DISCUSSION

In the current study, we investigated the dynamic process of  $^{18}\text{F}$ -FDG uptake after oral administration in a healthy volunteer. The optimal uptake times estimated from this study provide a reference for clinical PET imaging acquisition.

In clinical applications, intravenous administration of  $^{18}\text{F}$ -FDG has traditionally been the routine.  $^{18}\text{F}$ -FDG has been widely used for PET examinations, especially in clinical oncology. Although most PET centers have encountered patients in whom venous access is obviously difficult, especially those who have been receiving chemotherapy, publi-



**FIGURE 2.** Dynamic image series and tissue time–activity curves. (A) Images at 5, 35, and 70 min (top, coronal; middle, sagittal; bottom, transverse). (B) Tissue time–activity curves from different organs.



**FIGURE 3.** Normalized tissue time–activity curves (A) and time to 90% of maximal uptake (B).  $^{18}\text{F}$ -FDG uptake of gray matter of brain does not reach maximum at 70 min, as indicated by arrows.

cations on the oral administration of  $^{18}\text{F}$ -FDG are rare. However, published case reports (1,2) seem to indicate that oral administration of  $^{18}\text{F}$ -FDG may be a potential alternative to venous administration.

To develop a method for imaging gastrointestinal absorption after oral drug administration, several PET studies have been performed using  $^{18}\text{F}$ -FDG as a probe in animals and humans (3). From these studies, absorption, biodistribution, and the pharmacologic kinetics of  $^{18}\text{F}$ -FDG after oral administration have been systematically investigated. For example, Yamashita et al. (5), working with rats, found that all parts of the small intestine absorbed  $^{18}\text{F}$ -FDG and that the ratio of absorption between  $^{18}\text{F}$ -FDG and glucose was 0.58 (4.49 cm/s for  $^{18}\text{F}$ -FDG vs. 7.71 cm/s for D-glucose). Shingaki et al. (6), working with humans, avoided potential radiation exposure to the esophagus and thyroid by inventing a novel method for oral administration of  $^{18}\text{F}$ -FDG—enclosure in a soft gelatin capsule. They showed that this new method safely delivered  $^{18}\text{F}$ -FDG to the gastrointestinal tract and that the  $^{18}\text{F}$ -FDG was released and absorbed quickly.

From the present study, we found that at around 60 min after oral administration, uptake of  $^{18}\text{F}$ -FDG in most organs was near the maximum. Therefore, we suggest that, other than for brain imaging, PET acquisitions should begin 60 min after oral administration of  $^{18}\text{F}$ -FDG. A longer period of uptake may be needed before imaging of the brain, as is also in accordance with the findings of a previous investigation (7).

This study had limitations. Only a single subject was investigated. Furthermore, that subject was healthy instead of being a cancer patient, and uptake in tumor tissue would be different from uptake in normal tissues. These limitations will be considered in any future studies.

#### DISCLOSURE

No potential conflict of interest relevant to this article was reported.

#### REFERENCES

1. Franc B, Carlisle MR, Segall G. Oral administration of F-18 FDG to evaluate a single pulmonary nodule by positron emission tomography in a patient with poor intravenous access. *Clin Nucl Med.* 2003;28:541–544.
2. Nair N, Agrawal A, Jaiswar R. Substitution of oral  $^{18}\text{F}$ -FDG for intravenous  $^{18}\text{F}$ -FDG in PET scanning. *J Nucl Med Technol.* 2007;35:100–104.
3. Higashi T, Fisher SJ, Nakada K, Romain DJ, Wahl RL. Is enteral administration of fluorine-18-fluorodeoxyglucose (F-18 FDG) a palatable alternative to IV injection? Pre-clinical evaluation in normal rodents. *Nucl Med Biol.* 2002;29:363–373.
4. Martinez ZA, Colgan M, Baxter LR Jr, et al. Oral  $^{18}\text{F}$ -fluoro-2-deoxyglucose for primate PET studies without behavioral restraint: demonstration of principle. *Am J Primatol.* 1997;42:215–224.
5. Yamashita S, Takashima T, Kataoka M, et al. PET imaging of gastrointestinal absorption of orally administered drugs in conscious and anesthetized rats. *J Nucl Med.* 2011;52:249–256.
6. Shingaki T, Takashima T, Wada Y, et al. Imaging of gastrointestinal absorption and biodistribution of an orally administered probe using positron emission tomography in humans. *Clin Pharmacol Ther.* 2012;91:653–659.
7. Masud M, Yamaguchi K, Rikimaru H, et al. Evaluation of resting brain conditions measured by two different methods (i.v. and oral administration) with  $^{18}\text{F}$ -FDG-PET. *Ann Nucl Med.* 2001;15:69–73.