

---

---

# The Role of PET and PET/CT in Managing the Care of Lymphoma Patients

Westley C. Evans, David Gilmore, and Jeffrey English

*Beth Israel Deaconess Medical Center, Boston, Massachusetts*

---

The clinical use of PET and PET/CT aids physicians and patients in developing lymphoma prognoses, specifically for Hodgkin disease and aggressive types of non-Hodgkin lymphoma. PET and PET/CT are used to initially stage lymphoma, restage disease, and check for remission or recurrence of malignant tissue after treatment. PET/CT is more sensitive and specific than CT alone and has better accuracy concerning lymphoma relapse and remission. In conjunction with other tests, such as blood laboratory work and biopsy, PET and PET/CT allow the lymphoma to be staged appropriately and treated correctly. Results from PET and PET/CT contribute to the formation of a specialized treatment plan that leads to the best possible care for each individual patient. PET and PET/CT positively affect the management of patients with lymphoma.

**Key Words:** lymphoma; PET; PET/CT; staging; relapse; remission

**J Nucl Med Technol 2011; 39:190–194**

DOI: 10.2967/jnmt.110.082982

---

**L**ymphoma is a cancer of the lymph tissue and represents the fifth most common cancer in the United States, with 74,030 estimated new cases in 2010 (1). Lymphoma can be differentiated into Hodgkin disease (HD) and non-Hodgkin lymphoma (NHL) by the presence of Reed–Sternberg cells. A Reed–Sternberg cell is an abnormal B cell that is larger than normal white blood cells and is found only in HD through examination under a microscope (2). All other types of lymphoma are considered NHL.

Lymph tissue is found throughout the body in lymph nodes, the spleen, the thymus gland, adenoids and tonsils, the digestive tract, and bone marrow. It comprises mainly lymphocytes, which can be differentiated into B and T cells. B cells make antibodies, and 85% of all NHL affects the B-cell lymphocytes (3). T cells come in many different forms, including those that specialize in fighting off bacteria, fungi, and viruses; those that produce cytokines; and those that work with other immune system cells to expedite

or slow the body's immune response (2). The type of lymphocyte affected by the lymphoma is important, as there are various types of lymphoma that arise from different types of lymphocytes, and each is treated differently.

HD usually involves the upper mediastinum and primarily affects people aged 15–34 y and people older than 55 y (3). HD can be categorized into 4 different histologic subtypes: nodular sclerosis (most common), lymphocyte predominance, mixed cellularity, and lymphocyte depletion (4). An estimated 8,490 cases of HD were newly diagnosed in 2010 (1).

NHL is more prevalent than HD, as there were an estimated 65,540 patients newly diagnosed in 2010, and usually affects those over the age of 60 y (1,2). NHL can be divided into slow-growing types, more aggressive types, and fast-growing types (1). There are over 20 types of NHL, the most common of which are diffuse large B-cell lymphoma and follicular lymphoma, which together account for more than half of all NHL cases (5). Other common types include small lymphocytic lymphoma, mantle cell lymphoma, peripheral T-cell lymphoma, and marginal-zone B-cell lymphoma (5). Together, HD and NHL resulted in 21,530 deaths in 2010 (1).

## STAGING

Staging is a vitally important process in treating cancer of any type, including lymphoma. Accurate staging ensures that the patient's treatment regimen is not too weak (not powerful enough to combat the disease) or, conversely, too strong (unnecessarily toxic to the patient). Systems used to stage the disease include the Ann Arbor Classification system and the International Working Group response criteria, among others.

The Ann Arbor Classification grades the lymphoma on a scale from I to IV according to the extent of involvement of the lymphoma. Also, symptoms associated with the lymphoma, and the bulkiness of the tumor, are incorporated into staging. Staging consists of a thorough history report, a physical examination, laboratory studies, biopsy, and bone marrow biopsy. Also, radiologic examinations are used to properly stage lymphoma, such as CT, MRI, ultrasound, and <sup>18</sup>F-FDG PET, which may or may not be accompanied by low-dose CT (PET/CT). PET scans can be done with or without CT (usually low-dose, low-resolution), which is used for attenuation correction and lesion localization (6).

---

Received Sep. 15, 2010; revision accepted Apr. 15, 2011.  
For correspondence or reprints contact: Westley C. Evans, Beth Israel Deaconess Medical Center, 300 Brookline Ave., Boston, MA 02215.  
E-mail: westley.evans@childrens.harvard.edu  
Published online Jul. 27, 2011.  
COPYRIGHT © 2011 by the Society of Nuclear Medicine, Inc.

The International Working Group response criteria have been widely used since their inception in 1999 to provide a more standardized way to treat various levels of lymphoma involvement. This classification system also uses lymph node biopsy, bone marrow evaluation, and tumor size to determine the stage of disease and proper response criteria. To incorporate the new technology of  $^{18}\text{F}$ -FDG PET, as well as immunohistochemistry and flow cytometry, revised response criteria were published in 2007 (7).

One example of a study demonstrating that PET adds to the accuracy of staging was done by Juweid et al. In that study, 54 patients with aggressive NHL were more accurately staged using PET and the International Working Group response criteria than using the International Working Group response criteria alone (8). Pelosi et al. demonstrated in 337 consecutive patients (130 with HD and 207 with aggressive NHL) that adding PET to bone marrow biopsy increases the diagnostic accuracy and is essential to the staging process (9).

### **$^{18}\text{F}$ -FDG UPTAKE IN LYMPHOMA**

PET shows sites in the body that demonstrate increased glucose metabolism. As Nobel Laureate Otto Heinrich Warburg discovered, because cancer are rapidly dividing, they use adenosine triphosphate at increased levels, a chemical that is produced by glycolysis (10). The radioactive tracer used,  $^{18}\text{F}$ -FDG, is chemically similar to sugar, or glucose. As a result, the  $^{18}\text{F}$ -FDG is actively transported at the first site of glycolysis and converted into  $^{18}\text{F}$ -FDG-6-phosphate.  $^{18}\text{F}$ -FDG, however, is then trapped at the site of glucose metabolism, as it cannot serve as a substrate for the next enzyme of glycolysis (11).

Areas of abnormal  $^{18}\text{F}$ -FDG uptake can be assessed visually and with the assistance of standardized uptake values (SUVs). SUVs semiquantitatively calculate the concentration of metabolic activity in a certain area divided by the dose administered, taking into account patient weight and decay time of dose (11). The equation is as follows (12):

$$\frac{\text{Decay-corrected activity [kBq]} / \text{tissue volume [mL]}}{\text{Injected } ^{18}\text{F-FDG avidity [kBq]} / \text{body weight [g]}}$$

Incorporation of this metabolic information permits physicians to observe the reaction to their patient's treatment and individualize the prognosis. Because there are many variables such as image noise, resolution, and ROI definition, it is recommended that SUVs not be used alone for diagnostic purposes. However, SUVs aid in the visual assessment to differentiate benign and malignant tumors (13).

### **COMPARISON OF PET/CT TO DIAGNOSTIC CT**

PET and PET/CT can be used to initially stage lymphoma, to restage lymphoma, to detect recurrence of lymphoma throughout treatment, and to follow up with patients who are in remission. At M.D. Anderson Cancer Center, in Houston, Texas, more than half of all PET/CT

scans performed are indicated for lymphoma (14). An advantage of PET/CT for lymphoma is that it can differentiate between actively malignant tissue and necrotic tissue, whereas CT alone and MRI are unable to tell the difference. CT and MRI identify abnormal masses, nodal enlargement, and alteration of normal anatomy, whereas PET/CT demonstrates the metabolic activity of the cancer cells. A CT scan and MRI scan have decreased specificity because they are unable to decipher between malignant tissue and fibrosis, whereas PET/CT is able to differentiate.

CT is much more widely available than PET/CT and more commonly used for staging, but PET/CT has shown greater sensitivity in imaging extranodal regions of interest (15). Extranodal regions of interest for lymphoma include bone marrow, liver, lungs, and pleura.

Also, diagnostic whole-body CT has a high radiation dose, up to 30 mSv, whereas a PET scan accompanied by a low-dose CT scan typically has a radiation dose of 7 mSv from the CT component and 8 mSv from the  $^{18}\text{F}$ -FDG, for a total of 15 mSv (16).

Recent evidence suggests that lymphoma patients undergoing dual-modality PET/CT may not need to additionally undergo whole-body CT. The study, by Raanani et al., showed that PET/CT, as opposed to CT alone, changed patient care management decisions in 25% of NHL patients and 33% of HD patients (17).

Recent studies suggest that PET is also more sensitive than CT for staging NHL. A retrospective study by Foo et al. included 38 patients who underwent PET: 24 at initial staging and 46 at restaging. The PET scans were compared with CT scans and, for disease validation, were compared with clinical follow-up or biopsy. For initial staging, PET scans had a 96% sensitivity rate, whereas CT had only a 71% sensitivity rate. In 29% of patients, PET also identified sites of disease not present on CT (18).

A study by Guay et al. compared PET with CT to determine predictive value and diagnostic accuracy in HD. This study included 48 patients who underwent PET and CT. The study showed PET to have a positive predictive value, negative predictive value, and diagnostic accuracy of 92%, compared with a significantly lower diagnostic accuracy of 56% for CT (19).

### **$^{67}\text{Ga}$ -CITRATE IMAGING IN LYMPHOMA**

PET/CT produces higher-quality images than  $^{67}\text{Ga}$ -citrate imaging, the nuclear medicine examination done formerly to find malignant tissue. PET/CT is sensitive for imaging the abdomen, whereas  $^{67}\text{Ga}$  is taken up diffusely in benign tissue of the abdomen, making the interpretation of  $^{67}\text{Ga}$  scans difficult (20). PET/CT is more convenient, as a PET/CT scan can be obtained 1 h after injection, whereas  $^{67}\text{Ga}$  scans must be obtained 2–3 d after injection.

### **LIMITATIONS OF PET**

The tracer  $^{18}\text{F}$ -FDG is not specific to cancer cells and will show other sites of glucose metabolism, such as

myocardium, brain, and skeletal muscle. As a result, patients are asked to avoid exercise for 24 h before a PET/CT scan and are encouraged to relax and refrain from excessive talking after their  $^{18}\text{F}$ -FDG injection.  $^{18}\text{F}$ -FDG will also be taken up at sites of infection and inflammation, as is common for lymphoma patients, who may be imaged while they are immunosuppressed or after radiation therapy. Abnormal uptake is often seen focally in hyperplasia of the thymus and diffusely in both the bone marrow and spleen after chemotherapy (12). Consequently, false-positive results can occur. The International Harmonization Project guidelines suggest that PET/CT ideally be done at 6–8 wk, and no less than 3 wk, after treatment (7,21). Because radiation therapy can cause inflammation for up to 3 mo after treatment, the patient treatment history should be noted (12).

In addition, tumors with low glucose activity may not show malignant tissue on a PET/CT scan, particularly in the case of slow-growing or low-grade lymphoma, which would cause a false-negative result. In particular, extranodal marginal-zone lymphoma and T-cell cutaneous lymphoma demonstrate variable  $^{18}\text{F}$ -FDG uptake (15). Also, lesions smaller than 5–10 mm may not be resolved on a PET/CT scan (14). As a result, it is recommended that PET/CT not be the only modality used for imaging tumors; however, the sensitivity of the test can serve to complement other modalities to determine prognosis for the patient.

Diabetic patients must monitor their blood glucose levels and ensure that they are not too high before  $^{18}\text{F}$ -FDG injection. It is the responsibility of the nuclear medicine technologist to check the glucose level of the patient before radiopharmaceutical administration. Patients with blood glucose levels above 150 mg/dL may have nondiagnostic studies as a result of competition from nonradioactive extracellular glucose (22).

#### **TECHNICAL PROTOCOL FOR PET/CT IN PATIENTS WITH LYMPHOMA**

At Beth Israel Deaconess Medical Center, the technical protocol calls for intravenous injection of  $^{18}\text{F}$ -FDG. The dose is either 555 MBq ( $\pm 10\%$ ) for any person with a body mass index (BMI) of 24.9 or less or 740 MBq ( $\pm 10\%$ ) for any person with a BMI of 25.0 or greater. The patient must take nothing by mouth for at least 4 h before the injection, and the blood glucose must be below 250 mg/dL at the time of injection. The patient should avoid strenuous exercise the day before the scan and should avoid talking once the radiopharmaceutical has been injected. The radiopharmaceutical is taken up for 60 min, and then the patient empties the bladder before undergoing imaging. The low-dose CT parameters are a pitch of 1.5:1, a speed of 15 mm/rotation, a helical thickness of 5 mm, and a voltage of 140 peak kilovoltage. The current depends on BMI. Fifty milliamperes are used for a low BMI (0–25), 75 mA for a medium BMI, and 120 mA for a high BMI (23).

#### **U.S. REIMBURSEMENT FOR PET/CT IN LYMPHOMA**

In 1998, the Center for Medicare and Medicaid Services began to reimburse for PET/CT scans done for lymphoma, among other cancers. The indications allowable for reimbursement of a PET/CT scan for lymphoma include initial staging and—during or after treatment—restaging. For certain indications that are not covered by the Center for Medicare and Medicaid Services, the patient is eligible for reimbursement as long as the hospital has an affiliation with the National Oncology PET Registry.

#### **CASE STUDIES**

##### **Case 1**

Case 1 is a 22-y-old woman who developed symptoms of itchy skin without a rash, feelings of unease, fatigue, and a 9-kg (20-lb) weight loss. She was having difficulty breathing on exertion and was wheezing when lying flat. The patient noticed a lump under her right armpit, which initially brought her to the oncologist.

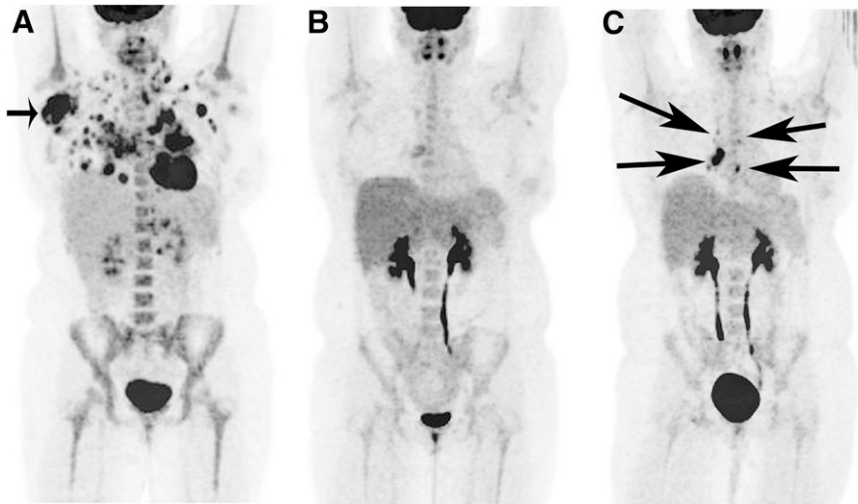
A right axillary biopsy was performed and came back positive for HD. A CT scan was also performed and revealed bilateral axillary mediastinal lymphadenopathy, with bilateral lung nodules in the chest, and a right ovarian cyst. The patient was assessed to have stage IVB HD, nodular sclerosis subtype: IV because of the extent of the disease (lung parenchyma) and B because of the weight loss. A PET/CT scan was scheduled to serve as a baseline reference to which any scans throughout and after treatment could be compared.

A treatment plan consisting of the Stanford V chemotherapy regimen and radiation was chosen. This regimen consists of adriamycin, vinblastine, bleomycin, and vincristine, as well as nitrogen mustard and etoposide. Side effects from this chemotherapy were reviewed with the patient and can include hair loss, nausea, vomiting, fatigue, myelosuppression, and a rare risk for cardiotoxicity and leukemia. The oncologist informed the patient and stated that lymphoma “can be a curable cancer, and benefits from treatment outweigh the risks.”

The initial PET/CT examination (Fig. 1A) was performed 1 wk after the initial appointment with the oncologist. There was diffusely abnormal  $^{18}\text{F}$ -FDG uptake in the following lymph node regions: right and left axillary, left lower jugular chain, right posterior cervical, left supraclavicular, anterior mediastinal, prevascular, anterior cardiac, right pulmonary, and retroperitoneal. This image demonstrated widespread evidence of lymphoma.

Follow-up PET/CT (Fig. 1B) was done 2 mo later and showed remission. There was no abnormal  $^{18}\text{F}$ -FDG avidity. This scan effectively demonstrated the positive response to treatment.

Four months after the initial PET/CT examination (Fig. 1C), a third PET/CT examination was performed, and it showed recurrence of the lymphoma in several anterior mediastinal nodes. As a result of these findings, the patient’s



**FIGURE 1.** Case 1. (A) Initial PET image, with arrow indicating right axillary lymph node involvement of lymphoma. (B) PET image demonstrating remission of lymphoma. (C) PET image demonstrating relapse, with arrows indicating lymphoma involving multiple anterior mediastinal lymph nodes.

treatment regimen was altered to chemotherapy consisting of ifosfamide, mesna, carboplatin, and etoposide. A stem cell transplant, otherwise known as a bone marrow transplant, was also scheduled secondary to PET/CT scan recurrence.

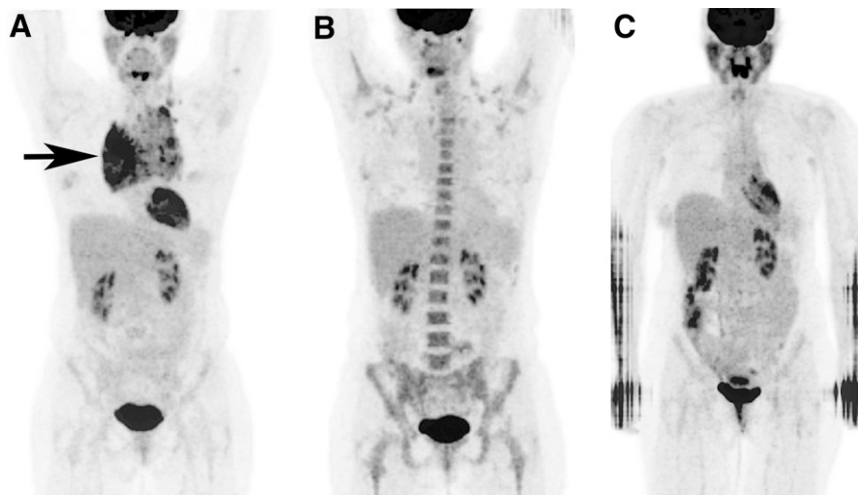
This patient underwent 8 more PET/CT examinations over the next 10 mo to track her response to treatment. Although the scan after the treatment regimen had been altered showed remission, subsequent scans showed new areas of uptake and increased intensity in the chest. Her final scan demonstrated significant progression of the disease, including metastases to the liver. Unfortunately, the results from this scan showed that there was nothing more that could be done for the patient. The patient tried alternative medicine but died 6 mo later.

The PET/CT scans were beneficial to this patient's treatment, providing the clinician valuable information about the extent of disease throughout treatment. The scans showed the initial extent of involvement of lymphoma and then showed remission as a result of treatment. The scans then,

however, demonstrated recurrence of the disease, leading to an altered treatment cycle, which initially worked. Finally, PET/CT demonstrated relapse of the lymphoma in the form of new metastases and widespread progression of the disease.

#### Case 2

Case 2 is a woman who was 43 y old when she initially visited her physician in 2005 for a routine physical examination. The physician found troubling lymph nodes on the left side of her neck. PET/CT was performed to aid in diagnosis, which was confirmed by biopsy. The patient was assessed to have stage IIA HD. The initial PET/CT scan (Fig. 2A) showed abnormal  $^{18}\text{F}$ -FDG uptake in the anterior and superior mediastinum. As a result of the mass, the patient's trachea was displaced posteriorly, and the right pericardium was affected because of compression of the superior vena cava. SUVs of the area were much higher than normal.



**FIGURE 2.** Case 2. (A) Initial PET image, with arrow indicating anterior and superior mediastinum lymph node involvement of lymphoma, causing displacement of trachea. (B) PET image demonstrating remission of lymphoma. (C) Most recent PET image, still demonstrating remission, with patient's arms down during imaging.

A chemotherapy plan was formed as a result of the biopsy and PET/CT results. The chemotherapy regimen, which consisted of adriamycin, bleomycin, vinblastine, and dacarbazine, can have side effects such as hair loss, neutropenia, pulmonary fibrosis, and nausea. The second PET/CT scan (Fig. 2B), 2.5 mo later, showed lack of  $^{18}\text{F}$ -FDG avidity and a decrease in size, demonstrating excellent response to therapy. A PET/CT scan (Fig. 2C) obtained at the time this manuscript was prepared indicated continued remission.

Again, the invaluable clinical information provided by PET/CT is demonstrated, as is its impact on patient management. The nuclear medicine follow-up plan for this patient is to repeat PET/CT every 3 mo during the first year and every 6 mo after that to check for possible relapse.

## CONCLUSION

PET/CT is a valuable asset for the management of lymphoma. It aids in staging, determining response to treatment, and following up by illustrating the metabolic state of the lymphoma. This information allows the oncologist to alter treatment plans for the patient according to the extent of disease involvement. As the case studies illustrate, PET scans done for lymphoma before, during, and after treatment increase the ability to accurately determine the response and prognosis.

## ACKNOWLEDGMENT

No potential conflict of interest relevant to this article was reported.

## REFERENCES

- Jemal A, Siegel R, Xu J, et al. Cancer statistics, 2010. *CA Cancer J Clin*. 2010;60:277–300.
- Non-Hodgkin lymphoma. American Cancer Society Web site. Available at: <http://www.cancer.org/acs/groups/cid/documents/webcontent/003126-pdf.pdf>. Published October 25, 2010. Accessed May 20, 2011.
- Lymphoma. MedlinePlus Web site. Available at: <http://www.nlm.nih.gov/medlineplus/lymphoma.html>. Accessed May 20, 2011.
- Jaffe ES, Harris NL, Stein H, et al. *World Health Organization Classification of Tumours: Pathology and Genetics of Tumours of Haematopoietic and Lymphoid Tissues*. Lyon, France: IARC Press; 2001.
- Lu P. Staging and Classification of Lymphoma. *Semin Nucl Med*. 2005;35:160–164.
- Carbone PP, Kaplan HS, Musshoff K, et al. Report of the Committee on Hodgkin's Disease Staging Classification. *Cancer Res*. 1971;31:1860–1861.
- Cheson BD, Pfistner B, Juweid ME, et al. Revised response criteria for malignant lymphoma. *J Clin Oncol*. 2007;25:579–586.
- Juweid ME, Wiseman GA, Vose JM, et al. Response assessment of aggressive non-Hodgkin's lymphoma by integrated International Workshop Criteria and fluorine-18-fluorodeoxyglucose positron emission tomography. *J Clin Oncol*. 2005;23:4652–4661.
- Pelosi E, Penna D, Douroukas A, et al. Bone marrow disease detection with FDG-PET/CT and bone marrow biopsy during the staging of malignant lymphoma: results from a large multicentre study. *Q J Nucl Med Mol Imaging*. December 9, 2010 [Epub ahead of print].
- Warburg O. On the origin of cancer cells. *Science*. 1956;123:309–314.
- Jhanwar YS, Straus DJ. The role of PET in lymphoma. *J Nucl Med*. 2006;47:1326–1334.
- Allen-Auerbach M, de Vos S, Czernin J. The impact of fluorodeoxyglucose positron emission tomography in primary staging and patient management in lymphoma patients. *Radiol Clin North Am*. 2008;46:199–211.
- Boellaard R, Krak NC, Hoekstra OS, Lammertsma AA. Effects of noise, image resolution, and ROI definition on the accuracy of standard uptake values: a simulation study. *J Nucl Med*. 2004;45:1519–1527.
- Podoloff DA, Macapinlac HA. PET and PET/CT in management of the lymphomas. *Radiol Clin North Am*. 2007;45:689–696.
- Cronin CG, Swords R, Truong MT, et al. Clinical utility of PET/CT in lymphoma. *AJR*. 2010;194:W91–W103.
- Radiation protection of patients: PET/CT scanning. International Atomic Energy Agency Web site. Available at: [http://rpop.iaea.org/RPOP/RPoP/Content/InformationFor/HealthProfessionals/6\\_OtherClinicalSpecialities/PETCTscan.htm](http://rpop.iaea.org/RPOP/RPoP/Content/InformationFor/HealthProfessionals/6_OtherClinicalSpecialities/PETCTscan.htm). Accessed May 20, 2011.
- Raanani P, Shasha Y, Perry C, et al. Is CT scan still necessary for staging in Hodgkin and non-Hodgkin lymphoma patients in the PET/CT era? *Ann Oncol*. 2006;17:117–122.
- Foo SS, Mitchell PL, Berlangieri SU, et al. Positron emission tomography scanning in the assessment of patients with lymphoma. *Intern Med J*. 2004;34:388–397.
- Guay C, Lepine M, Verreault J, et al. Prognostic value of PET using  $^{18}\text{F}$ -FDG in Hodgkin's disease for post treatment evaluation. *J Nucl Med*. 2003;44:1225–1231.
- Anderson KC, Leonard RC, Canellos GP, Skarin AT, Kaplan WD. High-dose gallium imaging in lymphoma. *Am J Med*. 1983;75:327–331.
- Juweid ME, Stroobants S, Hoekstra OS, et al. Use of positron emission tomography for response assessment of lymphoma: consensus of the Imaging Subcommittee of International Harmonization Project in Lymphoma. *J Clin Oncol*. 2007;25:571–578.
- Christian PE, Waterstram-Rich KM. *Nuclear Medicine and PET/CT*. St. Louis, MO: Mosby Elsevier; 2007:372.
- Procedure Manual: PET/CT Scan Tumor Imaging*. Boston, MA: Beth Israel Deaconess Medical Center, Division of Nuclear Medicine; 2008.