
The Value of Quantitative Uptake of ^{99m}Tc -MDP and ^{99m}Tc -HMPAO White Blood Cells in Detecting Osteomyelitis in Violated Peripheral Bones

Nasser S. Ballani¹⁻³, Fawaz Abu Al-Huda^{2,3}, Haider A. Khan^{2,3}, Shihab Al-Mohannadi^{2,3}, Hanan Mahmood^{2,3}, and Farha Al-Enezi^{2,3}

¹Biomedical Sciences, Lebanese International University, Beirut, Lebanon; ²Radiologic Sciences, Kuwait University, Kuwait; and ³Nuclear Medicine Department, Kuwait Center for Specialised Surgery, Kuwait

Our objective in this study was to evaluate whether measurement of quantitative uptake of ^{99m}Tc -methylene diphosphate (MDP) and ^{99m}Tc -hexamethylpropyleneamine oxime (HMPAO) white blood cells (WBCs) is useful in detecting osteomyelitis in peripheral bony lesions. **Methods:** Twenty-four patients (12 men and 12 women; age range, 25–72 y) were referred for imaging because of clinically suspected osteomyelitis. They had a traumatic fracture ($n = 10$), knee prosthesis ($n = 5$), hip prosthesis ($n = 2$), diabetic foot ($n = 4$), or chronic osteomyelitis ($n = 3$). Three-phase bone scanning and ^{99m}Tc -HMPAO WBC studies were performed on all patients within the same week. Regions of interest were drawn over the abnormal bony sites and the contralateral normal sites, and the abnormal-to-normal uptake ratios (A/N ratios) were obtained for both studies. **Results:** All patients had abnormal findings on 3-phase bone scanning, whereas 17 (71%) had abnormal findings on ^{99m}Tc -HMPAO WBC studies, of which 15 were confirmed to be true-positive. In those 15 patients, the mean A/N ratios for ^{99m}Tc -MDP and ^{99m}Tc -HMPAO WBC were 3.0 ± 1.6 (range, 1.3–6.2) and 1.8 ± 0.3 (range, 1.4–2.2), respectively. In the other 9 patients, whose scan results were clinically confirmed to be true-negative, the mean A/N ratios for ^{99m}Tc -MDP and ^{99m}Tc -HMPAO WBC were 2.1 ± 1.2 and 1.2 ± 0.2 , respectively. In the group with a ^{99m}Tc -MDP A/N ratio greater than 2 ($n = 15$), 87% (13/15) had a high ^{99m}Tc -HMPAO WBC A/N ratio (>1.5), including 2 that were false-positive. In the remaining 2 patients, one with chronic osteomyelitis and the other with a recent hip prosthesis, ^{99m}Tc -HMPAO WBC ratios were normal. In the group with a bone A/N ratio of less than 2 ($n = 9$), only 4 patients (44%) were true-positive for acute osteomyelitis. **Conclusion:** ^{99m}Tc -MDP bone scanning alone, with an A/N ratio of more than 2, is useful in detecting osteomyelitis in violated bone except in the case of a recent hip prosthesis or chronic osteomyelitis.

Key Words: 3-phase bone scan; ^{99m}Tc -HMPAO WBC; osteomyelitis; quantitative measurements

J Nucl Med Technol 2007; 35:91–95

DOI: 10.2967/jnmt.106.035402

Clinical and laboratory tests such as complete blood counting, C-reactive protein, and erythrocyte sedimentation rate are considered nonspecific for the diagnosis of osteomyelitis, whereas cultures of the blood or bone tissue are essential for a precise diagnosis (1). However, cultures are invasive, may spread infection from overlying soft tissue to underlying bone, and may induce pathologic fractures. Imaging is needed to confirm the diagnosis early, because a delay in treatment reduces the chance of cure. Prolonged treatment with intravenous antibiotics for 4–6 wk cannot be given without an accurate diagnosis (2,3). The bone scan has an established role in detecting bone infection. Normal results on a bone scan rule out osteomyelitis (4). The classic findings of hyperemia, increased blood-pool activity, and increased focal bony uptake on delayed images on 3-phase bone imaging are sensitive and specific for the diagnosis of osteomyelitis in nonviolated bone (5,6). Violated bone hampers the detection of infection on the basis of these classic findings because increased bone turnover and, perhaps, hyperemia are already present. Therefore, despite high bone scan sensitivity, pathologic orthopedic (violated bone) cases have a lowered specificity for the detection of osteomyelitis (7). The sensitivity of 3-phase bone imaging has been reported to be between 70% and 100%, with an average of 92%, whereas the average specificity might be as low as 32% (8). Because labeled leukocytes do not accumulate at the site of increased bone turnover, the addition of ^{99m}Tc -hexamethylpropyleneamine oxime (HMPAO) white blood cell (WBC) imaging has been helpful in diagnosing bone infection in violated bones, such as after trauma, after surgery, and from diabetic foot infection (9–11). The

Received Aug. 3, 2006; revision accepted Feb. 21, 2007.
For correspondence or reprints contact: Nasser S. Ballani, PhD, Biomedical Sciences, Lebanese International University, Mouseitbeh St., Beirut, Lebanon.
E-mail: nasser.ballani@liu.edu.lb
COPYRIGHT © 2007 by the Society of Nuclear Medicine, Inc.

overall ^{99m}Tc -HMPAO WBC sensitivity and specificity are 88% and 91%, respectively, in osteomyelitis of previously violated bones (9,12–14). However, ^{99m}Tc -HMPAO WBC imaging is performed only after a positive finding on 3-phase bone imaging, because the latter is highly sensitive but significantly less expensive, making it more appropriate as a first-line screening procedure (3).

Previous attempts have been made to improve the specificity of 3-phase bone imaging. The use of 4 phases has been reported to improve accuracy in differentiating osteomyelitis from cellulitis by showing an increase in the ratio between the lesion and normal bone due both to longer uptake of ^{99m}Tc -methylene diphosphate (MDP) by infected than by healthy bone and to the reduction of background activity (15,16). Seldin et al. attempted to improve the sensitivity of 3-phase bone imaging in diabetic patients by classifying increased activity on the flow phase of the study (hyperemia) according to the time of its appearance relative to the surrounding soft tissues (17).

In addition to qualitatively assessing the ^{99m}Tc -MDP and ^{99m}Tc -HMPAO WBC studies, we have attempted to evaluate the clinical usefulness of measuring quantitative uptake in ^{99m}Tc -MDP and ^{99m}Tc -HMPAO WBC scanning in detecting osteomyelitis in peripheral bony lesions. In this study, our attempt was to investigate the usefulness of quantifying the degree of ^{99m}Tc -MDP uptake on bone scanning and to compare it with the degree of ^{99m}Tc -HMPAO uptake on WBC scanning, in patients with suspected osteomyelitis.

MATERIALS AND METHODS

This study was conducted between 2000 and 2003 at the Kuwait Center for Specialised Surgery. Twenty-four patients with violated bone (12 men and 12 women; age range, 25–72 y) were referred to the nuclear medicine department with a clinical suspicion of osteomyelitis. The patients underwent 3-phase ^{99m}Tc -MDP bone scanning first, followed by ^{99m}Tc -HMPAO WBC scanning. The studies were separated by at least 2 d but no more than 7 d. The underlying bone pathology included traumatic fracture ($n = 10$), knee prosthesis ($n = 5$), hip prosthesis ($n = 2$), diabetic foot ($n = 4$), and chronic osteomyelitis ($n = 3$). In both studies, the amount of intravenously injected ^{99m}Tc was about 740 MBq (~ 20 mCi), and images were acquired by a γ -camera with a high-resolution parallel-hole collimator using a matrix of 256×256 (pixel size, ~ 2 mm) on a 20% window at a 140-keV peak. Anterior images were obtained 3 h after ^{99m}Tc -MDP injection and 4 h after ^{99m}Tc -HMPAO leukocyte injection.

Three nuclear medicine consultants qualitatively evaluated the scintigraphic findings of both studies. The ^{99m}Tc -HMPAO-labeled WBC and ^{99m}Tc -MDP scans were considered to be consistent with osteomyelitis when the labeled WBC scan uptake was concordant in all instances with ^{99m}Tc -MDP bone uptake. ^{99m}Tc -HMPAO WBC uptake without concordant bone ^{99m}Tc -MDP activity was considered to indicate a soft-tissue infection. The results of the ^{99m}Tc -HMPAO WBC and ^{99m}Tc -MDP scans were compared with the following diagnostic criteria: A good response to antibiotic therapy and resolving radiologic findings were considered diagnostic of osteomyelitis; absence of bone infection was also confirmed by clinical and radiologic follow-up; and bone biopsy with culture and

sensitivity was performed whenever possible. When bone biopsy could not be performed, a clinical criterion based on follow-up evidence was adopted as follows: Empiric antibiotic therapy was started on the basis of a strong clinical suspicion and supportive evidence on ^{99m}Tc -MDP/HMPAO studies, and a subsequent good response to antibiotic therapy and resolving radiologic findings were considered to be diagnostic of osteomyelitis. In patients who were considered negative for bone infection (based on negative biopsy findings or negative ^{99m}Tc -MDP/HMPAO scan results), no antibiotic therapy was given and the absence of bone infection was confirmed by uneventful clinical and radiologic follow-up. The nuclear medicine physician asked for a bone marrow scan whenever altered bone marrow distribution was suspected—for example, in a diabetic foot.

Both the ^{99m}Tc -MDP bone scans and the ^{99m}Tc -HMPAO WBC scans were further analyzed by drawing equal rectangular regions of interest over the suspected abnormal and contralateral normal bony sites (mirrored regions of interest). The entire lesion was included in the rectangular region of interest. Mean counts per pixel in each region of interest were estimated. The mean uptake count ratio between abnormal and normal sites (A/N) in ^{99m}Tc -MDP bone and ^{99m}Tc -HMPAO WBC scans were obtained. A/N ratios were assessed by an unpaired 2-way Student *t* test applied to the ^{99m}Tc -MDP bone and ^{99m}Tc -HMPAO WBC scans using version 12.0 SPSS software (SPSS Inc.) for Windows (Microsoft).

RESULTS

Figure 1 shows 2 different patients. Although both had positive findings on ^{99m}Tc -MDP scanning, the first patient had negative findings on ^{99m}Tc -HMPAO scanning whereas the second had positive findings. All patients had abnormal 3-phase bone findings, whereas 17 (71%) had concordant

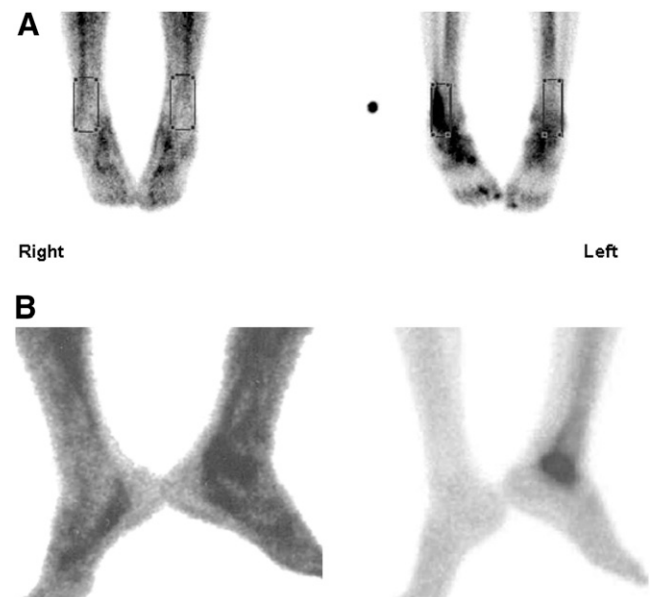


FIGURE 1. Anterior-view ^{99m}Tc -HMPAO WBC scans (left) and ^{99m}Tc -MDP bone scans (right). (A) Images of patient with negative ^{99m}Tc -HMPAO findings but positive ^{99m}Tc -MDP findings, showing regions of interest drawn on suspected site of abnormality and on contralateral normal site. (B) Patient with positive findings on both types of scans.

abnormal findings on ^{99m}Tc -HMPAO WBC scanning and therefore were considered to have osteomyelitis, which was confirmed on follow-up in 15 of 17 (Table 1). In the 15 true-positive osteomyelitis patients, the mean A/N ratios on ^{99m}Tc -MDP and ^{99m}Tc -HMPAO WBC scans were 3.0 ± 1.6 (range, 1.3–6.2) and 1.8 ± 0.3 (range, 1.4–2.2), respectively. In the remaining 9 patients, clinically confirmed negative, the mean A/N ratios for ^{99m}Tc -MDP and ^{99m}Tc -HMPAO WBC were 2.1 ± 1.2 and 1.2 ± 0.2 , respectively (Table 2). The derived ^{99m}Tc -HMPAO WBC mean A/N ratios were significantly different between patients who were positive and patients who were negative for osteomyelitis (Table 2).

We considered a mean A/N ratio of 2, or twice the normal uptake, to be significantly abnormal on ^{99m}Tc -MDP bone scanning and further analyzed our data accordingly (Table 3). Of the 15 patients with an A/N ratio of more than 2 (mean, 3.4 ± 1.3) on ^{99m}Tc -MDP bone scanning, 13 (87%) had a mean A/N ratio of more than 1.5 (mean, 1.8 ± 0.3) on ^{99m}Tc -HMPAO WBC scanning, of whom 2 were false-positive for osteomyelitis. The remaining 2 had ^{99m}Tc -HMPAO WBC A/N ratios of 1.2 (hip prosthesis) and 1.1 (chronic osteomyelitis) and were true-negative for acute osteomyelitis. Of the 9 pa-

TABLE 2
Quantitative Results for Both Studies in 24 Patients with Violated Peripheral Bones

Definitive diagnosis	<i>n</i>	^{99m}Tc -MDP A/N (mean \pm SD)	^{99m}Tc -HMPAO A/N (mean \pm SD)
Positive	15	3.0 ± 1.6	1.8 ± 0.3
Negative	9	2.1 ± 1.2	1.2 ± 0.2
<i>P</i> value		<0.2	<0.001

P value was derived using 2-way unpaired Student *t* test.

tients with ^{99m}Tc -MDP bone A/N ratios of less than 2 (mean, 1.4 ± 0.1), 4 (44%) were confirmed to have osteomyelitis, of whom 2 had an ^{99m}Tc -HMPAO WBC A/N ratio equal to or above 1.5 and the other 2 had a ^{99m}Tc -HMPAO WBC A/N ratio of 1.4 (Table 3).

We evaluated 10 patients with complicated fractures for acute osteomyelitis. Five were confirmed to have osteomyelitis, all having a ^{99m}Tc -HMPAO WBC A/N ratio of more than 1.5 and a ^{99m}Tc -MDP A/N ratio of more than 2. One

TABLE 1
Quantitative ^{99m}Tc -MDP and ^{99m}Tc -HMPAO WBC Scan Results in Violated Peripheral Bone with Their Definitive Diagnosis

Patient no.	Underlying pathology	^{99m}Tc -MDP A/N	^{99m}Tc -HMPAO A/N	Scan report	Diagnostic criteria	Antibiotic therapy	Definitive diagnosis
1	Fracture	1.3	1.1	Negative	Clinical	No	TN
2	Fracture	2.6	2.2	Positive	Bone biopsy	Yes	TP
3	Fracture	1.4	1.2	Negative	Clinical	No	TN
4	Fracture	2.7	1.6	Positive	Bone biopsy	No	FP
5	Fracture	4.1	1.9	Positive	Bone biopsy	Yes	TP
6	Fracture	2.4	1.5	Positive	Bone biopsy	Yes	TP
7	Fracture	1.3	1.2	Negative	Clinical	No	TN
8	Fracture	2.2	1.5	Positive	Clinical	Yes	TP
9	Fracture	2.9	1.8	Positive	Bone biopsy	Yes	TP
10	Fracture	1.3	1.4	Positive	Clinical	Yes	TP
11	Prosthesis	2.1	1.5	Positive	Bone biopsy	Yes	TP
12	Prosthesis	1.4	1.5	Positive	Bone biopsy	Yes	TP
13	Prosthesis	2.1	1.7	Positive	Clinical	No	FP
14	Prosthesis	1.3	1.4	Positive	Bone biopsy	Yes	TP
15	Prosthesis	1.6	2.1	Positive	Bone biopsy	Yes	TP
16	Prosthesis	2.0	2.1	Positive	Bone biopsy	Yes	TP
17	Prosthesis	4.8	1.2	Negative	Clinical	No	TN
18	Diabetic foot ulcers	6.2	2.1	Positive	Bone biopsy	Yes	TP
19	Diabetic foot ulcers	5.0	2.0	Positive	Bone biopsy	Yes	TP
20	Diabetic foot ulcers	4.4	2.1	Positive	Bone biopsy	Yes	TP
21	Diabetic foot ulcers	4.8	2.0	Positive	Bone biopsy	Yes	TP
22	Chronic osteomyelitis	2.9	1.1	Negative	Clinical	No	TN
23	Chronic osteomyelitis	1.3	1.0	Negative	Clinical	No	TN
24	Chronic osteomyelitis	1.3	1.1	Negative	Clinical	No	TN

Negative = ^{99m}Tc -MDP and ^{99m}Tc -HMPAO WBC scans reported negative for osteomyelitis; positive = ^{99m}Tc -MDP and ^{99m}Tc -HMPAO WBC scans reported positive for osteomyelitis; clinical = clinical follow-up shows good response to antibiotic therapy and resolving radiologic and clinical findings; absence of bone infection was also confirmed by uneventful clinical and radiologic follow up without antibiotic therapy.

Definitive diagnostic criterion was bone biopsy with culture and sensitivity. For bone scanning, sensitivity = 100% and specificity = 30%. For HMPAO WBC scanning, sensitivity = 100% and specificity = 78%.

TABLE 3

Quantitative Results for Both Studies in 15 and 9 Patients with a Mean ^{99m}Tc -MDP A/N Ratio of More Than 2.0 and Less Than 2.0, Respectively

MDP A/N ratio	n (24)	HMPAO A/N ratio	
		<1.5 (1.2 ± 0.1)	≥1.5 (1.8 ± 0.3)
≥2.0 (3.4 ± 1.3)	15	2/15 (13%)	13/15 (87%)
<2.0 (1.4 ± 0.1)	9	7/9 (78%)*	2/9 (22%)

*Two of 9 patients were true-positive for osteomyelitis.

patient was falsely reported to have osteomyelitis on the combined ^{99m}Tc -MDP/HMPAO WBC study. He had a ^{99m}Tc -HMPAO WBC A/N ratio of 1.6 and a ^{99m}Tc -MDP A/N ratio of 2.7 (Table 1).

Another 7 patients had either a hip prosthesis ($n = 2$) or a knee prosthesis ($n = 5$). Five were confirmed to have acute osteomyelitis, of whom 4 had a ^{99m}Tc -HMPAO WBC A/N ratio of at least 1.5 and a ^{99m}Tc -MDP A/N ratio of more than 2. Of the 2 patients with no definite evidence of acute osteomyelitis, one, reported as true-negative on ^{99m}Tc -HMPAO WBC scanning, had recently received a hip prosthesis and had a ^{99m}Tc -MDP A/N ratio of 4.8; the other, reported as false-positive on ^{99m}Tc -HMPAO WBC scanning (A/N ratio, 1.7) and having a ^{99m}Tc -MDP A/N ratio of 2.1, had inflammation on bone biopsy with a negative culture report.

Four patients with diabetic foot ulcers had high ^{99m}Tc -MDP bone uptake (A/N ratio range, 4.4–6.2). All had confirmed acute osteomyelitis and had a ^{99m}Tc -HMPAO WBC A/N ratio of at least 2.

Three patients with a past history of bone infection and with residual radiographic changes (labeled as chronic osteomyelitis) had true-negative ^{99m}Tc -HMPAO WBC findings. Two of these 3 had a ^{99m}Tc -MDP A/N ratio of less than 2, and 1 had a ^{99m}Tc -MDP A/N ratio of 2.9.

DISCUSSION

Since the advent of infection-specific radiopharmaceuticals, the standard approach in cases of suspected osteomyelitis has been to perform plain radiography followed by 3-phase bone scintigraphy using such infection-specific radiopharmaceuticals to increase the specificity of bone scan findings in cases of violated bone. MRI and CT are reserved for negative scintigraphic studies in cases with a high clinical suspicion of infection.

^{99m}Tc -HMPAO WBC scanning has been shown to be an accurate technique for the diagnosis of osteomyelitis in the setting of violated bone, with a sensitivity of 100% and a specificity of more than 95% (9). In a group of unselected patients appearing quite similar to our population, with violated bones and suspected osteomyelitis, Devillers et al. reported an overall sensitivity, specificity, and accuracy of 93%, 100%, and 96%, respectively, for ^{99m}Tc -HMPAO WBC scanning and 100%, 17%, and 53.3%, respectively,

for ^{99m}Tc -MDP bone scanning (18). In our study also, combined ^{99m}Tc -HMPAO/MDP imaging proved useful in diagnosing osteomyelitis. The specificity of ^{99m}Tc -MDP bone scanning improved from 30% to 78% on the addition of ^{99m}Tc -HMPAO WBC scanning. The quantification of abnormal uptake on both the bone scans and the WBC scans in the form of derived A/N ratios proved useful and revealed some interesting results. The mean bone A/N ratio in patients with no evidence of osteomyelitis was 2.1 ± 1.2 (Table 3). Of the 15 patients with a bone scan A/N ratio of more than 2, 13 patients had a ^{99m}Tc -HMPAO A/N ratio of more than 1.5, including 2 false-positive cases. The ^{99m}Tc -HMPAO findings were almost negative in the remaining 2 patients (A/N ratio, 1.2), of whom one had a past history of chronic osteomyelitis and the other had recently received a hip implant. Both patients turn out to have no osteomyelitis on long-term clinical follow-up. Such a cutoff value (2.0) would improve the ^{99m}Tc -MDP specificity from 29% to 87%. Falsely high bone uptake may thus be present in chronic osteomyelitis and recently received hip prostheses. Interestingly, relatively higher bone A/N ratios were observed in patients with diabetic foot ulcers (ranging from 4.4 to 6.2.), all of whom turned out to be true-positive for osteomyelitis, with ^{99m}Tc -HMPAO WBC A/N ratios of at least 2. A high bone uptake is expected in these patients because of underlying neuropathic bone changes (19–21). Previous studies with combined ^{99m}Tc -HMPAO/MDP imaging in diabetic foot ulcers prove to be useful in diagnosing osteomyelitis (18,22). Poirier et al. reported a sensitivity of 92.6% and a specificity of 97.6% for ^{99m}Tc -HMPAO/MDP scanning for the diagnosis of osteomyelitis in diabetic foot ulcers and concluded that neuroarthropathy did not affect the performance of this scan (23).

We evaluated 7 patients 6 mo to 3 y after prosthetic implantation. Five of the 7 were confirmed to have acute osteomyelitis, of whom 4 had a ^{99m}Tc -HMPAO A/N ratio of more than 1.5. These patients have shown variable bone uptake. Four had a ^{99m}Tc -MDP A/N ratio of more than 2, of whom one was reported falsely positive for osteomyelitis whereas the other, with a recent hip prosthesis, was correctly diagnosed on ^{99m}Tc -HMPAO WBC scanning to have no acute osteomyelitis although he had an ^{99m}Tc -MDP A/N ratio of 4.8. These results are consistent with the well-known fact that periprosthetic uptake patterns are variable during the first 12 mo after joint replacement, and accordingly, it appears that bone scanning is most useful in excluding infections when the findings are clearly negative (24,25). Therefore, the addition of ^{99m}Tc -HMPAO WBC scanning proved useful in detecting osteomyelitis (4/5 patients; A/N ratio, >1.5). Copping et al. found ^{99m}Tc -HMPAO WBC scanning to be useful for the evaluation of orthopedic implant infection after positive findings on 3-phase bone scanning (3). De Lima Ramos et al. reported a sensitivity, specificity, and accuracy of 72.7%, 78.2%, and 76.4%, respectively, for ^{99m}Tc -HMPAO WBC scanning for the localization of bone and joint infections (26). False-positive

^{99m}Tc-HMPAO WBC scans are possible in conditions such as periprosthetic granuloma, ossifying peri-arthritis, non-specific bone inflammation negative for bacterial growth, and physiologic uptake by cellular bone marrow. Munoz et al. stated that the addition of bone marrow scintigraphy with ^{99m}Tc-stannous colloid to the ^{99m}Tc-HMPAO WBC/MDP scan protocol improved the accuracy of the diagnosis of bone prosthesis infection and should be included in the diagnostic protocol for this disease (27). In our study, a quantitative ^{99m}Tc-HMPAO WBC A/N ratio of more than 1.5 correctly identified the presence of osteomyelitis in 4 of 5 patients. Therefore, our findings suggest that adding quantitation to the ^{99m}Tc-HMPAO WBC scan could be significantly valuable in detecting osteomyelitis in patients with prosthetic transplants.

Of 10 patients with complicated fractures, 5 were correctly identified as having osteomyelitis on ^{99m}Tc-MDP bone scanning (A/N ratio, >2), and all 5 had a ^{99m}Tc-HMPAO WBC A/N ratio of more than 1.5. One patient was falsely reported to have osteomyelitis on the combined ^{99m}Tc-MDP/HMPAO WBC study. This patient had no abnormal uptake at the fracture site on the ^{99m}Tc-HMPAO WBC scan but had an actual increase in tracer localization at a bony site distal to the fracture on both ^{99m}Tc-MDP and ^{99m}Tc-HMPAO WBC scans. The patient had an uneventful course with no antibiotic treatment. Three patients with chronic osteomyelitis were correctly diagnosed to have no acute osteomyelitis on ^{99m}Tc-HMPAO WBC scanning (A/N ratio, 1.1). Only one patient had ^{99m}Tc-MDP uptake of more than 2. Although the number of patients in this study was small, similar results have been reported by Krznaric et al., who found that ^{99m}Tc-HMPAO WBC scanning had an overall sensitivity, specificity, and accuracy of 94%, 91%, and 92%, respectively, for the diagnosis of chronic osteomyelitis (28).

CONCLUSION

This study found a high correlation between qualitative and quantitative diagnosis in suspected cases of violated bone infection using combined ^{99m}Tc-MDP/HMPAO WBC scanning. Uptake measurements were easy to perform. ^{99m}Tc-MDP bone scanning alone, with an A/N ratio of more than 2, was useful in detecting osteomyelitis in violated bone, if one kept in mind the possibility of variable bone uptake in certain settings such as prosthetic implants and chronic osteomyelitis. These preliminary findings suggest that an uptake of more than 1.5 on ^{99m}Tc-HMPAO WBC scanning can be of value in detecting osteomyelitis.

REFERENCES

1. Waldvogel FA, Medoff G, Swartz MN. Osteomyelitis: a review of clinical features, therapeutic considerations and unusual aspects. 3. Osteomyelitis associated with vascular insufficiency. *N Engl J Med.* 1970;282:316–322.
2. Lew DP, Waldvogel FA. Osteomyelitis. *N Engl J Med.* 1997;336:999–1007.

3. Copping C, Dalgliesh SM, Dudley NJ, et al. The role of ^{99m}Tc-HMPAO white cell imaging in suspected orthopaedic infection. *Br J Radiol.* 1992;65:309–312.
4. Ang ES, Sundram FX, Goh AS, Aw SE. ^{99m}Tc-polyclonal IgG and ^{99m}Tc nanocolloid scans in orthopaedics: a comparison with conventional bone scan. *Nucl Med Commun.* 1993;14:419–432.
5. Elgazzar AH, Abdel-Dayem HM, Clark J, Maxon HR. Multimodality imaging of osteomyelitis. *Eur J Nucl Med.* 1995;22:1043–1063.
6. Schauwecker DS. The scintigraphic diagnosis of osteomyelitis. *AJR.* 1992;158:9–18.
7. Peters AM. The utility of (^{99m}Tc) HMPAO-leukocytes for imaging infection. *Semin Nucl Med.* 1994;24:110–127.
8. Elgazzar AH, Abdel-Dayem HM. Imaging skeletal infections: evolving considerations. In: Freeman LM, ed. *Nuclear Medicine Annual.* Philadelphia, PA: Lippincott Williams & Wilkins; 1999:157–185.
9. Maugeudre D, Poirier JY. Nuclear medicine in the diagnosis of diabetic foot osteomyelitis. *Diabetes Metab.* 2001;27:396–400.
10. Seabold JE, Nepola JV. Imaging techniques for evaluation of postoperative orthopedic infections. *Q J Nucl Med.* 1999;43:21–28.
11. Papos M, Barat F, Narai G, Dillmann J, Lang J, Csernay L. Tc-^{99m} HMPAO leukocyte and Tc-^{99m} nanocolloid scintigraphy in posttraumatic bone infection. *Clin Nucl Med.* 1998;23:423–428.
12. Ruther W, Hotze A, Moller F, Bockisch A, Heitzmann P, Biersack HJ. Diagnosis of bone and joint infection by leucocyte scintigraphy: a comparative study with ^{99m}TcHMPAO-labelled leucocytes, ^{99m}Tc-labelled antigranulocyte antibodies and ^{99m}Tc-labelled nanocolloid. *Arch Orthop Trauma Surg.* 1990;110:26–32.
13. Verlooy H, Mortelmans L, Verbruggen A, Stuyck J, Broogaerts M, De Roo M. Tc-^{99m} HMPAO labeled leukocyte scanning for detection of infection in orthopedic surgery. *Prog Clin Biol Res.* 1990;355:181–187.
14. Vorne M, Lantto T, Paakinen S, Salos S, Soini I. Clinical comparison of Tc-^{99m} HMPAO labeled leukocytes and Tc-^{99m} nanocolloid in the detection of inflammation. *Acta Radiol.* 1989;30:633–637.
15. Alazraki N, Dries D, Datz F, Lawrence P, Greenberg E, Taylor A Jr. Value of a 24 hour image (four phase bone scan) in assessing osteomyelitis in patients with peripheral vascular disease. *J Nucl Med.* 1985;26:711–717.
16. Israel O, Gips S, Jerushalmi J, Frenkel A, Front D. Osteomyelitis and soft tissue infection: differential diagnosis with 24 hour/4 hour ratio of Tc-^{99m} MDP uptake. *Radiology.* 1987;163:725–726.
17. Seldin DW, Heiken JP, Feldman F, Alderson PO. Effect of soft-tissue pathology on detection of pedal osteomyelitis in diabetics. *J Nucl Med.* 1985;26:988–993.
18. Devillers A, Garin E, Polard JL, et al. Comparison of Tc-^{99m}-labelled antileukocyte fragment Fab' and Tc-^{99m}-HMPAO leukocyte scintigraphy in the diagnosis of bone and joint infections: a prospective study. *Nucl Med Commun.* 2000;21:747–753.
19. Friedman SA, Rakow RD. Osseous lesions of the foot in diabetic neuropathy. *Diabetes.* 1971;20:302–307.
20. Schwarz GS, Berenyi MR, Siegel MW. Atrophic arthropathy and diabetic neuritis. *AJR.* 1969;106:523–529.
21. Fox IM, Zeiger L. Tc-^{99m}-HMPAO leukocyte scintigraphy for the diagnosis of osteomyelitis in diabetic foot infections. *J Foot Ankle Surg.* 1993;32:591–594.
22. Harvey J, Cohen MM. Technetium-^{99m}-labeled leukocytes in diagnosing diabetic osteomyelitis in the foot. *J Foot Ankle Surg.* 1997;36:209–214.
23. Poirier JY, Garin E, Derrien C, et al. Diagnosis of osteomyelitis in the diabetic foot with a ^{99m}Tc-HMPAO leukocyte scintigraphy combined with a ^{99m}Tc-MDP bone scintigraphy. *Diabetes Metab.* 2002;28:485–490.
24. Utz JA, Lull RJ, Galvin EG. Asymptomatic total hip prosthesis: natural history determined using Tc-^{99m} MDP bone scans. *Radiology.* 1986;161:509–512.
25. Rosenthal L. Hip and knee prostheses: evaluation of the natural history of periprosthetic bone changes. *Semin Nucl Med.* 1997;27:346–354.
26. De Lima Ramos PA, Martin-Comin J, Bajen MT, et al. Simultaneous administration of ^{99m}Tc-HMPAO-labelled autologous leukocytes and ¹¹¹In-labelled non-specific polyclonal human immunoglobulin G in bone and joint infections. *Nucl Med Commun.* 1996;17:749–757.
27. Munoz A, Ricart Y, Hernandez Hermoso J, et al. Radionuclide scan with Tc-^{99m}-tin colloid in the evaluation of orthopedic implant infections. *Rev Esp Med Nucl.* 1998;17:152–157.
28. Krznaric E, Roo MD, Verbruggen A, Stuyck J, Mortelmans L. Chronic osteomyelitis: diagnosis with technetium-^{99m}-d, l-hexamethylpropylene amine oxime labelled leucocytes. *Eur J Nucl Med.* 1996;23:792–797.