

# Efficacy of Administering Simultaneous Oral Perchlorate and Intravenous $^{99m}\text{TcO}_4^-$ for Brain Scanning

Mary E. Maxwell and Bonnie J. Baggenstoss

St. Paul-Ramsey Hospital and Medical Center, St. Paul, Minnesota

Brain scans were performed using the following methods: (A) oral administration of perchlorate at least 30 min before i.v. injection of  $^{99m}\text{Tc}$ -pertechnetate ( $^{99m}\text{TcO}_4^-$ ) and (B) simultaneous administration of oral perchlorate and i.v.  $^{99m}\text{TcO}_4^-$ . The scans were retrospectively reviewed for choroid plexus uptake of technetium and scan quality. The simultaneous administration of oral perchlorate and i.v.  $^{99m}\text{TcO}_4^-$  is an effective method of performing brain scans and should replace outdated protocols requiring treatment with perchlorate before i.v. administration of pertechnetate.

Most nuclear medicine laboratories use a brain scan protocol that requires the administration of a perchlorate treating agent, either sodium or potassium, before the i.v. administration of  $^{99m}\text{TcO}_4^-$ . The pre-treatment plan requires an expenditure of extra time and effort for both technologist and patient. The primary purpose of this study was to determine if oral blocking agents administered simultaneously with i.v.  $^{99m}\text{TcO}_4^-$  would effectively block the choroid plexus.

## Materials and Methods

Brain scans performed on 2,938 patients at St. Paul-Ramsey Hospital were retrospectively reviewed to assess  $^{99m}\text{TcO}_4^-$  uptake in the choroid plexus. A perchlorate treatment method was used on 2,791 of these patients. The remaining 147 brain scans were performed without any perchlorate treatment because of the patients' inability to ingest oral medications. Twenty-three of the patients received  $^{99m}\text{Tc}$ -DTPA, which does not require treatment with perchlorate (1).

The choroid plexus blocking agents used were either 250–500 mg potassium perchlorate ( $\text{KClO}_4$ ) in capsule form or 500 mg sodium perchlorate ( $\text{NaClO}_4$ ) in a cherry syrup solution made in the hospital pharmacy and consisting of the following: sodium perchlorate, 50 gm; methyl paraben, 2 gm; propyl paraben, 0.2 gm; ethyl alcohol USP, 8.3 ml; distilled water, 500 ml; and cherry syrup added to bring the total solution to 1,000 ml.

TABLE 1. Methods of Perchlorate Administration

Group	Method	Number of studies
1	Treat with perchlorate at least 30 min before i.v. injection of $^{99m}\text{TcO}_4^-$	1,558
2	Simultaneous administration of oral perchlorate and i.v. $^{99m}\text{TcO}_4^-$	1,233
3	No perchlorate given	147
	Total	2,938

The syrup was prepared by (A) dissolving the sodium perchlorate in distilled water, (B) dissolving the parabens in ethyl alcohol, and (C) adding the alcohol/paraben solution to the aqueous sodium perchlorate and bringing the combination to the appropriate volume with cherry syrup. The final solution should be refrigerated to insure stability and increased palatability.

The brain scans were arranged into three groups according to the method of perchlorate treatment (Table 1). The scans were performed on either a rectilinear scanner or a scintillation camera at 45–120 min after the injection of  $^{99m}\text{TcO}_4^-$ .

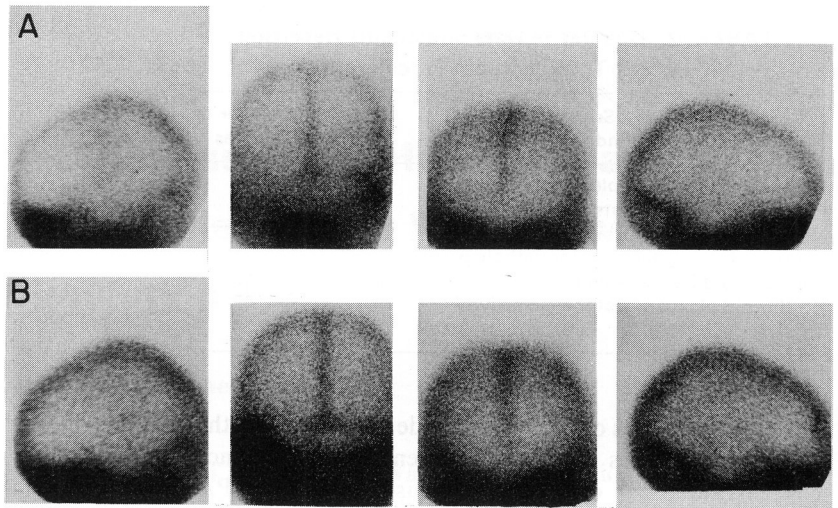
All of the 2,938 scans were subjectively evaluated to ascertain the presence or absence of choroid plexus activity and overall scan quality.

## Results

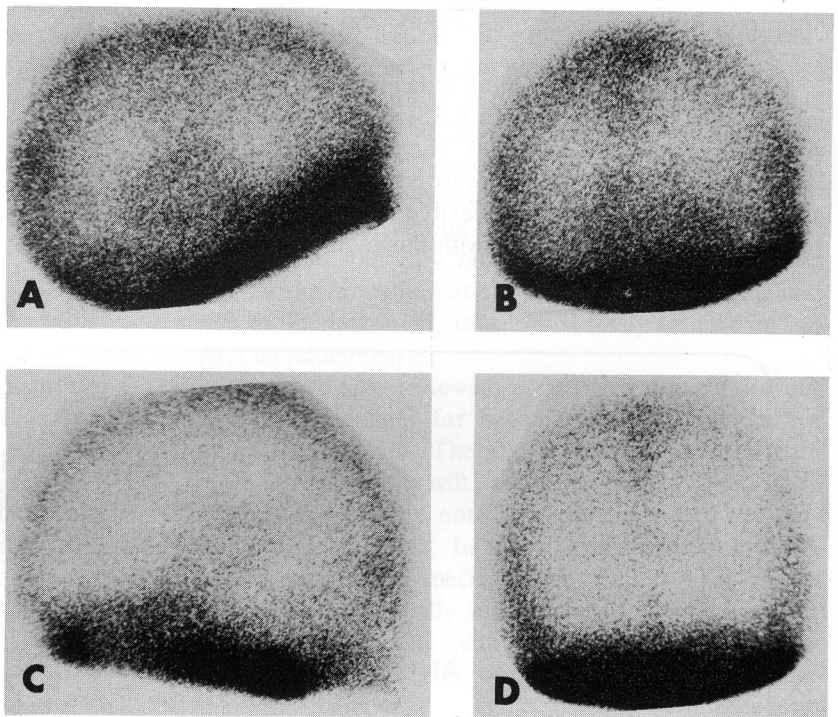
Brain scans performed after the simultaneous administration of oral  $\text{ClO}_4^-$  and i.v.  $^{99m}\text{TcO}_4^-$  were comparable to scans performed using a  $\text{ClO}_4^-$  pretreatment before administering the i.v.  $^{99m}\text{TcO}_4^-$  (Fig. 1). There was no evidence of pertechnetate uptake in the choroid plexus on any of the studies reviewed in the perchlorate-treated series.

When no oral blocking agent was used (147 scans),

For reprints contact: Mary E. Maxwell, Div. of Nuclear Medicine, St. Paul-Ramsey Hospital and Medical Center, St. Paul, Minn. 55101.



**FIG. 1.** Brain scans of same patient demonstrate comparable overall quality and no evidence of choroid plexus uptake. (A) Simultaneous oral perchlorate and i.v.  $^{99m}\text{TcO}_4^-$  method and (B) 30-min pretreatment with perchlorate before administration of i.v.  $^{99m}\text{Tc}$ .



**FIG. 2.** Brain scans demonstrate increased area of activity in choroid plexus due to patient's inability to ingest oral perchlorate. (A) Right lateral, (B) posterior, (C) left lateral, and (D) anterior views.

62% (124) demonstrated increased activity in the region of the choroid plexus (Fig. 2).

### Discussion

This study has demonstrated that oral perchlorate and i.v.  $^{99m}\text{TcO}_4^-$  can be administered simultaneously without compromising scan quality. The ability of the perchlorate ion to effectively enhance brain scan images is well documented but not well understood (2-5). Results of this study support the findings of Harper, et al (2) who did a comparison of concentration ratios of  $^{99m}\text{TcO}_4^-$  following i.v. injection in dogs. Their study consisted of a control group that received only intravenously injected  $^{99m}\text{TcO}_4^-$ , a group that received a  $^{99m}\text{TcO}_4^-/\text{NaClO}_4$  solution intravenously, and a group

that received oral  $\text{KClO}_4$  before the intravenous  $^{99m}\text{TcO}_4^-$ . Qualitative and quantitative analyses of their work showed that the simultaneous administration method was equally as effective as the perchlorate pretreatment method, and that, if indicated for human use, the simultaneous method could effectively eliminate the pretreatment methods currently used.

Some observers have found that without perchlorate blockage, uptake of  $^{99m}\text{TcO}_4^-$  in the choroid plexus occurred in only 1-10% of the population (6). This study revealed a 62% incidence of choroid plexus uptake of  $^{99m}\text{TcO}_4^-$  when perchlorate was not administered (Table 2).

Technetium-99m-DTPA may be used as an alternate radiopharmaceutical when the patient cannot ingest perchlorate. This radiopharmaceutical combines the

**TABLE 2. Qualitative Data on Patients Receiving i.v.  $^{99m}\text{TcO}_4^-$  without Perchlorate**

Scan findings	Number of studies
Uptake in the choroid plexus region only	33
Pathology identified outside choroid plexus region as well as choroid plexus activity	31
Choroid plexus uptake and/or pathology in the choroid plexus region	13
No choroid plexus or pathologic activity	47
Total	124

physical properties of the radionuclide  $^{99m}\text{TcO}_4^-$  and the biologic properties of chelating agents, which do not concentrate in any organs (1). The use of  $^{99m}\text{Tc}$ -DTPA in brain scanning eliminates a major source of error in interpretation in the choroid plexus region on brain scans.

Experience at this hospital indicated that overall laboratory efficiency was improved with the use of the simultaneous method described. The technologist's and the patient's time was utilized more efficiently. The daily schedule of studies was more flexible due to the shorter total procedure time involved with this method, and the

waiting period for outpatients was reduced by a factor of 2.

#### Acknowledgment

We wish to thank Robert R. McClelland for his help with the preparation of this manuscript.

#### References

1. Hauser W, Atkins HL, Nelson KG, et al: Technetium-99m DTPA: A new radiopharmaceutical for brain and kidney scanning. *Radiology* 94:679-684, 1970
2. Harper AG, Friedman BI, Avis KE, et al: Perchlorate blocking of  $^{99m}\text{TcO}_4^-$  uptake by simultaneous intravenous injection in dogs. *J Nucl Med* 13:363-366, 1972
3. Hirsch JI, Sharpe AR, Garnett W: The role of potassium perchlorate in 99m technetium brain scanning. *Drug Intelligence and Clinical Pharmacy* 5:252-257, 1971
4. Oldendorf WH, Sisson WN, Iisaka Y: Compartmental redistribution of  $^{99m}\text{Tc}$ -pertechnetate in the presence of perchlorate ion and its relation to plasma protein binding. *J Nucl Med* 11:85-88, 1970
5. Buttfield IH, Wrench JC, Adishesan N, et al: Intravenous perchlorate in brain scanning: Effects on choroid plexus and lesion visibility. *J Nucl Med* 14:543-545, 1973
6. Maynard CD: *Clinical Nuclear Medicine*. Philadelphia, Lea & Febiger, 1969, p 163