

Visualization in the Ipsilateral Lymph Nodes Secondary to Extravasation of a Bone-Imaging Agent in the Left Hand: A Case Report

Wei-Jen Shih, Judy Collins, and Vickie Kiefer

Nuclear Medicine Service, Lexington VA Medical Center, Lexington; and Section of Nuclear Medicine, Department of Diagnostic Radiology, University of Kentucky Medical Center, Lexington, Kentucky

Axillary or elbow lymph node visualization after subcutaneous infiltration of the bone-imaging agent on a routine bone scintigraphy has been reported. The prostate cancer patient in this case report underwent bone scintigraphy; in 3-h bone images, the lymph nodes in the wrist, elbow, and axillary regions were simultaneously visualized. This was caused by extravasation of the intravenous injection of bone-imaging agent in the dorsal part of the patient's hand.

Key Words: bone scintigraphy; lymph nodes; extravasation; bone-imaging agent

J Nucl Med Technol 2001; 29:154–155

A 69-y-old man with prostate cancer was referred for bone scintigraphy because of an increasing serum prostate-specific antigen level. A total-body image was acquired 3 h after intravenous injection of 762.2 MBq (20.6 mCi) ^{99m}Tc -HMDP. This image showed a large area of intense uptake in the dorsal portion of the left hand corresponding to the area of injection and infiltration of the radiopharmaceutical. A small area of intense uptake was seen in the left wrist, an area of substantially less activity was seen in the elbow, and an area of faint uptake was seen in the left axilla (Fig. 1). Multiple anterior, posterior, and left posterior oblique images of the chest and forearm showed areas of radiopharmaceutical uptake that incrementally decreased in size and intensity proceeding from the wrist and through the elbow and axilla (Fig. 2).

DISCUSSION

Incidental axillary or elbow lymph node visualization after subcutaneous infiltration of the bone-imaging agent

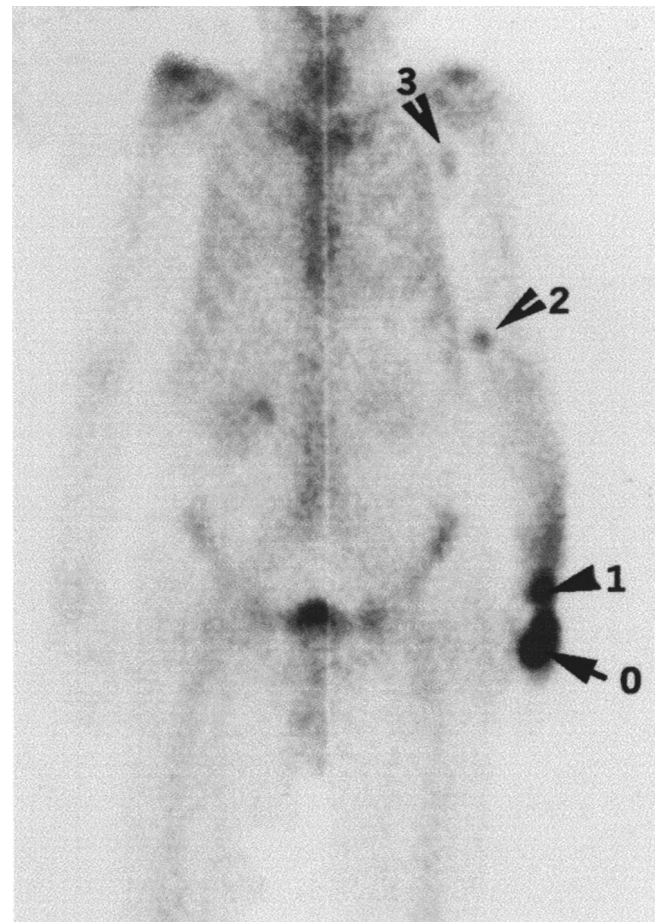


FIGURE 1. ^{99m}Tc -HMDP scan shows large area of intense uptake in dorsal portion of left hand (0), a relatively smaller area of intense uptake in left wrist (1), area of substantial decrease in radioactivity in elbow (2), and area of rather faint radioactivity in left axilla (3).

into the antecubital or wrist region has been reported (1–5). Visualization of lymph nodes in the elbow region resulting from the extravasation of bone-imaging agent in the wrist area has also been described (6). Our patient's injection site for the

For correspondence or reprints contact: Dr. Wei-Jen Shih, Nuclear Medicine Service, Lexington VA Medical Center, Lexington, KY 40511; Phone: 849-381-5928; Fax: 849-381-5934.

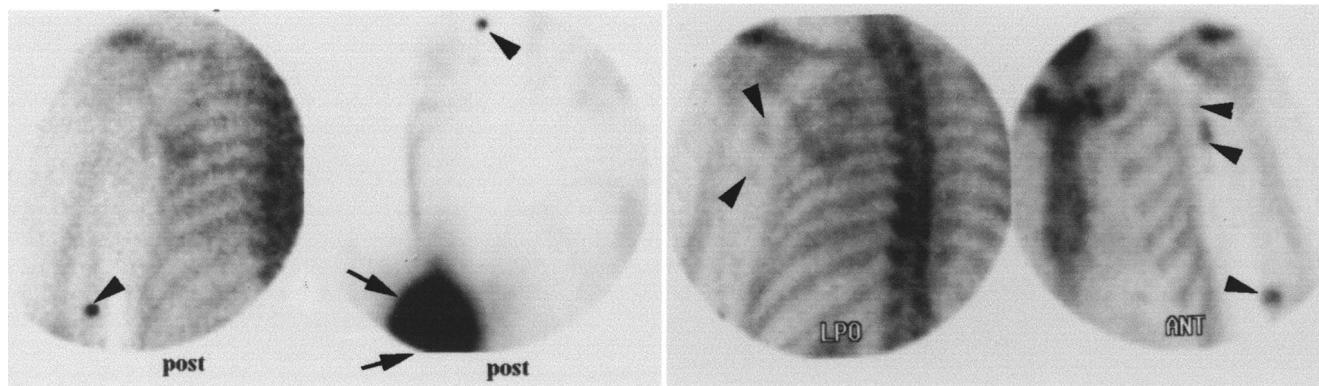


FIGURE 2. Multiple posterior (first 2 images from left), left posterior oblique (LPO, second image from right), and anterior (far right) images of chest and forearm show lymph nodes in elbow and axilla (arrowhead) and left wrist (arrow). Lymphatic channel (2 arrowheads) is also faintly visualized in anterior image.

bone-imaging agent was located on the distal dorsal area of the left hand, near the dorsal portion of the little and ring fingers. As per routine imaging, the bone scintigraphy was acquired 3 h after radiopharmaceutical injection. The extravasation appeared to be a substantially large amount of the total injected dose. This was shown by the intense uptake in the large area in the dorsal aspect of the left hand even 3 h after administration. Also note that the time required to acquire the total-body image (Fig. 1) and spot images (Fig. 2) was unusually prolonged. Over 3 h, gradual transportation of bone-imaging agent in the cephalic direction occurred, resulting in an incremental decrease in radioactive uptake in the lymph nodes in the distal to proximal direction.

REFERENCES

1. Ongseng F, Goldfarb CR, Finestone H. Axillary lymph node uptake of ^{99m}Tc MDP. *J Nucl Med.* 1995;36:1797-1799.
2. Chatterton BE, Vannitamby M, Cook DJ. Lymph node visualisation: an unusual artifact in the ^{99m}Tc pyrophosphate bone scan. *Eur J Nucl Med.* 1980;5:187-188.
3. Penney HF, Styles CB. Fortuitous lymph node visualization after interstitial injection of ^{99m}Tc -MDP. *Clin Nucl Med.* 1982;7:84-85.
4. Wallis JW, Fisher S, Wahl RL. ^{99m}Tc MDP uptake by lymph nodes following tracer infiltration: clinical and laboratory evaluation. *Nucl Med Commun.* 1987;8:357-363.
5. Dogan AS, Rezaei K. Incidental lymph node visualization on bone scan due to subcutaneous infiltration of ^{99m}Tc MDP. A potential for false-positive interpretation. *Clin Nucl Med.* 1993;18:208-209.
6. Shih WJ, Wierzbinski B, Magoun S. Lymph node visualization in the elbow region. *J Nucl Med.* 1996;37:1913.