
The Effect of Gadolinium Contrast Media on Radioiodine Uptake by the Thyroid Gland

Carl R. Christensen, Jerry V. Glowniak, Paul H. Brown and Kathryn A. Morton

Salt Lake Regional Medical Center, Salt Lake City, Utah; Department of Radiology, Wayne State University, Detroit, Michigan; Departments of Radiology and Clinical Engineering, Oregon Health Sciences University, Portland, Oregon; Imaging Service and Veterans Administration Medical Center, Portland, Oregon

Objective: Patients with thyroid cancer may require detailed anatomic imaging before ^{131}I therapy. Imaging by contrast-enhanced CT is contraindicated because it may result in saturation of tissues with iodine, decreasing the avidity of thyroid or thyroid cancer cells to subsequent radioiodine for extended intervals. Gadolinium-enhanced MRI offers an alternative to CT for detailed anatomic imaging. However, it is not known whether gadolinium contrast affects uptake of iodine by the thyroid gland since lanthanides affect ion transport in a variety of ways. The objective of this project was to determine whether the gadolinium MRI contrast injection alters thyroid uptake of radioiodine.

Methods: Radioiodine uptake by the thyroid gland was measured at 6 h and 24 h after the oral administration of 100 μCi ^{123}I -Na-I. Three to seven days later, a standard dose (20 mL) of Magnevist (gadolinium DTPA) was administered intravenously. Another capsule of 100 μCi ^{123}I Na-I immediately was given orally, and 6-h and 24-h radioiodine uptake by the thyroid gland was again measured and compared to baseline values.

Results: There was no statistically significant difference in uptake of radioiodine uptake by the thyroid gland between baseline values and those acquired immediately after the administration of Magnevist.

Conclusion: Contrast-enhanced MRI may be safely performed before contemplated determinations of thyroid uptake of radioiodine, ^{131}I therapy for hyperthyroidism, and postsurgical ^{131}I imaging and therapy for well-differentiated thyroid cancer.

Key Words: radioiodine uptake; thyroid; gadolinium contrast

J Nucl Med Technol 2000; 28:41–44

Well-differentiated thyroid carcinoma can be highly treatable, with long-term survival rates well in excess of 90%. Prognosis depends on patient age, gender, histology, stage of disease, and

appropriate surgical and medical management (1). The classic therapeutic triad for managing well-differentiated thyroid cancer consists of surgical removal of the thyroid, ablation of residual thyroid tissue with ^{131}I , and subsequent long-term suppression of TSH levels with exogenous thyroxine.

Patients with well-differentiated thyroid cancer often require detailed anatomic imaging for surgery planning, assessment of recurrence, and definition of the spatial relationship of tumor-to-critical structures. Imaging may be required in the weeks before contemplated ^{131}I therapy. Imaging by contrast-enhanced CT is contraindicated in these situations because it may result in saturation of tissues with iodine, thereby decreasing the avidity of thyroid or thyroid cancer cells to diagnostic or therapeutic radioiodine for extended intervals (2,3).

Gadolinium-enhanced MRI offers an excellent alternative to contrast-enhanced CT for detailed anatomic imaging in the neck. It is particularly useful in evaluating the postsurgical neck. However, lanthanides, such as gadolinium, are known to alter the cellular transport of many other ions in a variety of ways (4). The possibility exists that gadolinium contrast also could compromise uptake of iodine by thyroid tissue. The objective of this project was to determine whether the gadolinium contrast medium alters the uptake of radioiodine by the thyroid gland.

METHODS AND MATERIALS

Subjects and Screening Parameters

All examinations were performed with signed informed-consent by the subjects. Study design and consent forms were approved by the Human Use Subcommittee of the hospital Investigational Review Board. The subjects were 10 healthy adult male volunteers, ranging in age from 23–58 y. Thyroid function in all was normal, established within 1 wk before the procedures by serum TSH and free T4 levels. A careful history precluded the administration of iodinated contrast media within 3 mo. No medications or dietary supplements that are known to alter thyroid function were taken within the month before the experimental procedures (2).

For correspondence or reprints contact: Kathryn A. Morton, MD, Chief, Imaging Service, VA Medical Center, PO Box 1034, Mail Code P2-Imag, Portland, OR 97207; Phone: 503-273-5104; E-mail: morton.kathryn@portland.va.gov.

Protocol

Baseline measurements of 6 h and 24 h uptake of ^{123}I by the thyroid gland were obtained. Three to seven days later, subjects intravenously received a standard adult dose of 20 mL Magnevist (gadolinium DTPA, Berlex Laboratories, Inc., Wayne, NJ). Immediately (within 5 min) after administration of Magnevist, subjects received a second dose of ^{123}I . Uptake of radioiodine by the thyroid gland was again measured at 6 h and 24 h and compared to the baseline values.

Radioiodine Uptake

Using a thyroid uptake probe (Atom Lab 950 Medical Spectrometer; Biodex Medical, Shirley, NY), radioiodine uptake in the thyroid gland was measured at 6 and 24 h according to guidelines published by the Society of Nuclear Medicine (5). For each determination of thyroid radioiodine uptake, 100 μCi ^{123}I Na-I was given orally in capsule form to subjects fasted, except for water, for at least 6 h. Before administration to the subject, the capsule was placed in a neck phantom as a standard for subsequent calculations.

Statistics

Comparisons between baseline and postgadolinium (values obtained after gadolinium contrast administration) were compared by a paired t test, with 95% confidence intervals required for significance.

RESULTS

Table 1 and Figures 1 and 2 illustrate the results of this study. All 6-h and 24-h uptake measurements were accomplished in 9 patients. In 1 patient, the baseline 6-h value was not obtained. There was no significant difference in uptake by the thyroid gland between baseline values and those acquired after administering the gadolinium-DTPA contrast medium (postgadolinium) at either 6 h ($P = 0.37$) or 24 h ($P = 0.4$). For the 6-h uptake values, the range of differences between baseline and postgadolinium was -4.3% – 6.5% (mean difference 0.99%). For the

TABLE 1
Thyroid Uptake of Iodine-123 at Baseline and After Gadolinium Contrast Media

Subject	% Thyroid uptake of radioiodine			
	Baseline 6 h	Baseline 24 h	Post-Gd 6 h	Post-Gd 24 h
1	6.6	16.3	10.5	17.3
2	14.7	28.6	16.0	27.1
3	8.0	19.4	5.6	20.1
4	9.2	24.1	9.6	20.5
5	10.5	19.8	6.2	12.6
6	8.6	14.1	10.2	13.8
7	6.2	17.1	12.7	19.0
8	—	28.8	12.6	28.7
9	11.4	18.2	12.6	18.9
10	8.6	19.4	9.3	20.2
Mean	9.31	20.58	10.53	19.82
SEM	0.87	1.58	0.99	1.59

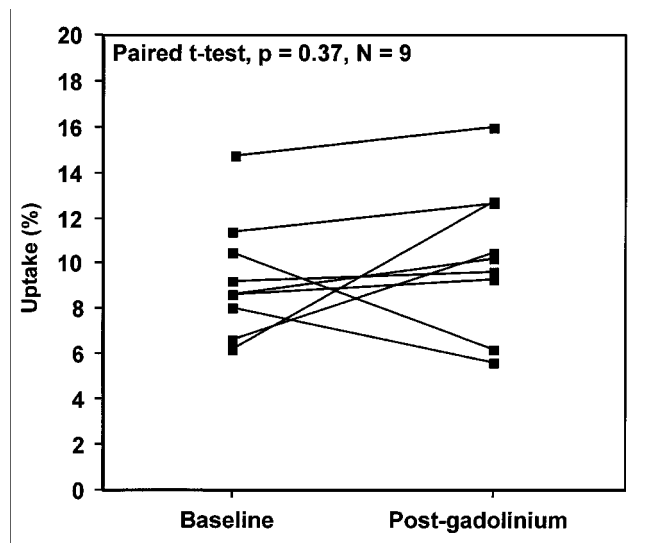


FIGURE 1. Uptake of ^{123}I by the thyroid gland was measured in 9 patients 6 h after the oral administration of 100 μCi ^{123}I -NaI. The baseline value for radioiodine uptake was compared with that obtained 3–7 d later, after the intravenous administration of 20 mL gadolinium contrast media (post-gadolinium).

24-h values, the range of differences was 0.1%–7.2% (mean difference -0.76%). These mean differences are well within the coefficient of variation in the measurement of thyroid uptake in the same patient by different technologists in our nuclear medicine service (previously established by our lab in conjunction with quality control activities).

DISCUSSION

Uptake of iodine by the thyroid gland occurs by a Na-I co-transporter that concentrates iodine against an electrochemical gradient. The co-transporter is an energy-dependent, carrier-mediated mechanism driven by the Na^+ gradients established

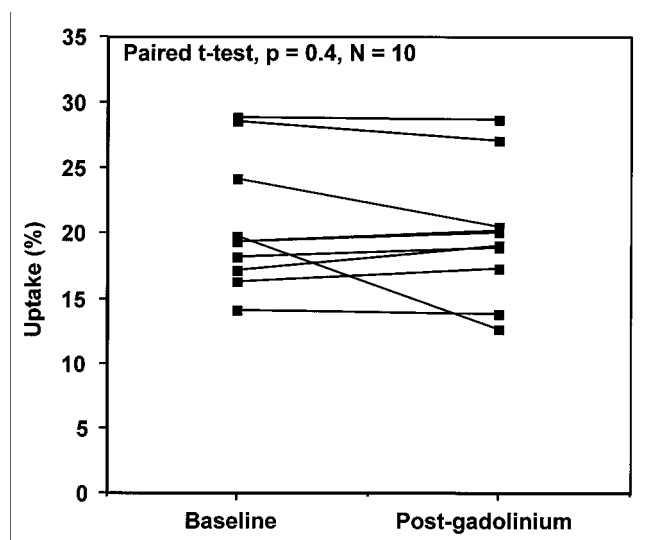


FIGURE 2. Uptake of ^{123}I by the thyroid gland was performed in 10 patients 24 h after the oral administration of 100 μCi ^{123}I -NaI. The baseline value for radioiodine uptake was compared with that obtained 3–7 d later, after the intravenous administration of 20 mL gadolinium contrast media (post-gadolinium).

by the Na⁺/K⁺ ATPase pump (6,7). The gene for the co-transporter has only recently been cloned (8). The complex factors that drive expression of the gene and modulate activity of the co-transporter are not yet fully defined (7).

Iodinated contrast media of all types (parenteral ionic and nonionic, oral and intracavitary) are contaminated by variable amounts of free (unbound) iodine (9). The iodinated compounds in contrast media also can be further metabolized in vivo to release additional free iodine. All forms of iodinated contrast media, as well as superficially-applied iodine-containing compounds such as Betadine, can increase the total body pool of iodine. This can result in accumulation of excess iodine by the thyroid gland, which alters thyroid function and significantly decreases uptake of radioiodine by the thyroid for extended intervals of 2–4 wk or longer (2,3,10–14). The primary mechanism for this reduction in uptake is the dilution of the radioiodine by the endogenous unlabeled iodine pool (Wolff-Chaikoff effect).

The kinetics of uptake and clearance of iodine by well-differentiated thyroid cancer are not known. Conceivably, the effects of iodinated contrast on uptake of radioiodine could be of longer duration in thyroid cancer cells than in the normal thyroid. It cannot be assumed, in patients under TSH-suppressive therapy, that it is safe to use iodinated contrast without subsequently diminishing the efficacy of further therapy with ¹³¹I. Thyrostatic treatment does not completely block the effect of iodinated contrast on the thyroid gland in euthyroid patients with thyroid autonomy (15). Cultured thyroid cells also are known to continue to accumulate iodine even in the absence of TSH (8). The overall best policy in imaging patients with suspected or proven thyroid cancer (before or after surgery or radioiodine therapy) is to avoid the use of iodinated contrast. It also may be advisable to extend this policy to patients with new extrathyroidal neck or mediastinal masses who are either nonsmokers or who are under the age of 50 y. In these patients, thyroid cancer is a distinct possibility.

Based on metal ion speciation calculations of the behavior of Gd-DTPA in plasma, and the observation that excretion of Gd-DTPA is only 91% of that observed for ^{99m}Tc DTPA, it is likely that gadolinium contrast media are contaminated by, or release in vivo, small amounts of free gadolinium (16,17). Gadolinium and other lanthanides are known to interact with many cellular components, even in small concentrations (18). They also modify, by a variety of selective and nonselective ways, the activity of several ion transport channels. These include mechano-gated and sodium channel currents (4,19), calcium channels of the L and T types (20,21), K⁺ channels (22,23), and Ca²⁺-release endoplasmic reticulum channels (24). Gadolinium also inhibits the action of ionophoric colicins, resulting in an indirect blockade of Na⁺/K⁺ ATPase activity (25). Gadolinium potentiates GABA-induced chloride currents (26). Gadolinium, and several other trivalent cations inhibit ATP-gated channels at low concentrations (27). Because of the diversity of ion transport mechanisms altered by lanthanides, it is conceivable that free Gd³⁺, even if present in very small concentrations, could interfere with iodine transport.

Although we have not definitively proven that Gd does not

interact with the Na-I- co-transporter mechanism, either directly or indirectly, we have shown that the small amount of Gd³⁺ likely present in MRI contrast media does not statistically alter the uptake of radioiodine by the thyroid gland. Since well-differentiated thyroid cancer is thought to accumulate iodine by the same mechanism as does normal thyroid tissue, our data suggest that the performance of MRI with gadolinium contrast media can be done safely in patients, without fear of confounding subsequent imaging or radiotherapy with radioactive iodine.

CONCLUSION

Our data did not show a statistically significant difference in uptake of iodine by the thyroid gland caused by gadolinium contrast. The 95% confidence range was –2.8 to 1.4% in our group of 10 patients for 24 h. Uptake shows that the mean difference in uptake caused by gadolinium contrast is less than 3%. This value is too small to have a clinically significant effect on patient management. Anatomic imaging with gadolinium contrast-enhanced MRI or MRA is unlikely to result in clinically significant problems with determinations of uptake, imaging or therapy with radioactive iodine.

ACKNOWLEDGMENT

This research was supported by the Department of Veterans Affairs.

REFERENCES

1. Robbins J, Merino MJ, Boice JD Jr, et al. Thyroid cancer: a lethal endocrine neoplasm. *Ann of Intern Med.* 1991;115:133–147.
2. Mettler FA, Guiberteau MJ. *Essentials of Nuclear Medicine Imaging*. 3rd ed. Philadelphia, PA: WB Saunders Co.; 1991:79.
3. Thrall JH, Ziessman HA. *Nuclear Medicine. The Requisites*. St. Louis, MO: Mosby-Year Book, Inc.; 1995:324.
4. Hamill OP, McBride DW Jr. The pharmacology of mechanogated membrane ion channels. *Pharmacol Rev.* 1996;48:231–252.
5. Becker DV, Charkes ND, Hurley JR, et al. Endocrine guidelines: procedure guideline for thyroid uptake measurement. In: Guidelines and Procedure Committee, Commission on Health Care Policy and Practice, eds. *Society of Nuclear Medicine Procedure Guidelines Manual*. Reston, VA: Society of Nuclear Medicine; 1999:29–32.
6. Kaminsky SM, Levy O, Salvador C, et al. Na(+)-I- symport activity is present in membrane vesicles from thyrotropin-deprived non-I transporting cultured thyroid cells. *Proc Natl Acad Sci USA.* 1994;91:3789–3793.
7. Cavalieri RR. Iodine metabolism and thyroid physiology: current concepts. *Thyroid.* 1997;7:177–181.
8. Dai G, Levy O, Carrasco N. Cloning and characterization of the thyroid iodide transporter. *Nature.* 1996;379:458–460.
9. Parravicini E, Fontana C, Paterlini GL, et al. Iodine, thyroid function, and very low birth weight infants. *Pediatrics.* 1996;98:730–734.
10. Sergeev PV, Belykh AG. Effect of contrast agents on the iodine-absorbing function of the thyroid gland. *Farmakol Toksikol.* 1982;45:96–100.
11. Jaffiol C, Baldet L, Bada M, Vierne Y. The influence on thyroid function of two iodine-containing radiological contrast media. *Br J Radiol.* 1982;55:263–265.
12. Mann K, Rendl J, Busley R, et al. Systemic iodine absorption during endoscopic application of radiographic contrast agents for endoscopic retrograde cholangiopancreatography. *Eur J Endocrinol.* 1994;130:498–501.
13. L'Allemand D, Gruters A, Beyer P, Weber B. Iodine in contrast agents and skin disinfectants is the major cause for hypothyroidism in premature infants during intensive care. *Hormone Res.* 1987;28:42–29.

14. Martin FI, Tress BW, Colman PG, Deam DR. Iodine-induced hyperthyroidism due to nonionic contrast radiography in the elderly. *Am J Med.* 1993;95:78–82.
15. Nolte, Muller R, Siggelkow H, et al. Prophylactic application of thyrostatic drugs during excessive iodine exposure in euthyroid patients with thyroid autonomy: a randomized study. *Eur J Endocrinol.* 1996;134:337–341.
16. Jackson GE, Byrne MJ. Metal ion speciation in blood plasma: gallium-67-citrate and MRI contrast agents. *J Nucl Med.* 1996;37:379–386.
17. Diem K, Lentner C, eds. *Scientific Tables.* 7th ed. Ardsley, NY: Geigy Pharmaceuticals; 1970:518.
18. Das T, Sharma A, Talukder G. Effects of lanthanum in cellular systems. *Biol Trace Elem Res.* 1988;18:201–228.
19. Bustamante JO. Modification of sodium channel currents by lanthanum and lanthanide ions in human heart cells. *Can J Physiol Pharmacol.* 1987;65:591–597.
20. Lacampagne A, Gannier F, Argibay J, et al. The stretch-activated ion channel blocker gadolinium also blocks L-type calcium channels in isolated ventricular myocytes of the guinea-pig. *Biochem Biophys Acta.* 1994;1191:205–208.
21. Biagi BA, Enyeart JJ. Gadolinium blocks low- and high-threshold calcium currents in pituitary cells. *Am J Physiol.* 1990;259:C515–520.
22. Elinder F, Arhem P. The modulatory site for the action of gadolinium on surface charges and channel gating. *Biophys J.* 1994;67:84–90.
23. Elinder F, Arhem P. Effects of gadolinium on ion channels in the myelinated axon of *Xenopus laevis*: four sites of action. *Biophys J.* 1994;67:71–83.
24. Klusener B, Boheim G, Liss H, et al. Gadolinium-sensitive, voltage-dependent calcium release channels in the endoplasmic reticulum of a higher plant mechanoreceptor organ. *EMBO J.* 1995;14:2708–2714.
25. Bonhivers M, Guihard G, Pattus F, Letellier L. In vivo and in vitro studies of the inhibition of the channel activity of colicins by gadolinium. *Eur J Biochem.* 1995;229:155–163.
26. Ma JY, Narahashi T. Enhancement of the gamma-aminobutyric acid-activated chloride channel currents by lanthanides in rat dorsal root ganglion neurons. *J Neurosci.* 1993;13:4872–4879.
27. Nakazawa K, Liu M, Inoue K, Ohno Y. Potent inhibition by trivalent cations of ATP-gated channels. *Eur J Pharmacol.* 1997;325:237–243.