

# Hot Spots Observed on Pulmonary Perfusion Imaging: A Case Report

Hiroo Ikehira, Masaki Kinjo, Yoshikazu Yamamoto, Harufumi Makino, Yoskiaki Furuichi, Hirokazu Nakamura and Tadashi Aoki

Departments of Radiology and Surgery, Kawatetsu Chiba Hospital, Chiba, Japan

A case of hot spots observed on perfusion lung images is presented. This artifact is well known, however, it is rarely seen in our experience. Although this artifact can occur if a faulty injection technique is used, the artifact also may be caused by embolization of the MAA in the upper extremity venous blood after injection. This cause of the artifact is beyond the control of the nuclear medicine professional.

**Key Words:** technetium-99m-MAA; pulmonary hot spot artifact; lung scintigraphy; pulmonary embolism

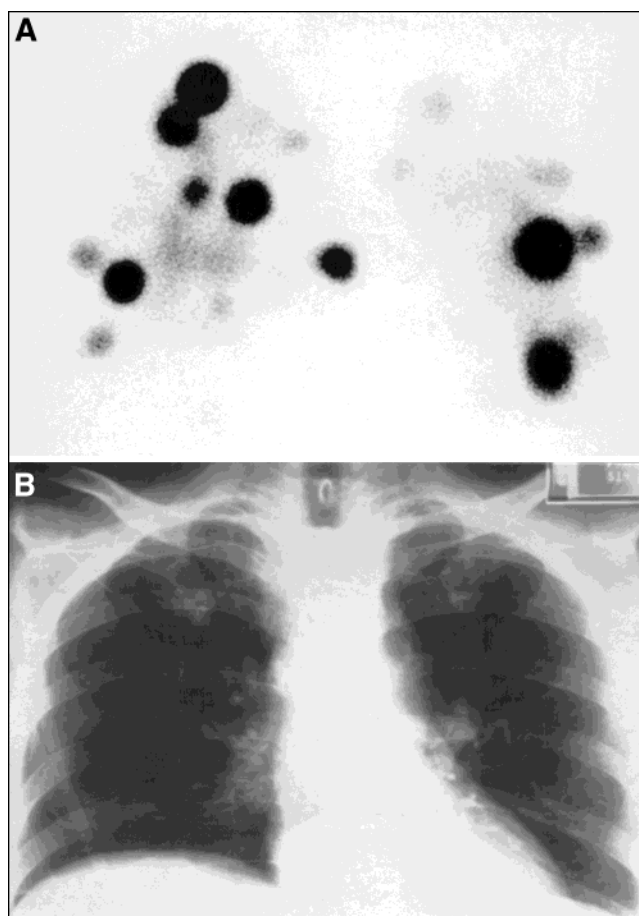
*J Nucl Med Technol* 1999; 27:301–302

The usefulness of pulmonary scintigraphy in diagnosing pulmonary embolism is well known (1,2). Hot spots on the perfusion lung scan have been recognized as a complication of faulty injection technique (3). We recently experienced the hot spot artifact during perfusion lung scintigraphy performed on a patient with severe pulmonary emboli.

## CASE REPORT

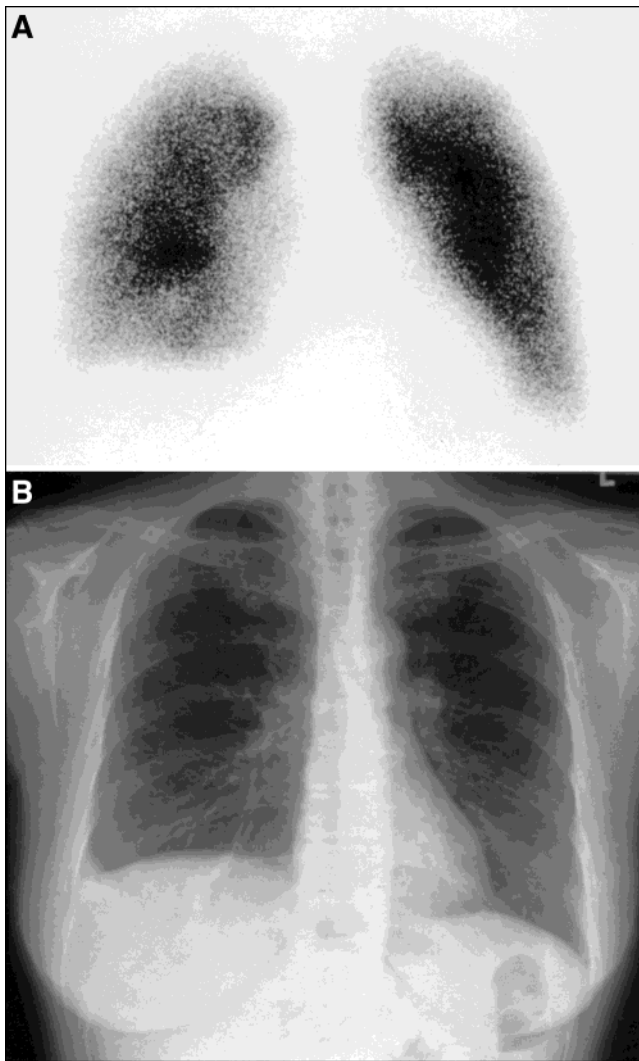
Lung perfusion scintigraphic images were obtained after administering 185 MBq (5 mCi)  $^{99m}\text{Tc}$ -MAA using a high-resolution, parallel-hole collimator attached to a scintigraphic camera. The patient was a 58-y-old woman who was 4 d posthemicolectomy for the excision of colon cancer. She was referred to nuclear medicine to rule out pulmonary embolism as the source of her symptoms. Figure 1A is the anterior lung perfusion image we obtained. There are multiple bilateral perfusion defects and multiple hot spot artifacts. Figure 1B is the chest radiograph performed at the same time. The chest radiograph indicated the disappearance of pulmonary vessel shadows due to very low pulmonary perfusion. The patient was treated with urokinase and heparin. Figure 2A is the anterior lung perfusion image we obtained 18 d later. There was nearly normal perfusion at that time and no hot spot artifacts were observed. The images demonstrate the effectiveness of therapy in this patient and further documents that the

perfusion defects seen earlier were most likely due to multiple pulmonary emboli. The improvement in pulmonary perfusion seen as the pulmonary emboli resolve over time also is seen on scintigraphic perfusion images. The chest radiograph at this time (Fig. 2B) showed normal pulmonary vessel shadows.



**FIGURE 1.** (A) The anterior lung perfusion image with multiple bilateral perfusion defects and multiple hot spot artifacts. (B) The chest radiograph performed at the same time. The chest radiograph shows the disappearance of pulmonary vessel shadows due to very low pulmonary perfusion.

For correspondence or reprints contact: Dr. Hiroo Ikehira, 3-38-10, Izumidai, Ichihara-shi, Chiba-ken, 299-0114, Japan.



**FIGURE 2.** (A) The anterior lung perfusion image obtained 18 d later. There was nearly normal perfusion at that time and no hot spot artifacts were observed. The images demonstrate the effectiveness of therapy in this patient and further documents that the perfusion defects observed earlier most likely were due to multiple pulmonary emboli. (B) The chest radiograph at this time showed normal pulmonary vessel shadows.

## DISCUSSION

We were surprised to experience this hot spot artifact because we thought we had properly prepared and injected the  $^{99m}\text{Tc}$ -MAA. We had not experienced the artifact before or after this patient. There are reports of nontechnical causes of this artifact (4,5), including active concurrent thrombophlebitis in the upper extremities. Theoretically it is possible that the hot spots were caused by incorporation of the MAA into small blood clots forming in the upper extremity venous blood after injection, however, we have no proof that this is what happened.

## CONCLUSION

Based on the literature, we assume this artifact most likely was caused by either incomplete separation of the MAA particles during radiopharmaceutical preparation or inadvertently mixing a small amount of venous blood with the MAA in the injection syringe, at the time of venipuncture and before the actual injection, which caused small clots to form. This case reminds us that careful radiopharmaceutical preparation and venipuncture and injection technique are always important. Even though we thought we had been careful, it is easy to introduce an artifact. If the hot spots were caused by embolization of the MAA in the upper extremity venous blood after injection, we could not have prevented this from occurring.

## REFERENCES

1. Christiansen F, Nilsson T, Mare K, et al. Observer agreement and accuracy for lung scintigraphy: a comparison with pulmonary angiography. *Nucl Med Commun.* 1997;18:112–117.
2. Shih WJ, Pulmano C. Massive pulmonary embolism without symptoms demonstrated by radionuclide imaging with thromboemboli in both main pulmonary arteries. *Clin Nucl Med.* 1996;21:465–468.
3. Preston DF, Greenlaw RH. “Hot spots” in lung scans. *J Nucl Med.* 1970;11:422–425.
4. Lutzker LG, Perez LA. Radioactive embolization from upper-extremity thrombophlebitis. *J Nucl Med.* 1975;16:241–242.
5. Goldberg E, Lieberman C. “Hot Spots” in lung scans [Letter]. *J Nucl Med.* 1977;18:499–500.