
The Role of Morphine-Augmented Cholescintigraphy and Real-Time Ultrasound in Detecting Gallbladder Disease

Mordechai Lorberboym, Julietta Simon and Tifha Horne

Departments of Nuclear Medicine and Radiology, Edith Wolfson Medical Center, Holon; Department of Nuclear Medicine, Assaf Harofeh Medical Center, Tel Aviv; and Sackler Faculty of Medicine, Tel Aviv University, Tel Aviv, Israel

Objective: Rapid diagnosis of acute cholecystitis is essential to minimize morbidity and mortality. The purpose of this study was to assess the diagnostic utility of cholescintigraphy using morphine augmentation compared with ultrasound, in acute and chronic gallbladder disease.

Methods: Cholescintigrams were performed on 103 patients suspected of having acute cholecystitis. In 79 patients (Group A) morphine sulfate was administered to reduce the scintigraphic imaging time if the gallbladder was not visualized during the first hour. In 24 control patients (Group B) no morphine was administered. All patients were evaluated clinically and 93 patients had concurrent ultrasound examination.

Results: The clinical presentation was nonspecific. The ultrasound findings were sensitive in detecting gallbladder disease (100%), but had low specificity (24%). Only findings of sediments and pericholecystic fluid were specific for cystic duct obstruction. Morphine augmentation reduced the imaging time by 126 min in patients with chronic cholecystitis.

Conclusion: Real-time ultrasound has low specificity for gallbladder disease. In the presence of an abnormal ultrasound, it is essential to perform a hepatobiliary scan, either to exclude gallbladder disease or distinguish acute from chronic cholecystitis. Low-dose morphine administration is a safe and useful adjunct to standard cholescintigraphy by substantially reducing the time required to obtain a diagnostic study.

Key Words: morphine-augmented cholescintigraphy; acute cholecystitis; chronic cholecystitis; ultrasound in gallbladder disease

J Nucl Med Technol 1999; 27:294–297

Acute cholecystitis refers to acute inflammation of the gallbladder due to obstruction of the cystic duct by an impacted stone. Acalculous cholecystitis accounts for 5% of acute cholecystitis.

An accurate and timely diagnosis is important as gallbladder empyema, necrosis and perforation may occur (1). Chronic gallbladder disease may develop in up to 35% of the cases (2).

The clinical presentation and laboratory tests in acute cholecystitis can result from other conditions (3–4), and may not be sufficient to establish the diagnosis. Real-time ultrasound is used frequently as the first imaging modality in patients with acute right upper quadrant pain. It provides information about gallbladder anatomy and shows the presence of stones with high accuracy. Most of the ultrasound findings, however, are indicative of, but not pathognomonic for, acute cholecystitis (5).

Technetium-99m-iminodiacetic acid (IDA) cholescintigraphy is the most sensitive method for assessing the patency of the cystic duct (6). In this study we correlated the scintigraphic findings of acute and chronic cholecystitis with the typical ultrasound signs of gallbladder disease.

MATERIALS AND METHODS

From January 1995 to December 1997, 103 consecutive patients with right upper quadrant pain were referred for hepatobiliary imaging. All patients (50 women, 53 men; mean age 61 y; age range 20–90 y) had fasted for at least 4 h before the intravenous administration of 185 MBq ^{99m}Tc-DIPA (diisopropyl-IDA). Sequential anterior dynamic images every 60 s were obtained for 1 h, using a large field-of-view gamma camera equipped with a low-energy, high-resolution parallel-hole collimator. Right lateral views were obtained routinely at 60 min.

In Group A (N = 79), 0.04 mg/kg of morphine diluted in 10 mL saline was given intravenously over a period of 3 min when the gallbladder was not visualized by 1 h, however, there was normal excretion of radiotracer into the duodenum. Serial images were obtained for an additional 30 min. In Group B (N = 24), no morphine was administered at 1 h, and imaging continued up to 4 h, or until gallbladder visualization occurred.

A working diagnosis of chronic cholecystitis was presumed if the gallbladder was visualized after 60 min of imaging. A working diagnosis of acute cholecystitis was presumed if there

For correspondence or reprints contact: Mordechai Lorberboym, MD, Dept. of Nuclear Medicine, Edith Wolfson Medical Center, Holon, 58100, Israel; Phone: 011-972-3-5028569.

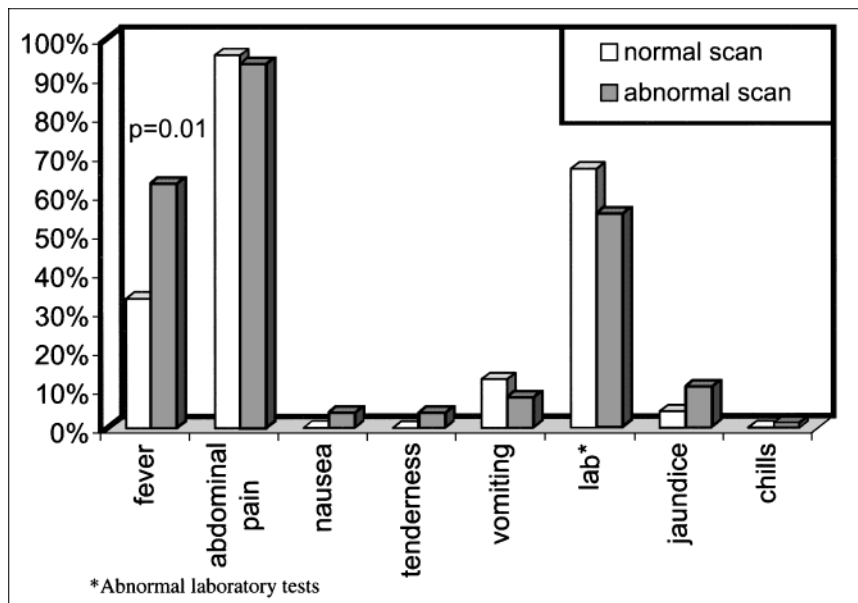


FIGURE 1. Clinical presentation compared with scan findings in patients with suspected gallbladder disease.

was persistent nonvisualization of the gallbladder 30 min postmorphine administration, or after 4 h of imaging without morphine.

All patients underwent clinical evaluation, and 93 patients had concurrent ultrasound examination within 24 h of hepatobiliary imaging. The final diagnosis was confirmed in 30 postoperative patients histologically and, in the remainder, the final diagnosis was taken from their medical records. Clinical and imaging findings were assessed in patients with normal gallbladders, and compared with the findings in patients with acute or chronic cholecystitis using Student's *t* test or chi-square analysis. For small values the Fisher exact test was used.

RESULTS

The most frequent clinical complaints on admission were abdominal pain (94%), and fever (56%), while abdominal tenderness, nausea or vomiting appeared in less than 10% of patients. There was no significant statistical difference in clinical presentation among patients with a normal scan and those with gallbladder disease, except for fever which was more common in patients with abnormal scans (Fig. 1).

In Group A, the gallbladder was visualized by 1 h (average 29 min \pm 15 min) in 25 of 79 patients and the IDA scan was terminated (Table 1). In 54 of 79 patients the gallbladder was

not observed by 1 h and each of these patients received morphine. In 12 of 54 patients the gallbladder was seen after morphine administration (average 69 min \pm 5 min.), while the remaining 42 patients had no gallbladder visualization and the study was terminated at 90 min (30 min postmorphine).

In the 24 control patients with no morphine administration (Group B), the average interval to gallbladder visualization was 195 min (8 of 24 patients), whereas in 16 of 24 patients the study was continued to 240 min with no gallbladder visualization. On average, morphine administration shortened the study by 126 min ($P < 0.001$).

Figure 2 shows ultrasound findings in 100% of patients with cystic duct obstruction, and in 78% of patients with no obstruction. Gallstones, thickened walls and gallbladder swelling were more common in patients with obstruction. Although gallbladder sludge and pericholecystic fluid were observed only in patients with obstruction, these findings had low sensitivity (7% and 28%, respectively), and could not differentiate between acute and chronic cholecystitis (Fig. 3).

Figure 4 shows a patient with congestive heart failure and right upper quadrant pain. The ultrasound (Fig. 4A) shows a distended gallbladder with thickened walls and sludge. The hepatobiliary scan is normal (Fig. 4B).

TABLE 1
Effect of Morphine Administration on Hepatobiliary Imaging Time

Morphine	Group A			Group B	
	Gallbladder visualization without morphine (negative study)	Gallbladder visualization with morphine (positive study)	No gallbladder visualization with morphine (positive study)	Gallbladder visualization without morphine (negative study)	No gallbladder visualization without morphine (positive study)
Scan time (min)	<60	60-90	90	60-240	240
No. of patients	25	12	42	8	16
Mean (min)	29.2	68.6	90	195	240
SD	15.1	5.4	0	22.7	0

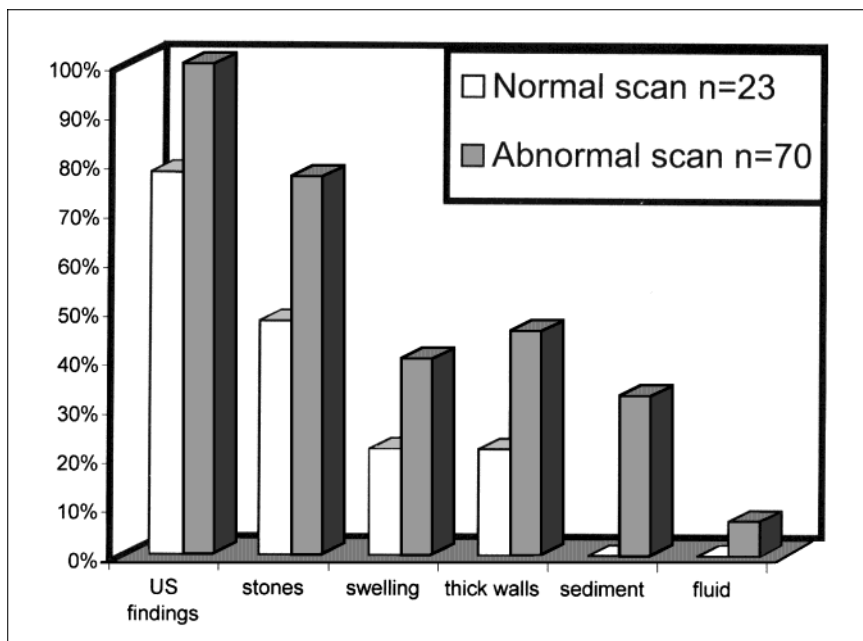


FIGURE 2. Ultrasound findings compared with hepatobiliary imaging results.

DISCUSSION

The clinical presentation of acute cholecystitis includes fever, chills, right upper quadrant pain, nausea and vomiting (1). A mild-to-moderate leukocytosis and mildly abnormal liver function tests also are common. These findings, however, can be mimicked by various pathologic conditions (3). The diagnosis of acute cholecystitis is particularly difficult to establish in critically ill patients.

Ultrasonography has good resolution and the ability to visualize gallstones or sludge, a thickening or distension of the gallbladder. It also may detect nonbiliary sources of right upper quadrant pain. Nevertheless, ultrasound is incapable of evaluating the functional filling of the gallbladder and patency of the cystic duct. Many individuals develop asymptomatic gallstones or sludge each year (7) and the sonographic abnormalities may

not reflect acute gallbladder disease. Likewise, hypoalbuminemia, heart failure and other local inflammatory diseases may cause edema of the gallbladder wall, a major sign of acute cholecystitis (7–8).

Using liberal criteria, ultrasound of the gallbladder is 80%–86% sensitive, but only 24% sensitive using strict criteria (pericholecystic fluid and wall edema) (5). In our study, all patients with gallbladder disease had ultrasound findings (100% sensitivity). However, most findings were not specific for cystic duct obstruction and were present also in patients with no obstruction (24% specificity in this study, which is lower than the 60%–64% specificity reported in the literature).

Radionuclide hepatobiliary imaging using ^{99m}Tc-IDA derivatives is a safe, simple, and extremely accurate procedure for evaluating acute cholecystitis. A positive scintigram (nonvisual-

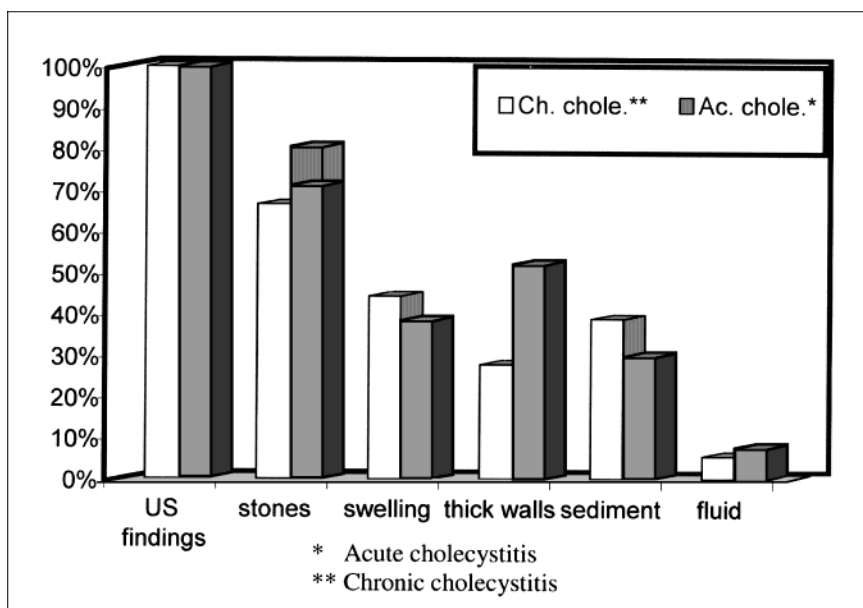


FIGURE 3. Ultrasound findings in patients with acute and chronic cholecystitis.

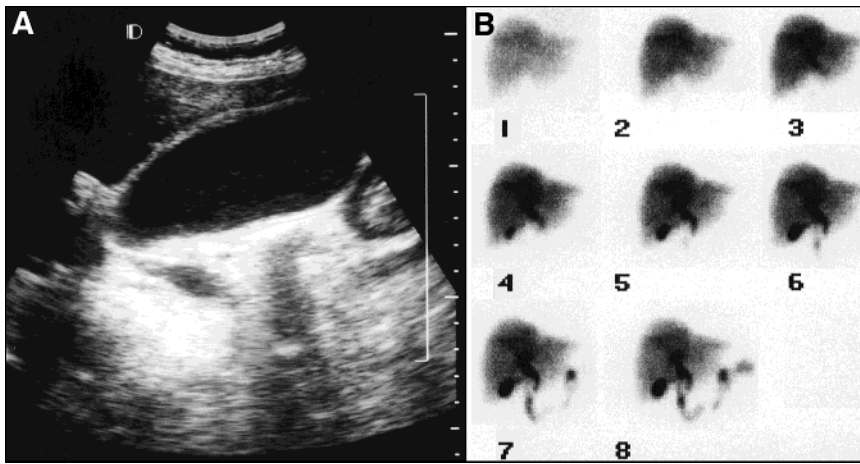


FIGURE 4. (A) Ultrasound of a patient with congestive heart failure showing a distended gallbladder with thickened walls and sludge. (B) The hepatobiliary scan demonstrates gallbladder visualization and excretion of bile, which are normal findings.

ization of the gallbladder) correlates closely with acute cholecystitis. The sensitivity and specificity of the study in confirming the diagnosis of acute cholecystitis is greater than 95% (9). The routine imaging protocol may require 4 h of imaging, or even 24 h in patients with severe intercurrent disease (10), to achieve high accuracy. Prolonged imaging is inconvenient and may not be feasible in some clinical conditions. Technical factors may affect the results, such as insufficient time allowed for gallbladder visualization and failure to perform delayed imaging, particularly in patients with chronic cholecystitis. Delayed images may be limited technically by the progressive decline in activity within the biliary system that accompanies physiologic emptying and tracer decay.

Low-dose morphine administration is a useful adjunct to conventional cholescintigraphy because it reduces the time required to obtain a diagnostic result and it may decrease the number of false-positive results (11–16). It is particularly useful when rapid diagnosis is critical. Morphine sulfate enhances the tone of the sphincter of Oddi, increasing the intraluminal pressure of the common bile duct (17). The increased intraluminal pressure is sufficient to divert the flow of bile or a radiopharmaceutical agent into a sluggish, distended, or sludge-filled gallbladder, thereby avoiding false-positive results.

CONCLUSION

This study indicates that the absence of sonographic findings in patients with right upper quadrant pain excludes the diagnosis of acute cholecystitis with a high degree of confidence and hepatobiliary scintigraphic imaging is probably unnecessary. Due to the markedly low specificity of the sonographic findings, however, it is essential to perform an IDA scan, either to exclude gallbladder disease or to distinguish acute from chronic cholecystitis, in the presence of abnormal ultrasound. The use of morphine-augmented cholescintigraphy is a safe and useful adjunct to standard cholescintigraphy by reducing substantially the time required to obtain a diagnostic study.

REFERENCES

1. Jones RS. Gallbladder and biliary tract. In: Hardy JD, ed. *Hardy's Textbook of Surgery*. 2nd ed. Philadelphia, PA: JB Lippincott; 1988:677–690.
2. Davis GB, Berk RN, Scheible FW, et al. Cholecystokinin cholecystography, sonography, and scintigraphy: detection of chronic acalculous cholecystitis. *AJR*. 1982; 139:1117–1121.
3. Hermann RE, Vogt DP. Biliary system. In: Davis JH, Drucker WR, Foster RS, et al., eds. *Clinical Surgery, Vol. 2*. St Louis, MO: CV Mosby; 1987:1637–1681.
4. McFadden DW, Zinner MJ. Manifestations of gastrointestinal disease. In: Schwartz SI, ed. *Principles of Surgery, Vol. 1*. 6th ed. New York, NY: McGraw Hill; 1994:1015–1042.
5. Fink-Bennett D, Freitas JE, Ripley SD, Bree RL. The sensitivity of hepatobiliary imaging and real-time ultrasonography in the detection of acute cholecystitis. *Arch Surg*. 1985;120:904–906.
6. Weissmann HS, Rosenblatt R, Sugarman LA, Freeman LM. An update in radionuclide imaging in the diagnosis of cholecystitis. *JAMA*. 1981; 246:1354–1357.
7. Weissmann HS, Freeman LM. The biliary tract. In: Freeman LM, ed. *Freeman and Johnson's Clinical Radionuclide Imaging*. 3rd ed. Orlando, FL: Grune and Stratton; 1984:879–1049.
8. Rosenthal SJ, Cox GG, Wetzel LH, Batnitzky S. Pitfalls and differential diagnosis in biliary sonography. *Radiographics*. 1990;10:285–311.
9. Drane WE, Nelp WB, Rudd TG. The need for routine delayed radionuclide hepatobiliary imaging in patients with intercurrent disease. *Radiology*. 1984;151:763–769.
10. Kistler AM, Ziessman HA, Gooch D, Bitterman P. Morphine-augmented cholescintigraphy in acute cholecystitis. A satisfactory alternative to delayed imaging. *Clin Nucl Med*. 1991;16:404–406.
11. Fink-Bennett D, Balon H, Robbins T, Tsai D. Morphine-augmented cholescintigraphy: its efficacy in detecting acute cholecystitis. *J Nucl Med*. 1991;32:1231–1233.
12. Vasquez TE, Greenspan G, Evans DG, et al. Clinical efficacy of intravenous morphine administration in hepatobiliary imaging for acute cholecystitis. *Clin Nucl Med*. 1988;13:4–6.
13. Fink-Bennett D, Balon HR. The role of morphine-augmented cholescintigraphy in the detection of acute cholecystitis. *Clin Nucl Med*. 1993;18:891–897.
14. Ziessman HA. Scintigraphy in the gastrointestinal tract. *Curr Opin Radiol*. 1992;4:105–116.
15. Kim CK, Worsley DF, Machac J. Interventions in gastrointestinal nuclear medicine. In: Freeman LM, ed. *Nuclear Medicine Annual 1996*. Philadelphia, PA: Lippincott-Raven; 1996:213–257.
16. Murphy P, Solomon J, Roseman DL. Narcotic anesthetic drugs: their effect on biliary dynamics. *Arch Surg*. 1980;115:710–711.
17. Dedrick DF, Tanner WW, Bushkin FL. Common bile duct pressure during enflurane anesthesia. Effects of morphine and subsequent naloxone. *Arch Surg*. 1980;115:820–822.