

Breast Tumor Scintigraphy

Patrick J. Peller, Nanda Y. Khedkar and Charles J. Martinez

Nuclear Medicine Division, Lutheran General Hospital, Park Ridge, Illinois

Breast cancer is the most common and, probably, the most feared malignancy of American women today. Although screening with breast examination and mammography is extremely important in the early detection of breast cancer, the limited specificity of these techniques creates the need for an adjunctive diagnostic tool. Technetium-99m-sestamibi was originally developed as a myocardial perfusion agent but also preferentially accumulates intracellularly in metabolically active breast cancer tissue. Sestamibi breast imaging can delineate breast cancers and exclude the presence of a neoplastic process with high accuracy. Careful attention to imaging parameters provides high-quality breast tumor scintigraphy. Breast scintigraphy can be a valuable, adjunctive diagnostic tool in evaluating breast abnormalities.

Key Words: breast cancer; technetium-99m-MIBI; thallium-201; fluorine-18-FDG; breast imaging

J Nucl Med Technol 1996; 24:198-203

Breast cancer is the most common visceral neoplasm affecting American women, with approximately 182,000 breast cancers diagnosed in 1995. The incidence of breast cancer has been increasing at an annual rate of more than 1% since the 1940s in the U.S. Recently, the rate of increase rose to nearly 4% per year. Breast cancer mortality also has been increasing over the same period, but more slowly with an estimated 46,000 American women dying of breast cancer in 1995. Breast cancer remains the leading cause of death among women aged 40 to 55 yr. Overall, breast cancer will strike one in every nine women in the U.S., accounting for 32% of all cancers and 18% of all cancer deaths in women (1).

Despite the plethora of statistics available about breast cancer, these numbers still fail to depict the full impact of breast cancer on women. For every one woman diagnosed with breast cancer, another five or six will have a biopsy that shows benign breast disease. And for every woman biopsied it is likely that an additional five go to their physician for evaluation of a worrisome breast mass or for counseling about their risk of breast

cancer. Thus, 10 to 20 million American women seek medical care each year for a potential breast cancer (2).

The first and best line of defense against breast cancer is early detection. Early detection, coupled with aggressive treatment, yields improved life expectancy and, in some individuals, the cure of their breast cancer. Three early-detection methods are currently employed: breast self-examination, clinical breast examination and screening mammography. With good patient education, monthly breast self-examination can bring breast neoplasms to medical attention at approximately 1–2-cm in size. Clinical breast examination by a trained health care provider generally can detect breast masses down to about 8 mm in diameter depending on the location and size of breast mass, breast size and the examiner's ability. Screening mammography has the potential to detect lesions well before they are palpable. The threshold for screening mammography may be as low as 2 mm (3).

Mammography detects the differential attenuation of x-rays passing through compressed breast tissue. Breast malignancies are detected due to calcifications within or around neoplasms or the increased density of the neoplastic tissue relative to adjacent normal breast tissue (Fig. 1). Prospective mammography research studies have demonstrated a 30% reduction in mortality in women over the age of 50 yr. Smaller, but similarly important reductions in mortality can be realized in women under the age of 50 yr. Mammography with current film screen technique is quite sensitive in detecting breast cancer (4).

Neither breast examination nor mammography can accurately differentiate breast cancer from the myriad of benign breast abnormalities. Therefore, each patient with a palpable breast abnormality or a positive mammogram requires an additional diagnostic step before treatment can be undertaken. Currently, the only means of confirming the nature of a suspicious breast abnormality is a biopsy. Fine needle aspiration cytology, stereotactic needle biopsy and surgical open-breast biopsies can provide breast cells or tissue for a pathologist to evaluate for the presence of breast cancer. Fine needle aspirate and stereotactic biopsy techniques are less invasive and traumatic and are becoming more prevalent, accepted and widely utilized (5).

Breast biopsy results are negative for breast cancer in 68–87% of women (6). Thus, while many breast abnormalities are

For correspondence or reprints contact: Patrick J. Peller, MD, Lutheran General Hospital, Nuclear Medicine Division, 1775 Dempster St., Park Ridge, IL 60068.

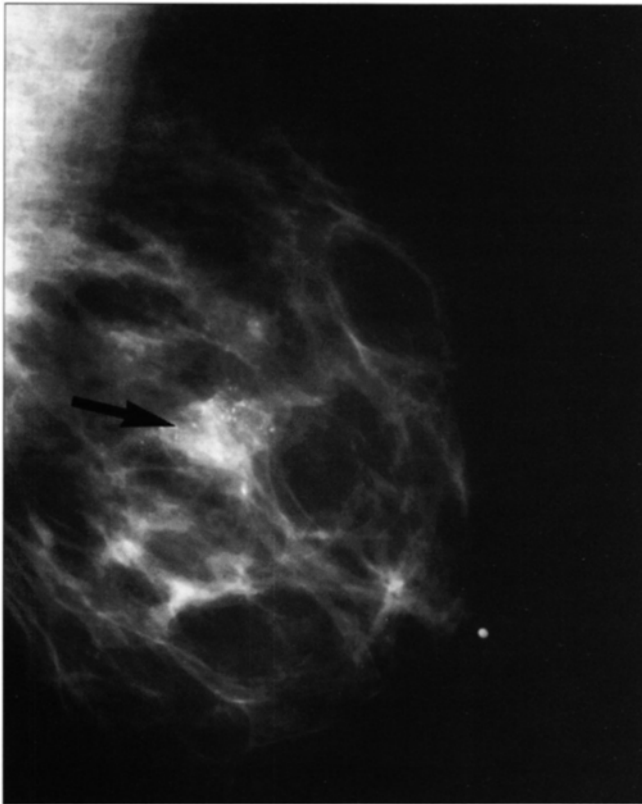


FIGURE 1. Left mediolateral oblique mammogram demonstrates scattered irregular calcifications surrounding an irregular density which on excisional surgical biopsy demonstrated intraductal carcinoma.

detected by breast examination and mammography, the vast majority of the positive findings prove to be falsely positive for malignancy. The dilemma for women and their physicians is that breast examination and mammography, while finding many early breast cancers, also subject thousands of women to a potentially unnecessary biopsy procedure with the associated risk, discomfort and expense. Therefore, many investigators have evaluated a wide variety of imaging modalities in an attempt to increase the specificity of breast cancer diagnosis noninvasively.

BREAST SCINTIGRAPHY

Technetium-99m-sestamibi (MIBI) was originally developed for cardiac imaging, and is now well-established as a myocardial perfusion agent. Technetium-99m-MIBI is distributed initially throughout the body in proportion to blood flow (7), rapidly clears the blood stream and enters cells by passively diffusing across cell membranes. Technetium-99m MIBI is fixed intracellularly in proportion to the metabolic activity of the cell. Most breast cancers have increased blood flow and many tumors induce the development of new blood vessels strictly to facilitate tumor growth. Neoplastic cells have a metabolic rate of 4–10 times that of normal cells (8). This suggested the potential for breast tumor imaging with ^{99m}Tc -MIBI.




FIGURE 2. Padded table with a cutout for prone breast scintigraphy is shown with adjacent gamma camera ready to begin positioning a patient. This table is firmly secured to an existing SPECT table.

In all nuclear medicine studies, close adherence to a standardized imaging protocol detailing patient preparation, radiopharmaceutical administration, positioning and acquisition parameters is very important in obtaining high-quality images for interpretation. Our standard imaging protocol is given in Appendix A. Positioning is of major importance in prone breast imaging. A breast lesion can be located in a myriad of locations depending on how the patient is positioned. The technique of prone breast imaging described by Khalkhali et al. (9) allows for separation of breast tissue from thoracic and upper abdominal activity, yet maintaining normal breast anatomy and contour. Incorrect positioning, such as accidental compression of the breast on the imaging table, can produce false abnormalities. Extending the ipsilateral arm over the head allows the axilla to come in contact with the collimator surface and to be included in the field of view. The use of a table overlay with a cutout for the breast (Fig. 2) enhances patient safety and comfort. The quality of images is often also improved (9) (Fig. 3).

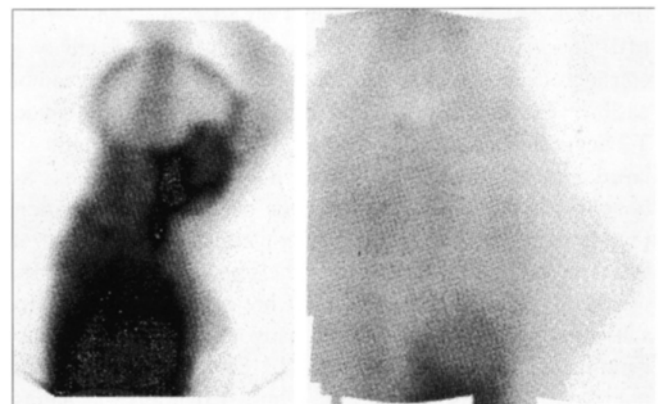


FIGURE 3. Normal sestamibi breast imaging. (A) Without a specialized table, the patient was placed on the edge of a SPECT table. Normal distribution of sestamibi is seen throughout the liver and salivary glands. This positioning was both precarious and uncomfortable for the patient. (B) Using a table overlay and adding zoom excluded the liver and head from the field of view. Normal breast tissue has very little sestamibi uptake relative to the liver and heart.

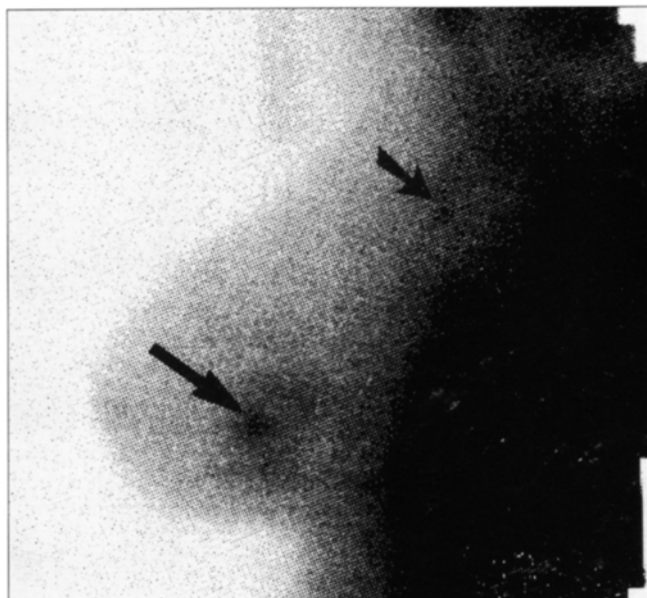

FIGURE 4. Prone scintigraphy demonstrates a breast cancer in a 49-year old female with a palpable mass in the left breast. Intense sestamibi uptake (long arrow) occurred in the mass. Surgical biopsy confirmed intraductal breast cancer. Axillary nodal activity (short arrow) resulted from breast cancer metastases.

Technetium-99m-MIBI is homogeneously distributed throughout normal breast tissue (Fig. 3). This normal pattern occurs irrespective of the breast density on mammogram and fibrocystic changes felt on the clinical breast examination. Intense ^{99m}Tc -MIBI uptake occurs within the liver and heart and should be excluded, when possible, from the imaging field of view. Sestamibi accumulation within the thyroid and salivary glands is usually of moderate intensity. The ^{99m}Tc -MIBI accumulation in normal breast tissue is low and is best evaluated on a computer monitor where the gray scale can be adjusted by the interpreter.

Technetium-99m-MIBI uptake within breast neoplasms ranges from just above normal breast activity to more than five times the activity found in normal breast tissue. Any ^{99m}Tc -MIBI accumulation greater than adjacent breast activity is considered positive (Fig. 4). Breast tumor visualization can be easily made as early as 3 to 4 min after tracer injection. Technetium-99m-MIBI undergoes very little clearance and delayed images up to 2 hr will produce similar findings. No benefit of delayed imaging has been observed in our patient population. The smallest breast neoplasm detected measured 8 mm in its greatest dimension. The intensity of ^{99m}Tc -MIBI uptake is greatest within primary breast cancers which are subsequently shown to have already metastasized. Axillary lymph node metastases can often be demonstrated by sestamibi breast images. Technetium-99m-MIBI uptake in metastases can be of equal or even greater intensity than the primary breast lesion uptake. Axillary uptake is visible when multiple lymph nodes are involved with metastatic breast cancer. In our patients, we have also demonstrated ^{99m}Tc -MIBI accumulation in breast cancer metastases to supracavicular, paratracheal and hilar lymph nodes and the sternum.

TABLE 1
Published Sestamibi Breast Imaging Results

Lead author	Number of patients (N)	Sensitivity	Specificity
Burak (10)	41	92.6	87.7
Kao (11)	38	84	100
Khalkhali (12)	147	92.2	89.2
Lu (13)	50	93	84
Taillefer (14)	65	91.5	94.4
Total no. of patients	341		
Range		84-93	84-100
N-weighted mean		91.3	90.5

In published research series (Table 1), sestamibi breast imaging has demonstrated high sensitivity and specificity in differentiating benign from malignant breast lesions when compared to microscopic evaluation of breast tissue after biopsy. Our evaluation of sestamibi breast imaging has yielded similar sensitivity (91.6%) and specificity (93.1%) to published results. Sestamibi breast imaging is generally more accurate when evaluating breast abnormalities found by physical examination than those detected by mammography. In our population, the negative predictive value for palpable lesions has been 100%. Thus, if a breast lesion is palpable but not visible on sestamibi breast imaging, it is unlikely to represent a breast neoplasm. Mammographic lesions are generally smaller abnormalities than palpable lumps and, therefore, accuracy is less than in palpable lesions when sestamibi breast imaging is performed with current gamma camera technology. Our negative predictive value in mammographic lesions is still 94%. The overall accuracy in our first 100 patients exceeds 93%.

Sestamibi breast imaging is not without its pitfalls and limitations. Falsely positive ^{99m}Tc -MIBI uptake occurs in benign hypercellular breast lesions and inflammation. An occasional benign breast abnormality will have the propensity to grow and, therefore, require excision (Fig. 5). Mild, diffuse increases in breast activity can be seen just prior to the onset of menses, especially in women under the age of 30 (Fig. 6). The greatest limitation of prone breast imaging with ^{99m}Tc -MIBI is the resolution of conventional gamma cameras. Falsely negative sestamibi breast imaging most frequently occurs in breast lesions less than 8 mm in diameter. Medially placed lesions may also create some difficulty, as they are farther away from the detector surface with more interposed breast tissue. This can lead to an insufficient lesion-to-background count ratio for detection of the abnormality. Obtaining a complete patient history (Appendix B) and reviewing the patient's mammograms prior to initiating sestamibi breast imaging may help limit false negative and false positive results.

CLINICAL ROLES OF BREAST SCINTIGRAPHY

Improved access and use of mammography, increased awareness and use of breast self-examination and the true increase in breast cancer incidence have resulted in an increase

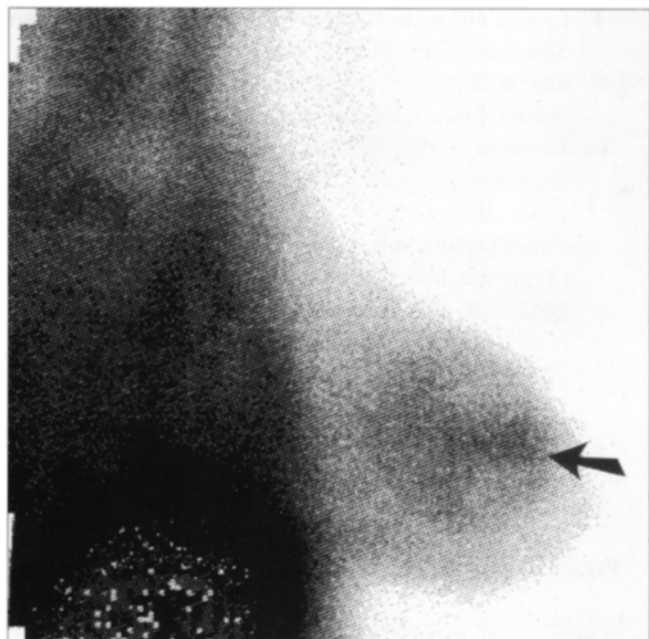


FIGURE 5. Sestamibi accumulated avidly throughout a smoothly marginated mass (arrow) in a 47-year old female with a rapidly growing tumor in the right breast. Surgical removal demonstrated a benign systocarcoma phyllodes. This hypercellular benign tumor does not have the propensity to spread like breast cancer but will recur if incompletely resected.

in diagnostic dilemmas confronting physicians caring for women. Sestamibi breast imaging's role will not be in supplanting conventional film-screen mammography and breast examination, but in providing adjunct diagnostic information. In the borderline abnormal breast examination or marginally abnormal mammogram, sestamibi breast imaging can arbitrate the need for and the location of appropriate biopsy. Mammographically dense breast tissue can be evaluated easily with sestamibi breast imaging, especially when evaluating a palpable abnormality. Breast-conserving surgery has a higher local recurrence rate than the more extensive modified radical mas-

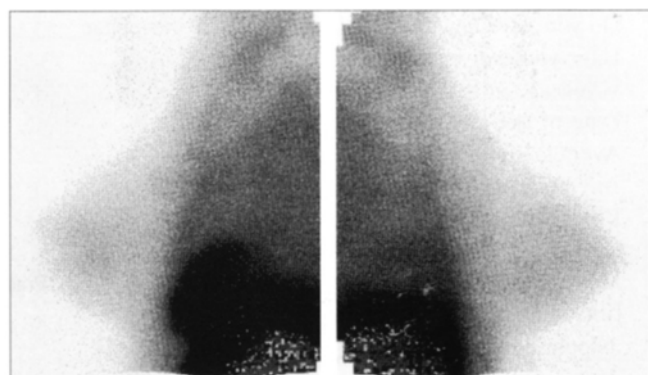


FIGURE 6. Diffuse sestamibi uptake in a 38-year old female undergoing sestamibi breast imaging due to a mammographic abnormality of the right breast. Imaging was done two days prior to the onset of menses. Mild diffuse, bilateral increased sestamibi uptake can be seen in premenopausal women, especially those who experience tender breast swelling prior to menstruation.

tectomy (15), and radiation therapy frequently creates breast tissue which is difficult to evaluate both by examination and mammography (16). Sestamibi breast imaging can provide the first evidence of recurrence in this group of patients. Sestamibi breast imaging provides solutions to the diagnostic dilemmas in evaluating breast abnormalities.

With the expansion of treatment options for breast cancer, the greatest future role for sestamibi breast imaging is to assist treatment planning. As breast-conserving surgery continues to become more prevalent, complete noninvasive staging of the breast neoplasm will become important. Chemotherapy administered prior to surgery allows breast conservation in a far greater number of women and may improve survival from breast cancer even in advanced stages (17). The application of presurgery chemotherapy precludes staging based upon surgical results.

Sestamibi breast imaging can aide evaluation of nodal metastases and multicentric and multifocal breast cancers. Additionally, sestamibi breast imaging can guide a confirmatory biopsy, avoiding full surgical exploration. Sestamibi breast imaging provides a guide in the treatment of breast tumors.

OTHER RADIOPHARMACEUTICALS

Breast tumor scintigraphy was first performed with ^{201}Tl . Thallium breast imaging has excellent sensitivity and specificity and is comparable to that obtained with sestamibi. The main disadvantage of using ^{201}Tl for breast scintigraphy was the inability to administer more than 3–5 mCi ^{201}Tl due to radiation dosimetry. Technetium-99m-MIBI has largely replaced ^{201}Tl for nuclear breast imaging because of its superior imaging characteristics. A head-to-head comparison of sestamibi and thallium for breast imaging suggests that the specificity with ^{201}Tl was slightly higher but sestamibi breast imaging had better sensitivity in the detection of breast cancer. Visualization of nonpalpable axillary nodal metastases is also better with $^{99\text{m}}\text{Tc}$ -MIBI than ^{201}Tl (18).

Fluorine-18-labeled deoxyglucose (FDG) can be used to detect the elevated metabolic activity found in breast neoplasms. The sensitivity (96%) and specificity (100%) of FDG with PET is quite high (19). Axillary metastases have also been readily identified using FDG PET. Small published series have shown that FDG PET can readily differentiate benign from malignant lesions possibly eliminating the need for a biopsy. The results of these trials are very encouraging. The current cost of PET technology and FDG production may be too expensive for routine use in the diagnostic setting. Alternative imaging methods of FDG uptake in breast lesions are currently in development.

CONCLUSION

Sestamibi breast imaging is a valuable diagnostic tool, complementing conventional screening with breast examination and film screening mammography. Scintigraphy can play an important clinical role in evaluating breast abnormalities and determining the need for and location of biopsies. Breast

tumor scintigraphy has a promising future in diagnosing breast cancer and assisting in treatment planning.

ACKNOWLEDGMENTS

We thank our technologists for their careful diligence in obtaining high-quality breast scintigraphy: Joy Braley, Tessa Gavilan, Georgia Quirch, Julie Wucki and Tracey Zahn. We were members of two multicenter trials employing ^{99m}Tc -sestamibi for breast imaging sponsored by DuPont Radiopharmaceuticals.

APPENDIX A

- I. Patient preparation
 - A. Entirely remove all clothing above the waist.
 - B. Patient should put on two hospital gowns with the inner gown open in the front and the outer gown open in the rear.
 - C. The outer gown will be removed during imaging to allow positioning of the breast.
 - D. Standard history (Appendix B) and breast examination should be recorded prior to imaging.
 - E. Mammograms should be available for the interpreting physician for comparison.
- II. Radiopharmaceutical administration
 - A. 25 to 35 mCi of ^{99m}Tc -sestamibi are used.
 - B. Intravenous injection is performed in a foot vein. If unsuccessful the arm contralateral to the breast lesion can be used.
 - C. Prior to injection of the tracer, a butterfly is placed to avoid any subcutaneous infiltration.
- III. Positioning
 - A. The table and breast imaging overlay should be securely locked in place.
 - B. The detector head should be positioned close to the edge of the table to provide additional safety for the patient.
 - C. The patient should be positioned prone with the breast freely dependent from the table and avoiding any compression of the breast by the table edge.
 - D. The ipsilateral arm should be comfortably placed over the head with the axilla close to or touching the collimator face.
 - E. The head is turned away from the breast to be imaged.
 - F. The collimator face should be adjusted to touch the patient's side and arm.
- IV. Instrumentation and procedure
 - A. A 10% window centered at 140 keV.
 - B. High-resolution collimator.
 - C. 128 × 28 matrix.
 - D. Electronic magnification to allow complete visualization of the breast, anterior chest and axilla, but yet exclude as much heart and liver as possible.
 - E. Shield chest, abdominal organs or salivary glands, or remove them from the field of view.

- F. Lateral images are 10 min in length commencing 5 min after tracer injection.
- G. Start with the lateral image of the breast with the lesion followed by a lateral of the other breast.
- H. Five-min marker views of palpable breast abnormality are performed with a cobalt marker overlying the palpable abnormality.
- I. Following lateral images, anterior supine images of the thorax are obtained with both arms above the head. Both axilla and breasts should be included.
- J. A marker view with radioactive markers on the nipples provide anatomic localization.

APPENDIX B

Sestamibi Breast Imaging

Personal information

Name _____ Today's date _____
 Date of birth _____
 Medical record no. _____ Age _____
 Address _____ Home phone _____
 _____ Work phone _____
 Referring physician _____ Bra size _____
 (e.g. 34 C)

Medical information

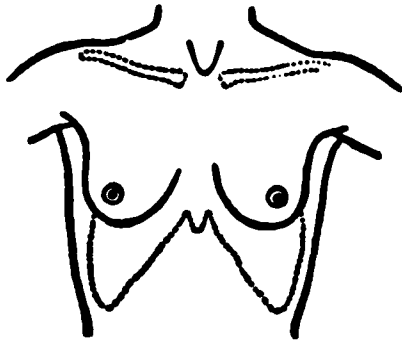
Height _____ Weight _____ Race _____
 Date of last mammogram _____ Where? _____
 Last breast exam by a physician _____
 Reason for current test _____

For each of the following questions, please circle YES or NO

Have you ever had BREAST cancer? Yes/No
 Family history of BREAST cancer? Yes/No
 Relation? _____ Age at diagnosis _____
 Other history of cancer? Yes/No
 If yes, type of cancer _____
 Do you have any medical problems? (e.g., hypertension)

 Current medications _____
 Do you have any allergies? Yes/No If yes, what _____
 Have you ever been pregnant? Yes/No
 If yes, age at first pregnancy _____
 Date of last menstruation _____
 Average number of days in cycle _____
 Any hormonal replacement therapy? Yes/No
 If yes, what? _____
 Oral contraceptives? Yes/No
 Menopausal status: Pre _____ Peri (recent) _____ Post
 (including post-hysterectomy) _____
 Nipple discharge? Yes/No
 If yes, type: Bloody _____ Clear _____ Other _____
 Which breast? Right _____ Left _____
 Have you experienced any of the following symptoms?
 Tenderness Yes/No Right _____ Left _____
 Cystic breast Yes/No Right _____ Left _____
 Lump or mass Yes/No Right _____ Left _____

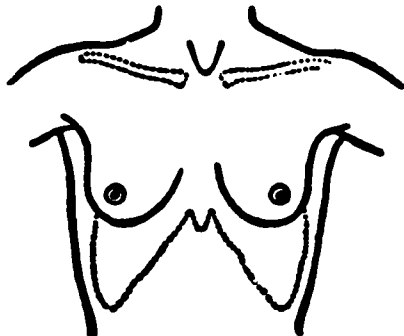
Indicate on the diagram below any previous breast surgery, treatments or injury. Indicate lumps, scars or moles on the diagram using the following symbols: (X = lump \ = scar ○ = mole). List dates for each marking.



FOR PHYSICIAN USE ONLY

If the patient has ever had breast surgery, treatment or injuries, mark the area of surgery and the year it was done. If patient has a palpable mass in her breast, mark the location and patient's position.

Date of breast examination: _____



Mammography results: Date(s) _____

REFERENCES

1. Smith RA. The epidemiology of breast cancer. In: Kopans DB, Mendelson EB, eds. *RSNA categorical course in breast imaging*. Oak Brook, IL: RSNA Publications; 1995;7-20.
2. Henderson IC. Breast cancer. In: Murphy GP, Lawrence W, Lenhard RE, eds. *American Cancer Society textbook of clinical oncology*, 2nd ed. Atlanta, GA: American Cancer Society; 1995:198-219.
3. Fletcher SW, Black W, Harris R, et al. Report of the International Workshop on Screening for Breast Cancer. *J Natl Cancer Inst* 1993;85:1644-1656.
4. Shapiro S. Screening: assessment of current studies. *Cancer* 1994;74(2 suppl):231-238.
5. Evans WP. Stereotaxic fine-needle aspiration and core biopsy. In: Kopans DB, Mendelson EB, eds. *RSNA categorical course in breast imaging*. Oakbrook, IL: RSNA Publications 1995:151-160.
6. Kuni CC. Mammography in the 1990s: a plea for objective doctors and informed patients. *Am Journal of Prevent Med* 1993;9:185-190.
7. Wackers FJ, Berman DS, Maddahi J, et al. Technetium-99m hexakis 2-methoxyisobutyl isonitrile: human biodistribution, dosimetry, safety and preliminary comparison to thallium-201 for myocardial perfusion imaging. *J Nucl Med* 1989;30:301-311.
8. Maublant JC, Zhang Z, Rapp M, et al. In vitro uptake of Tc-99m tetroxime in carcinoma cell lines and normal cells: comparison with Tc-99m-sestamibi and thallium-201. *J Nucl Med* 1993;34:1949-1952.
9. Khalkhali I, Mena I, Jouanne E, et al. Prone scintimammography in patients with suspicion of carcinoma of the breast. *J Am Coll Surg* 1994;178:491-497.
10. Burak Z, Argon M, Memis A, et al. Evaluation of palpable breast masses with Tc-99m-MIBI: a comparative study with mammography and ultrasonography. *Nucl Med Comm* 1994;15:604-612.
11. Kao CH, Wang SJ, Liu TJ. The use of Tc-99m-methoxyisobutylisonitrile breast scintigraphy to evaluate palpable breast masses. *J Nucl Med* 1994;21:432-436.
12. Khalkhali I, Cutrone JA, Mena IG, et al. Scintimammography: the complementary role of Tc-99m-sestamibi prone breast imaging for the diagnosis of breast carcinoma. *Radiology* 1995;196:421-426.
13. Lu G, Shih WJ, Huang HY, et al. Tc-99m-MIBI mammoscintigraphy of breast masses: early and delayed imaging. *Nucl Med Comm* 1995;16:150-156.
14. Taillerfer R, Robidoux A, Lambert R, Turpin, Laperriere J. Technetium-99m sestamibi prone scintimammography to detect primary breast cancer and axillary lymph node involvement. *J Nucl Med* 1995;36:1758-1765.
15. Borgen PI, Heerdt AS, Moore MP, Petrek JA. Breast conservation therapy for invasive carcinoma of the breast. *Curr Probl Surg* 1995;22:193-248.
16. Mendelson EB, Tobin CE. Imaging the breast after surgery and radiation therapy. In: Kopans DB, Mendelson EB, eds. *RSNA categorical course in breast imaging*. Oak Brook, IL: RSNA Publications; 1995:175-184.
17. Smith IE, Walsh G, Jones A, et al. High complete remission rates with primary neoadjuvant infusional chemotherapy for large early breast cancer. *J Clin Oncol* 1995;13:424-429.
18. Waxman AD. Thallium-201 and technetium-99m-methoxyisobutyl isoxaitrile (MIBI) in Nuclear Oncology. In: Sandler MP, et al, eds. *Diagnostic nuclear medicine*, 3rd ed. Baltimore, MD: Williams and Wilkins; 1996:1261-1274.
19. Adler LE, Crowe JP, Al-Kaisi NK, Sunshine JL. Evaluation of breast masses and axillary lymph nodes with [F-18] 2-deoxy-2-fluoro-D-glucose PET. *Radiology* 1993;187:743-750.

Please see end of second continuing education article, by Kane, et al., for CE test questions, answer sheet and answers to the June 1996 CE test.