

## Pulmonary Uptake of Technetium-99m-Labeled Sulfur Colloid Caused by Sustained-Release Niacin Therapy: Case Report

D. Haymond, L. Gordon, K. T. Cheng, and M. A. Fraley

Departments of Pharmacy and Radiology, Medical University of South Carolina, and Department of Radiology, Roper Hospital, Charleston, South Carolina

*In this report, we describe a potential drug interaction between niacin and the hepatic radiopharmaceutical technetium-99m-labeled sulfur colloid ( $^{99m}\text{Tc-SC}$ ). A patient was admitted with a diagnosis of acute hepatitis caused by her sustained-release niacin therapy. Diffuse lung accumulation of  $^{99m}\text{Tc-SC}$  was seen on her liver/spleen images. This is the first report of pulmonary localization of  $^{99m}\text{Tc-SC}$ , which is believed to be induced by the sustained-release niacin therapy for hyperlipidemia.*

*J Nucl Med Technol 1993; 21:221-223*

Technetium-99m-labeled sulfur colloid ( $^{99m}\text{Tc-SC}$ ) localizes primarily in three organs: the liver, the spleen, and the bone marrow. The mechanism of this localization is accepted as being phagocytosis of radiocolloid by cells of the reticuloendothelial (RE) system. Generally, diffuse lung uptake of radiocolloid is not visualized on normal images because only 1%-2% of the injected dose is phagocytized by the pulmonary RE cells (1). The following report describes a case of pulmonary uptake of  $^{99m}\text{Tc-SC}$ , which is believed to be induced by sustained-release niacin therapy for hyperlipidemia.

### CLINICAL PRESENTATION

A 45-yr-old white female presented to her physician complaining of malaise and mild anorexia. After her laboratory results revealed an aspartate aminotransferase (AST) of 488 U/l, an alkaline phosphatase (AP) of 246 U/l, and a lactate dehydrogenase (LDH) of 384 U/l, she was admitted into the hospital for further evaluation. The patient had a history of a left cadaver donor renal transplant, severe hypercholesterolemia, noninsulin dependent diabetes, and coronary artery stenosis, which had resulted in a coronary artery bypass graft one year prior to admission. Her medications at the time of this admission included diabinese, 250 mg/day; Imu-

ran, 100 mg/day; prednisone, 10 mg/day; dipyridamole, 75 mg/day; aspirin, 15 grains/day; and Niatrol, 1 g/day, which is an over-the-counter sustained-release niacin preparation manufactured by Leiner Nutritional Products, Torrance, CA.

On admission, her examination revealed a slightly cushingoid female with normal temperature, pulse, respiration, and blood pressure. She did not have fever, chills, or jaundice. The clinical diagnosis was acute hepatitis probably due to the sustained-release niacin therapy, which was discontinued after admission.

The patient's liver function test peaked three days after admission with an AST of 939 U/l, an alanine aminotransferase (ALT) of 470 U/l, an AP of 357 U/l, an LDH of 449 U/l, and a gamma glutamyl transpeptidase (GT) of 646 U/l. Her serum protein levels were lowest on Day 2 with an albumin value of 3.1 g/dl (normal: 3.6-5.1 g/dl), a globulin value of 1.6 g/dl, and a total protein value of 4.7 g/dl. Previous screening studies within the past year of this admission for the hepatitis B antibody and surface antigen, as well as for the hepatitis A and C antibodies, were all negative.

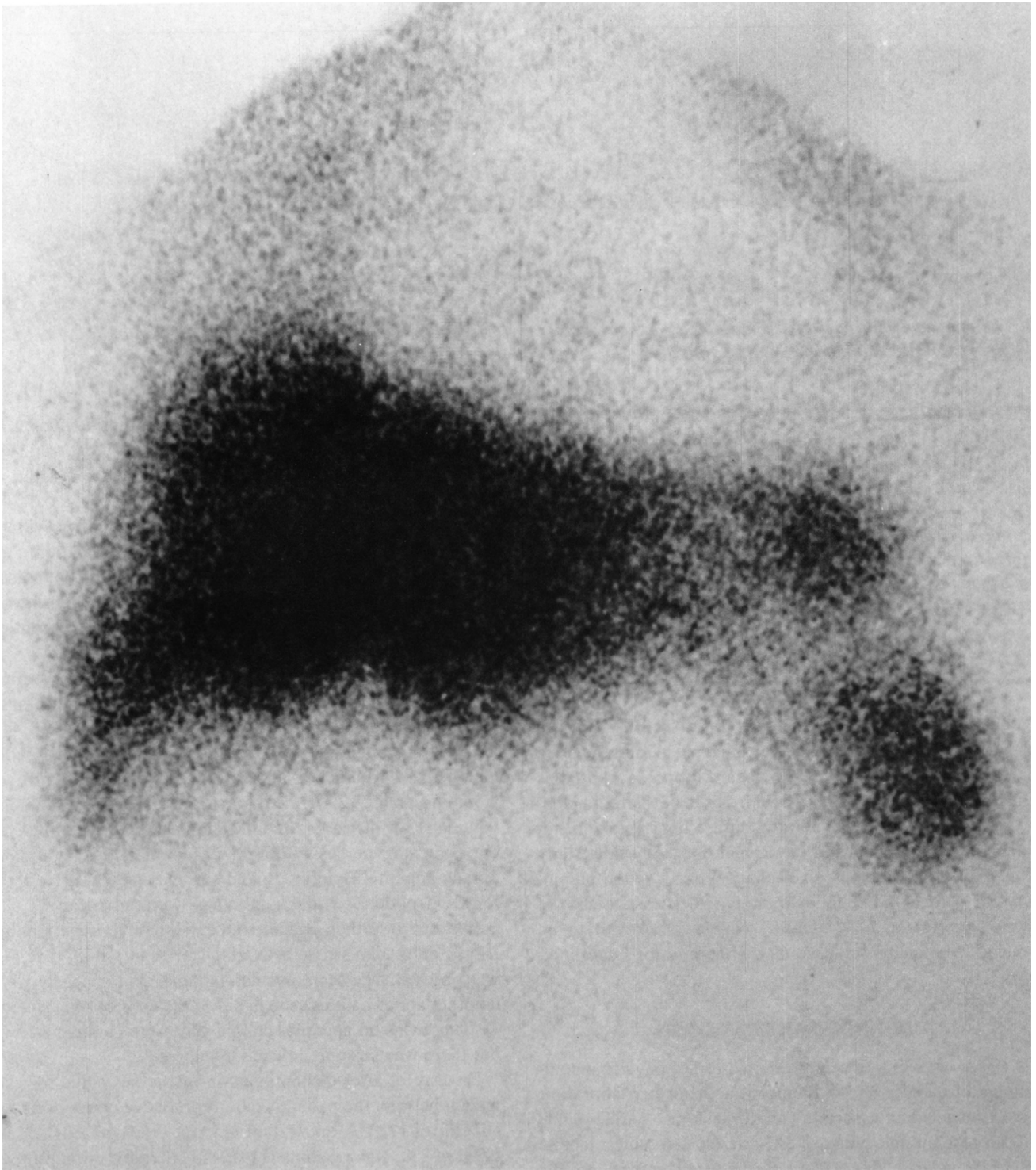
In order to further evaluate the patient's liver function, on Day 4 after admission, a liver/spleen scan with  $^{99m}\text{Tc-SC}$  was ordered. The scan revealed minimal splenomegaly with no other abnormalities seen in either the liver or spleen (Fig. 1). There was no apparent colloid shift to the bone marrow, but there was striking diffuse lung uptake.

On Day 6, after discontinuation of the sustained-release niacin therapy, the patient's laboratory values were down to an AST of 172 U/l, an ALT of 455 U/l, an AP of 291 U/l, an LDH of 238, and a gamma GT of 476 U/l. Her serum protein values, though still depressed, did show some improvement from her admission values, with an albumin of 3.4 g/dl, globulin of 1.9 g/dl, and a total protein of 5.4 g/dl. Thirteen days after discharge, the patient had a follow-up liver function test, and all values were back to normal.

### DISCUSSION

The cause of the patient's apparent pulmonary uptake of sulfur colloid appears to be related to the niacin therapy. The

For reprints contact: Kenneth T. Cheng, PhD, BCNP, Associate Professor, Nuclear Pharmacy/Radiology, Medical University of South Carolina, 171 Ashley Avenue, Charleston, SC 29425.



**FIG. 1.** Liver/spleen scan during the niacin-induced acute hepatitis condition, showing diffuse pulmonary uptake of  $^{99m}\text{Tc-SC}$ .

exact mechanism is not clearly understood. This iatrogenic alteration of the  $^{99m}\text{Tc-SC}$  distribution may be related to the acute hepatitis caused by the patient's niacin therapy.

The literature has suggested three possible mechanisms for the pulmonary uptake of  $^{99m}\text{Tc-SC}$ . The first is pathophysiologic; several of these causes are listed in Table 1 (2). The second is either the stimulation of alveolar RE cell activity by some compound, some of which are listed in

Table 2 (3), or the stimulation of RE cell migration to the lungs by estrogen degradation products (4). The third possible mechanism is direct pharmacologic interactions. These interactions include aluminum-hydroxide-containing antacids, which can cause particle size increases and secondary lung microemboli; chemotherapeutic agents, such as the nitrosoureas; and anesthetic agents like halothane. Both chemotherapeutic and anesthetic agents can cause a shift of

**TABLE 1. Pathophysiologic Mechanisms for the Alterations of <sup>99m</sup>Tc-SC Biodistribution**

Parenchymal Diseases
Amyloidosis
Mucopolysaccharidosis type II
Cirrhosis
Systemic infections
Malignancy

radiocolloid from the liver to the spleen and the bone marrow (5).

In this case, the patient's sustained-release niacin therapy was diagnosed as the cause of the acute hepatitis-like symptoms. The hepatotoxic effects of sustained-release niacin have been well documented (6,7). Most cases of hepatotoxicity from this cause are relatively benign and are resolved by discontinuation of therapy. There has been only one reported case of fulminant hepatic failure resulting in liver transplantation after high-dose sustained-release niacin use (8).

The actual mechanism responsible for the niacin-induced hepatotoxicity is unknown. It has been suggested, however, that this direct hepatotoxicity is dose dependent (9). Christensen, who did the original work comparing the side effects of crystalline niacin to those from sustained-release niacin, suggests that since sustained-release formulations are being absorbed from the gut more slowly, they affect liver enzymes for a longer period of time than do crystalline niacin formulations: therefore, the enzyme systems are inhibited from recovering adequately (10).

It is generally accepted that niacin is metabolized in the liver into three separate derivatives; N-methylniacinamide, N-methylated derivatives, and nicotinuric acid, which are

**TABLE 2. Alterations of <sup>99m</sup>Tc-SC Biodistribution Caused by Stimulation of Alveolar RE Cells**

Endotoxins
Attenuated bacteria
Triglycerides
Dextrose
Protein
Heparin
Thyroid
Yeast extracts

then excreted in the urine. Though this liver metabolism of niacin has been shown to cause a significant decrease in the clearance of some drugs, such as carbamazepine (another hepatically metabolized drug) (11), it is not clear that this hepatic metabolism of niacin is responsible for either its hepatotoxic effects or for the pulmonary uptake of <sup>99m</sup>Tc-SC seen in our patient.

## CONCLUSION

According to our literature review, this is the first report of sustained-release niacin therapy inducing a diffuse lung uptake of <sup>99m</sup>Tc-SC. Though a mechanism for this proposed drug interaction is not yet understood, we believe that literature on drug interactions should be actively reported so as to build up an accurate radiopharmaceutical/drug interaction data base. Knowledge of these potential interactions, such as that described in the above case, can help the clinician to better understand iatrogenic alterations of distribution and how they can potentially aid in the evaluation of the disease being investigated.

## ACKNOWLEDGMENT

The authors thank Mrs. Tracy Hackett for her help in preparing this manuscript.

## REFERENCES

1. Stern HS, McAfee JG, Subramanian G. Preparation, distribution, and utilization of technetium-99m sulfur colloid. *J Nucl Med* 1966;7:665-675.
2. Jacobson AF, Marks AM, Kaplan WD. Increased lung uptake on Tc99m SC liver/spleen scans in patients with hepatic venoocclusive disease following bone marrow transplantation. *J Nucl Med* 1990;31:372-374.
3. Sy WM, Malach M. Lung uptake on 99m technetium liver scan. *Chest* 1975;68:613-615.
4. Stadalnick RC. Diffuse lung uptake of Tc-99m sulfur colloid. *Semin Nucl Med* 1980;10:106-107.
5. Swanson DP. *Radiopharmaceuticals in medical imaging*. New York: MacMillan; 1990:467-468.
6. Hodis NH. Acute hepatic failure associated with the use of low-dose sustained-release niacin. *JAMA* 1990;264:181.
7. Etchason JA et al. Niacin-induced hepatitis: a potential side effect with low-dose time-release niacin. *Mayo Clinic Proceedings* 1991;66:23-28.
8. Mullin GE, Greenson JK, Mitchell MC. Fulminant hepatic failure after ingestion of sustained-release nicotinic acid. *Ann Intern Med* 1989;111:253-255.
9. Henkin Y et al. Rechallenge with crystalline niacin after drug-induced hepatitis from sustained-release niacin. *JAMA* 1990;264:241-243.
10. Christensen NA, et al. Nicotinic acid treatment of hypercholesteremia. *JAMA* 1961;177:76-80.
11. Bourgeois BFD et al. Interaction between primidone, carbamazepine and nicotinamide. *Neurology* 1982;32:1122.