

Elution Analysis and Normal Biodistribution of Technetium-99m HMPAO-Labeled White Blood Cells

C. H. Kao, Y. L. Wang, and S. J. Wang

Department of Nuclear Medicine, Taichung Veterans General Hospital, Taichung, Taiwan, Republic of China

The experience at the Taichung Veterans General Hospital with technetium-99m HMPAO-labeled white blood cells (Tc-WBCs) is reviewed. There were a total of 216 cases covering a broad range of clinical indications. The elution ratios in vivo and in vitro at 4 and 24 hr were calculated, the spontaneous elution was analyzed in 44 cases, and the normal biodistributions of the 216 Tc-WBCs were recorded for the first 40 min and at delayed intervals of 4 and 24 hr.

Although white blood cells (WBCs) labeled with indium-111 (^{111}In) complex have been used for years in the detection of infection, since the work of McAfee and Thakur in 1976 (1, 2), there has been a desire for technetium-99m ($^{99\text{m}}\text{Tc}$) labeled WBCs. This is because $^{99\text{m}}\text{Tc}$ is a widely available, generator-produced radionuclide, which is ideally suited for detection by a gamma camera. Attempts have been made for more than 15 yr to replace indium with technetium. In 1986, Peters et al. described the possibility of labeling WBCs with $^{99\text{m}}\text{Tc}$ -HMPAO, a new radiopharmaceutical, introduced for evaluation of regional cerebral blood flow (3). Due to its lipophilic character, this agent is able to diffuse through the cell membrane and apparently bind intracellularly. In order to avoid pitfalls in detecting inflammation with Tc-WBCs, 216 Tc-WBC studies were analyzed to determine their normal biodistribution patterns and characterize the elution results.

MATERIALS AND METHODS

The WBCs were labeled using a modified method (Fig. 1) (4,5). The labeling procedures were performed under aseptic conditions within a laminar flow hood. Thirty-six ml of whole blood were withdrawn from each patient, with 4 ml of ACD-A solution added as an anticoagulant. The whole blood was separated by differential-speed centrifugation, so that a concentrated pellet of WBCs was produced. Technetium-99m HMPAO was obtained by reconstituting a commercial vial of HMPAO (Ceretek, Amersham International Plc, UK); we

added 30 mCi/5 ml [$^{99\text{m}}\text{Tc}$]pertechnetate and mixed thoroughly. The resulting $^{99\text{m}}\text{Tc}$ -HMPAO had a radiochemical purity > 90%.

After incubating the WBC pellet with 10 mCi of $^{99\text{m}}\text{Tc}$ -HMPAO for 15 min at room temperature, the labeled WBCs were separated by high-speed centrifugation and resuspended in 5 ml of aseptic 0.9% saline for injection. The in vitro viability study of labeled WBCs by the trypan blue method was > 90%, and the recovery ratio (Fig. 1) (6) of labeled WBCs in whole blood at 40 min after intravenous injection was $42.0 \pm 4.7\%$ (mean \pm 1 s.d.). The labeling efficiency was $72 \pm 7\%$ (mean \pm 1 s.d.) (Fig. 1).

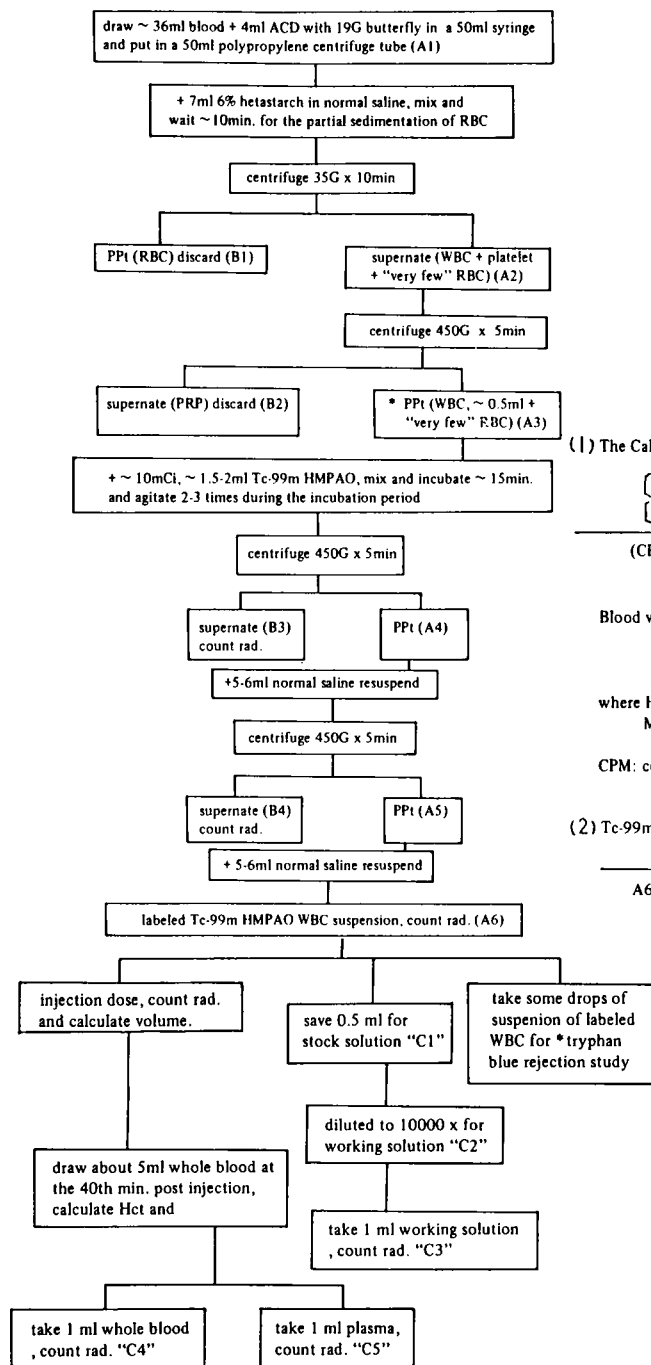
In 32 patients, the Tc-WBCs were injected with the patient in a supine position under the gamma camera, so that the activity in the right lung, liver, and spleen was recorded dynamically. A frame rate of 1 min/frame was used, and 40 frames were acquired. Time-activity curves (TACs) were generated using the mean counts from the regions of interest (of equal size) over the right lung, liver, and spleen.

All 216 patients received whole body scans (with a scanning speed of 40 cm/sec) and static spot images (800K counts/each view at 4 hr, 300K counts/each view at 24 hr) on a gamma camera (Elscint ECT 609R, Elscint, Haifa, Israel) with a low energy medium resolution collimator at 4 and 24 hr, respectively. The results of the imaging data were compared with clinical information, including bacterial culture, Gram stain, or a pathological report, and all images were reviewed in all areas where there was no known pathology. This was done to document normal distribution.

Grading was done using the following criteria for the intensity of the observable uptake: Grade 0 was equal to or less than the bone marrow uptake; Grade 1 was greater than the bone marrow uptake but less than the liver uptake; Grade 2 was equal to or greater than the liver uptake; and Grade 3 was equal to or greater than the spleen uptake. If the image was Grade 1 or higher, the images were considered to be positive for inflammation. Not all regions were imaged for each patient (Table 1) (7).

In our study, 44 of the 216 Tc-WBC cases were analyzed both in vivo and in vitro. At 4 and 24 hr, respectively, 5-ml blood samples were drawn from the patients and separated by high-speed centrifugation. The spontaneous elution ratio of Tc-WBCs in vivo was calculated by determining the ratio

For reprints contact: Chia-Hung Kao, MD, Department of Nuclear Medicine, Taichung Veterans General Hospital, 160 Taichung Harbor Road, Section 3, Taichung, Taiwan, Republic of China.



(1) The Calculation of Tc-99m labeled WBC recovery ratio at the 40th min. post I.V. injection:

$$\frac{\left[(\text{CPM of 1ml whole blood "C4"}) \times \text{blood volume} \times 100 \right] - \left[(\text{CPM of 1ml plasma "C5"}) \times \text{blood volume} \times (100 - \text{Hct}) \right]}{(\text{CPM of 1ml working solution "C3"}) \times 10000 (\text{dilution factor}) \times \text{the volume of I.V. injection}} \times 100\%$$

$$\text{Blood volume} = 0.236 \times H^{0.275} \times M^{0.426} - 1.229 (\text{male})$$

$$0.248 \times H^{0.275} \times M^{0.426} - 1.954 (\text{female})$$

where H = height in centimeters
M = body weight in kilograms

CPM: counts per minute, Hct: Hematocrit (%)

(2) Tc-99m HMPAO labeled WBC efficiency:

$$\frac{A6}{A6 + B3 + B4} \times 100\%$$

FIG. 1. The flow chart for labeling WBCs in our study, the calculations of recovery ratio at the 40th minute after intravenous injection of labeled WBCs, and labeling efficiency.

of the supernatant plasma counts to the whole blood sample counts (8).

The 0.5-ml samples of Tc-WBCs were suspended in vitro in 5 ml of 0.9% saline and 5 ml of platelet rich plasma (PRP), respectively, for 4 and 24 hr at 37°C in a water bath. The supernatant fluid and sedimentated blood cells were then separated by high-speed centrifugation. The spontaneous elution ratio of Tc-WBCs in vitro was calculated by determining the ratio of supernatant fluid counts to the total sample counts (8).

At the same time, the contents of the spontaneous elution at 4 and 24 hr were analyzed by using a combination of three thin-layer chromatography (TLC) systems. A 10-μl test sample was applied 2.5 cm from the base of the three chromatographic strips; two of which were ITLC/SG strips (2 × 20 cm) and one of which was a Whatman No. 1 strip (2 × 20 cm). Immediately after the sample was applied, one chromatogram using ITLC was developed in 2-butanone (MEK), and the other developed in 0.9% saline. The Whatman No. 1 strip was developed in 50% aqueous acetonitrile. After develop-

ment, the strips were dried and the radioactivity distribution was determined. The quantitative determination of radioactive components, such as reduced-hydrolyzed ^{99m}Tc , [^{99m}Tc]pertechnetate, secondary complex, and primary complex was made by counting the appropriate Rf value sites (9).

RESULTS AND DISCUSSION

TACs, recorded over the right lung, liver, and spleen for the first 40 min after injection of Tc-labeled WBCs, demonstrated rapid clearance of lung activity, with a half-time of 10.2 ± 2.1 min. Splenic activity increased monoexponentially with a time constant of $5.7 \pm 2.4\%$ /min, while hepatic activity, although generally minimal, reached a peak at 13 ± 5 min, then declined (Fig. 2). Significant Tc-WBC pooling in the spleen was seen on the later images. These findings may suggest that the lung hold-up was due to true margination in

TABLE 1. Normal Biodistribution Pattern of ^{99m}Tc -HMPAO-Labeled WBCs in Humans at 4 and 24 Hr

Organ	Grade of Uptake							
	0		1		2		3	
	4 hr	24 hr	4 hr	24 hr	4 hr	24 hr	4 hr	24 hr
Brain	100%	100%	0%	0%	0%	0%	0%	0%
Paranasal sinus	29%	73%	71%	27%	0%	0%	0%	0%
Thyroid	100%	100%	0%	0%	0%	0%	0%	0%
Heart	31%	93%	69%	7%	0%	0%	0%	0%
Lungs	77%	100%	23%	0%	0%	0%	0%	0%
Stomach	100%	100%	0%	0%	0%	0%	0%	0%
Gall bladder	100%	100%	0%	0%	0%	0%	0%	0%
Bowel	96%	18%	4%	44%	0%	35%	0%	3%
Kidneys	89%	96%	11%	4%	0%	0%	0%	0%
Urinary bladder	33%	64%	42%	19%	25%	17%	0%	0%

the pulmonary vasculature, rather than cell damage induced during labeling (11,12).

In general, the stability of WBCs labeled with ^{99m}Tc -HMPAO is lower than those labeled with conventional ^{111}In complex (6,8,10). This means that the bond between ^{99m}Tc -HMPAO and WBC is more easily broken than that between ^{111}In complexes and WBC.

In order to understand the difference in the biodistributions of WBCs labeled with ^{99m}Tc -HMPAO and those labeled with ^{111}In complex, we used a combination of three TLC systems to analyze the chemical compositions of the elutions, in vivo and in vitro. The contents of elutions inclusive of lipophilic primary complex, nonlipophilic secondary, free ^{99m}Tc , and reduced ^{99m}Tc , due to the dissociation of ^{99m}Tc -HMPAO-labeled WBC, may induce a different biodistribution from that of an intact ^{99m}Tc -HMPAO-labeled WBC and contribute to diagnostic errors.

Both saline and PRP have been used as the suspension medium in labeling WBC, in order to obtain more complete data in the human body under different labeling conditions. Hence, we calculated the elution ratios, both in vivo and in vitro, using saline and then PRP as suspension medium (Tables 2-4).

TABLE 2. The Elution Ratios of ^{99m}Tc -HMPAO-Labeled in Vivo and In Vitro at 4 and 24 Hr

Time (hr)	In vitro		In vivo
	Saline	PRP	
4	$17 \pm 4\%^*$	$22 \pm 4\%$	$12 \pm 2\%$
24	$36 \pm 6\%$	$40 \pm 6\%$	$22 \pm 6\%$

* Mean \pm 1 s.d., n = 44.

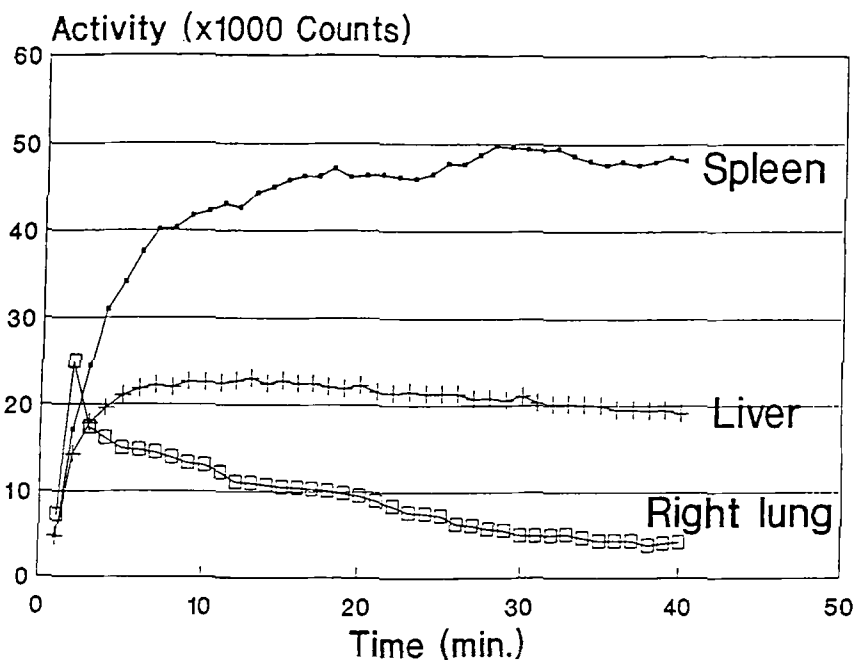


FIG. 2. Composite time-activity curves recorded over the right lung, liver, and spleen following injection of WBCs labeled with ^{99m}Tc -HMPAO over 40 min.

TABLE 3. Chemical Compositions of Spontaneous Elution in Saline at 4 and 24 Hr

Compositions	4 Hr	24 Hr
Primary complex	35.2%	32.4%
Secondary complex	51.8%	53.6%
[^{99m} Tc]pertechnetate	2.5%	2.7%
Reduced ^{99m} Tc	10.5%	11.3%

TABLE 4. Chemical Compositions of Spontaneous Elution in PRP at 4 and 24 Hr

Compositions	4 Hr	24 Hr
Primary complex	23.2%	13.2%
Secondary complex	63.6%	65.2%
[^{99m} Tc]pertechnetate	6.6%	13.4%
Reduced ^{99m} Tc	6.6%	8.0%

In 69% of the cases, activity was noted in the heart at 4 hr, but only 7% showed activity at 24 hr; this may represent excessive blood pooling activity at early normal biodistribution. Activity was also noted in the lungs of 23% of the cases at 4 hr, but no significant activity was noted in the lungs at 24 hr. This may be a transient margination of Tc-WBCs in pulmonary vasculature.

Another potential disadvantage is the renal excretion of ^{99m}Tc complex with kidneys (11% at 4 hr and 4% at 24 hr) and urinary bladder activity (42% + 25% = 67% at 4 hr and 19% + 17% = 36% at 24 hr), which may lead to a false diagnosis from the beginning of the study. In addition, the patients had unspecifically positive small and large bowel visualization, and the late intestinal excretion (only 4% at 4 hr but 44% + 35% + 3% = 82% at 24 hr) rendered the diagnosis more difficult at 24 hr. This phenomenon may be due to biliary excretion, which began at an earlier stage than 4 hr (6,8,10).

The potential disadvantages mentioned above may be mostly due to a secondary ^{99m}Tc complex and only slightly due to primary lipophilic complex or free [^{99m}Tc]pertechnetate (Tables 3 and 4), since no significant brain, thyroid, or stomach uptakes were demonstrated at the 4-hr and 24-hr normal biodistributions. Thus, the recommended imaging time for myocarditis is at 24 hr to avoid the blood pool in the heart chambers; for inflammatory lung disease, the recommended imaging time is at 24 hr to escape the margination of Tc-WBCs; and for abdominal or retroperitoneal inflammations, the recommended imaging time is at 4 hr, to avoid the late intestinal excretion.

Because the secondary complex is nonlipophilic and cannot pass through lipophilic WBC membranes, we think that most secondary complex may be due to the conversion of the primary complex, which has eluted from the labeled WBCs.

In addition, because the spontaneous elution was excreted through the genitourinary or gastrointestinal tracts in vivo, the calculated elution ratios in vivo were lower than those in vitro (Table 2).

CONCLUSION

As a potential cell labeling compound, ^{99m}Tc-HMPAO has a promising future, in comparison with ¹¹¹In complex, due to its high availability, better image quality, shorter acquisition time, and a lower radiation exposure to the patients for the diagnosis of inflammation. But the disadvantages of renal, biliary, and intestinal excretion of ^{99m}Tc complex; normal blood pooling at heart; and lung margination of Tc-WBCs at early imaging may lead to some diagnostic problems. Thus, the normal biodistribution patterns of Tc-WBCs in different organs, at 4 hr and 24 hr, must be considered and a time should be selected to avoid pitfalls while detecting inflammation with Tc-WBCs.

ACKNOWLEDGMENT

This work was supported in part by a grant, NSC80-0412-B-075a-13, from the National Science Council of the Republic of China.

REFERENCES

- McAfee JG, Thakur ML. Survey of radioactive agents for in vitro labelling of phagocytic leucocytes. 1. Soluble agent. *J Nucl Med* 1976;17:480-487.
- McAfee JG, Thakur ML. Survey of radioactive agents for in vitro labelling of phagocytic leucocytes. 2. Particles. *J Nucl Med* 1976;17:488-492.
- Ell PJ, Jarritt PH, Cullum I, et al. Regional cerebral blood flow mapping with ^{99m}Tc-labelled compound. *Lancet* 1985;11:50-51.
- Peters AM, Danpure HJ, Osman S, et al. Clinical experience with ^{99m}Tc-hexamethylpropylene-amineoxime for labelling leukocytes and imaging inflammation. *Lancet* 1986;25:946-949.
- Uno K, Imazeki K, Yoshikawa K, Arimizu N. Clinical use of technetium-^{99m} HMPAO labeled leukocyte for inflammatory imaging. [Abstract.] *J Nucl Med* 1987;28:648.
- Peters AM, Roddie ME, Danpure HJ, et al. Tc-^{99m}-HMPAO labelled leucocytes: comparison with In-111-tropolone labelled granulocytes. *Nucl Med Comm* 1988;9:449-463.
- Guze BH, Webber MM, Hawkins RA, Sinha K. Indium-111 white blood cell scan: sensitivity, specificity, accuracy, and normal patterns of distribution. *Clin Nucl Med* 1990;15:8-10.
- Becker W, Schomann E, Fischbach W, Borner W, Gruner KR. Comparison of Tc-^{99m}-HMPAO and In-111-oxine labelled granulocytes in man: first clinical results. *Nucl Med Comm* 1988;9:435-447.
- Neirinckx RD, Canning LR, Piper IM, et al. Technetium-^{99m} d,l-HMPAO: a new radiopharmaceutical for SPECT imaging of regional cerebral perfusion. *J Nucl Med* 1987;28:191-202.
- Mountford PJ, Kettle AG, O'Koherty MJ, Coakley AJ. Comparison of technetium-^{99m}-HM-PAO leukocytes with indium-111-oxine leukocytes for localizing intraabdominal sepsis. *J Nucl Med* 1990;31:311-315.
- Saverymuttu SH, Peters AM, Danpure HJ, Reavy HJ, Osman S. Lung transit of ¹¹¹-Indium-labelled granulocytes: relationship to labelling techniques. *Scand J Haematol* 1983;30:151-160.
- Peters AM, Savarymuttu SH, Bell RN, Lavender JP. Quantification of the distribution of the marginating granulocyte pool in man. *Scand J Haematol* 1985;34:111-120.