

# An Approach to Performing Hip Bone Scans on Children

Leo R. LaRocque

*Hartford Hospital, Hartford, Connecticut*

By using the high-resolution and pinhole collimators collectively in conjunction with a scintillation camera, one is able to obtain detailed scintiphotos of an anatomical area of interest. The pinhole collimator is especially important when visualizing small organs since it creates a magnified image with increased effective resolution. Because of the magnification or optical gain of the pinhole collimator, we are able to obtain images of children's hips, thyroids, magnified posterior fossa scans, etc.

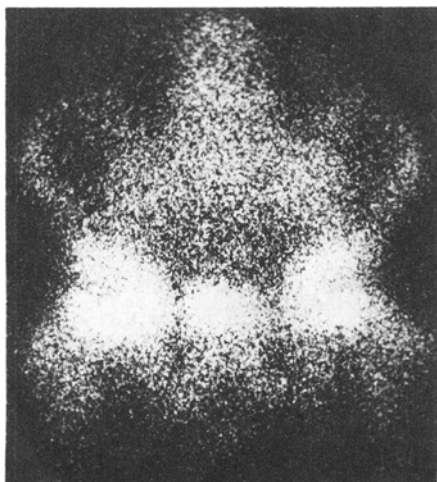
The use of  $^{99m}\text{Tc}$ -stannous polyphosphate agents as a diagnostic skeletal imaging radiopharmaceutical has been well documented in various nuclear medicine-related literature. Areas of abnormal accumulation of this agent may be observed in pathologic situations involving bone, i.e., metastatic malignancies to bone, traumatic fracture, osteomyelitis, localized increased osseous blood perfusion, areas of aseptic necrosis, etc. (1)

We at Hartford Hospital have been studying the usefulness of hip bone scanning on children with known or suspected Legg-Perthes disease. Legg-Perthes disease is a childhood hip disorder of unknown cause characterized by aseptic necrosis of the femoral head (ball of the ball and socket joint in the hip) probably due to compromise of the blood supply locally to the bone. Because of our location to a nearby children's hospital, we have been able to perform a variety of hip bone scans.

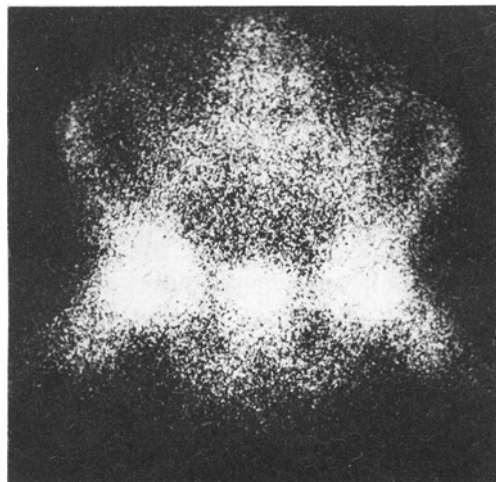
Although it still remains an investigational procedure, we have had gratification in using this technique for imaging the hips of children.

---

For reprints contact: Leo R. LaRocque, Dept. of Clinical Nuclear Medicine, Hartford Hospital, Hartford, Conn. 06115.



**FIG. 1.** Anterior projection of lower pelvis and hips taken with high-resolution collimator.



**FIG. 2.** Lateral frog projection of same anatomical area as shown in Fig. 1.

## Method and Materials

At the present time we have performed approximately 40 hip bone scans on children up to and including the age of 12. Twenty-five of these patients were documented as having Legg-Perthes disease on both radiographic and clinical grounds. The remaining patients had conditions that clinically simulated this same disease.

Photoscans were produced using the Searle 140-keV, high-resolution and pinhole collimators attached to a Searle Pho/Gamma III HP scintillation camera. Seventy-millimeter and Polaroid film was used for viewer acceptance.

All studies were performed with  $^{99m}\text{Tc}$ -stannous polyphosphate and the 25% photopeak window was used routinely in our clinical studies. We administer approximately 0.1 mCi/lb body weight to the child. Actual doses have ranged from 3 to 10 mCi. There is a delay of 2.5–3 hr postinjection before imaging begins.

Before imaging, the child is encouraged to urinate to avoid interference with visualization of the pelvis by excessive bladder activity.

The patient is then placed in the supine position on a table. Images of the lower pelvis and hips are taken with the high-resolution collimator positioned close to the pelvic area. These are performed in both the anterior and lateral frog positions (Figs. 1 and 2). There is no discomfort experienced by the child. Both scintiphotos are then taken at a preset count of 200K, which allows a direct comparison of relative osteogenic activity between the two hips.

The high-resolution collimator is then removed and replaced by the pinhole collimator. With the child remaining in the supine position, the end of the pinhole aperture is brought into close proximity to the hip to produce a magnified image of the proximal end of the femur and the acetabular region (Figs. 3 and 4). The right hip is imaged in anterior and lateral frog position at a preset count of 100K. The left hip view is taken at the preset time obtained from the first two images. Special care is taken to maintain the same geometry when visualizing the opposite hip.

## Results and Discussion

A typical pattern consisting of a zone of decreased activity in the femoral head anterolaterally was observed in all patients with Legg-Perthes disease. In Figs. 5 and 6 there is decreased activity in the right hip but even the high-resolution collimator images do not provide sufficient resolution to define anatomical details. Pinhole images (Figs. 7 and 8) show loss of femoral head activity laterally on the right and some associated reactive new bone

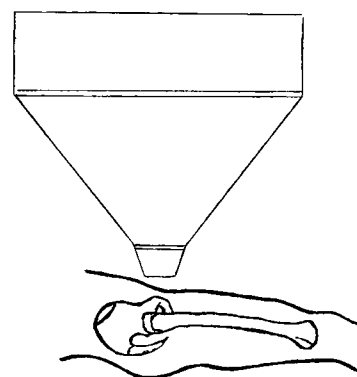


FIG. 3. Diagram of right lateral hip area showing position of pinhole collimator above hip.

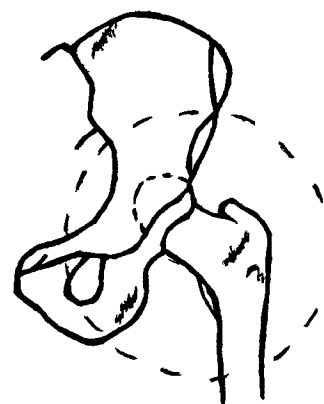

FIG. 4. Detail of area of interest.

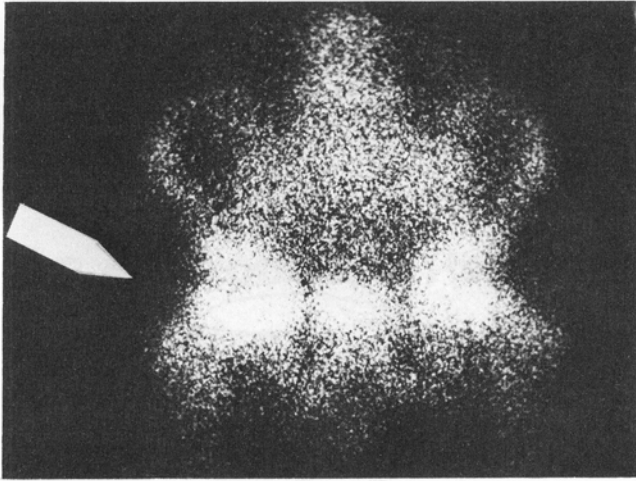
activity in the adjacent bone. The left hip (Fig. 9) appears to be normal.

However, since the majority of these patients are between the ages of 3 and 12 years, the epiphyseal centers are still open, and as a result of this there is more accumulation of this radiopharmaceutical present in the distal ends of the long bones.

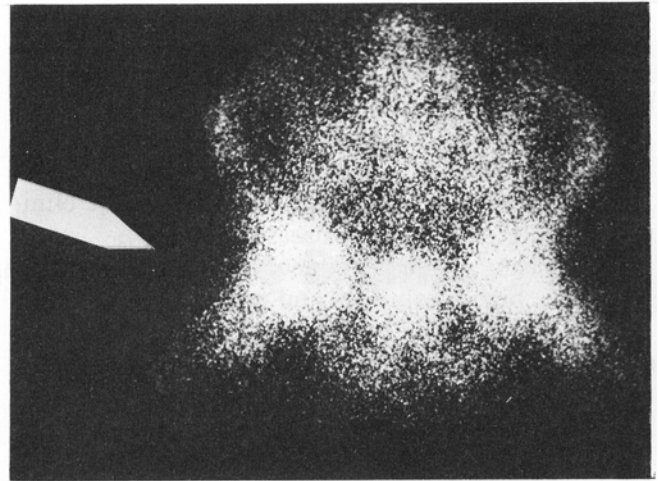
The pinhole collimator provides us with increased effective resolution when visualizing small organs positioned close to the collimator, e.g., thyroids, etc., thereby creating a magnified image in the crystal detector. This is referred to by Kenny (2) and others as optical gain. There is, however, a sizable decrease in sensitivity. The decrease in sensitivity does not seem to be a major problem now that high-photon-yield bone-scanning agents are available. A relative disadvantage is an increase in the patient motion artifact (this also is magnified by the pinhole collimator). The technologist must be alert and encourage cooperation to avoid this motion artifact.

## Summary

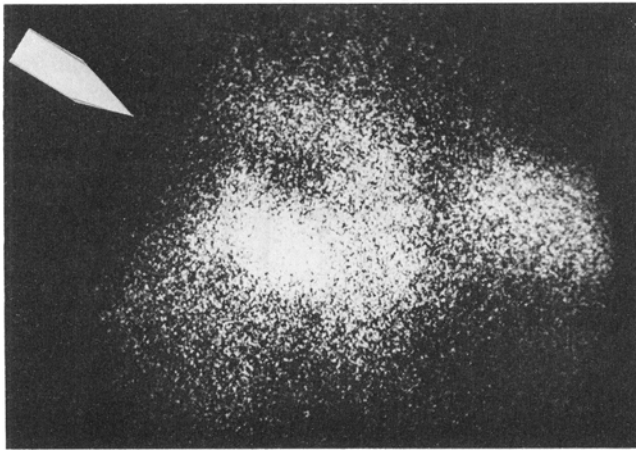
We feel that by using the high-resolution and pinhole collimators collectively with a scintillation camera in performing hip bone scans on children



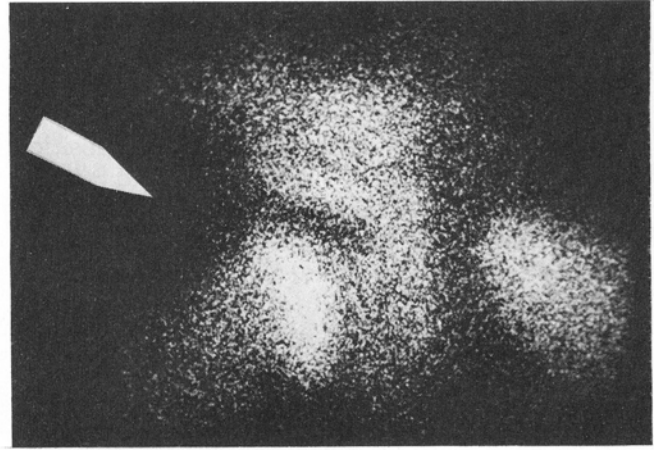
**FIG. 5.** Scintiphoto of right hip imaged with high-resolution collimator shows zone of decreased activity in head of femur (arrow).



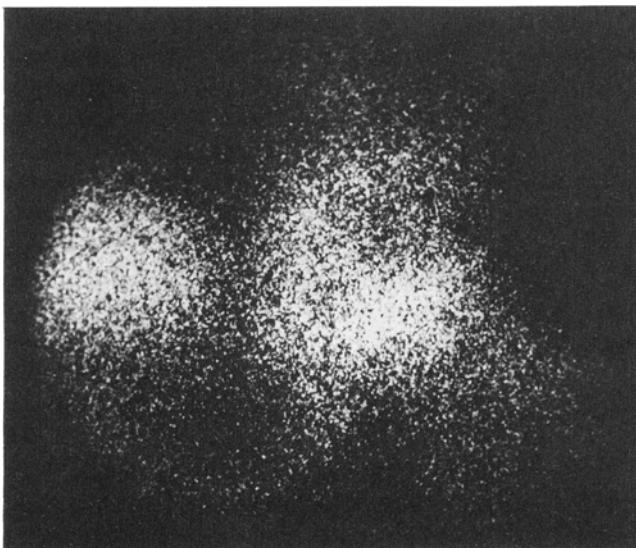
**FIG. 6.** Scintiphoto of same area as in Fig. 5 with patient positioned in lateral frog position. Arrow indicates zone of decreased activity.



**FIG. 7.** Scintiphoto of right hip imaged with pinhole collimator shows zone of decreased activity in head of femur (arrow).



**FIG. 8.** Scintiphoto of same area as in Fig. 7 with patient positioned in lateral frog position. Arrow indicates zone of decreased activity.



**FIG. 9.** Scintiphoto of left hip which appears to be normal.

and by using the technique described here, good scintiphotos may be obtained.

Because of the enlargement technique or optical gain of the pinhole collimator, areas of interest may be magnified, thereby producing good inherent resolution to aid the physician in diagnosing an abnormality or disease.

#### Acknowledgment

I wish to thank the staff at Hartford Hospital for their helpful criticism and analysis of this paper.

#### References

1. New England Nuclear: *The Stannous Polyphosphate Kit*. Catalog No. NRP-158
2. Kenney PJ: Collimation for rectilinear scanners and camera imaging equipment. *Semin Nucl Med* 3: 259-266, 1973