

Unusual Liver-Spleen Scan Findings

Haresh Majmundar, Royce A. Chrys, and Phillip Braunstein

University of California, Irvine Medical Center, Orange, California

Radioisotope scintigraphy is a widely used procedure for the evaluation of various forms of liver disease. It provides information regarding the size, shape, and position of the liver, as well as identification of any space-occupying lesions of the liver or spleen (1-4,6-8). The amount of radiocolloid clearance in liver, spleen and bone marrow depends on the distribution of radioactivity in reticuloendothelial (RE) tissue, the degree of liver disease and its effect on relative blood flow (1,9,10). We present an unusual liver-spleen scan demonstrating delayed clearance of blood-pool activity due to portal hypertension and consequent severe RE shift to spleen and bone marrow (1,5,11-13).

CASE REPORT

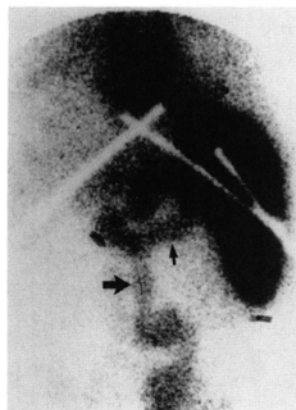
A 56-yr-old female with a 15-yr history of alcohol abuse presented for a liver-spleen scan. The patient had a longstanding history of alcoholic liver cirrhosis and recent worsening of hepatic function. A liver-spleen scan was performed to evaluate the extent of liver disease.

Fifteen minutes postinjection of technetium-99m- (^{99m}Tc) labeled sulfur colloid, the anterior image of the abdomen demonstrated severe reticuloendothelial shift to spleen and bone marrow with minimum uptake of sulfur colloid in the liver and an unusual display of vascular structures, most probably representing the splenic and superior mesenteric veins (Fig. 1). Forty-minute delayed images showed clearance of the sulfur colloid from the blood pool (Fig. 2).

DISCUSSION

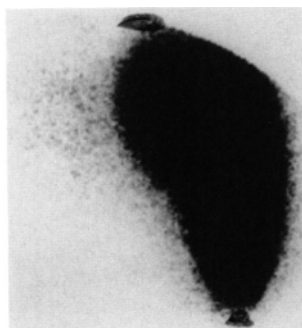
At our institution, we perform an average of three to five liver-spleen scans daily to evaluate the degree of liver disease in patients. About 40%–50% of these patients have alcoholic liver disease.

The early film shows vascular structures due to delayed blood clearance of radiocolloid by the reticuloendothelial system. This is a reflection of portal hypertension and demonstrates some of the collateral pathways of venous flow secondary to severe hepatic dysfunction.



initial

FIG. 1. Initial image of the abdomen 15 min postinjection of ^{99m}Tc -sulfur colloid demonstrates reticuloendothelial shift, splenomegaly, and extensive blood-pool activity resulting in visualization of vascular structures, including the superior mesenteric vein (large arrow) and splenic vein (small arrow).



40 min

FIG. 2. Delayed anterior image, 40 min postinjection, shows clearance of blood-pool activity with severe RE shift.

Reticuloendothelial shift is defined as the shift in distribution of radiocolloid from Kupfer cells in the liver to the spleen and bone marrow due to shunting of blood (1,8,9,12). Liver fibrosis increases resistance to flow producing portal hypertension. The fibrosis replaces liver sinusoids, which results in decreased hepatic transit. Blood concentration of sulfur colloid is thereby elevated for a period, allowing the spleen and bone marrow to extract more sulfur colloid than usual. Splenomegaly develops due to portal hypertension (1,8,9).

REFERENCES

1. Castell DO, Johnson RB. The ^{198}Au liver scan—an index of portal system collateral circulation in chronic liver disease. *New Engl J Med* 1966;275:188–192.
2. Bonte FJ, Bryan HL, Krohmer JS, Mize HL. Scintillation scanning of

For reprints contact: Haresh Majmundar, Dept. of Radiological Sciences, Univ. of California, Irvine Medical Ctr., 101 City Dr., Orange, CA 92668.

liver. *South Med J* 1966;53:754-763.

3. Krohmer JS, Bonte FJ. Scintillation scanning of liver physical basis. *AJR* 1962;88:269-274.

4. Wagner HM Jr, McAfee JG, Mozley JM. Diagnosis of liver disease by radioisotope scanning. *Arch Intern Med* 1986;107:324-334.

5. Johnson RB, Castell DO, Lukash WM. Liver scanning detection of collateral circulation by liver disease—a survey of 567 hepatic photoscans. *JAMA* 1969;207:528-538.

6. Bonte FJ, Krohmer JS, Elmendorf E, Presley ML, Andrews GJ. Scintillation scanning of liver. II. Clinical applications. *AJR* 1962;88:275-288.

7. Wellin FF, Sims JL, Cameron JR. Liver scanning, liver function tests. *JAMA* 1964;187:111-126.

8. Datz FL. *Handbooks in Radiology-Nuclear Medicine. GI and Hepatobil-*

iary Imaging. Chicago: Yearbook Medical Publishers; 1988:138-184.

9. DeNardo SJ, Bell GB, DeNardo GL, et al. Diagnosis of cirrhosis and hepatitis by quantitative hepatic and other reticuloendothelial clearance rates. *J Nucl Med* 1976;17:449-459.

10. Moreno AM, Burchell AR, et al. Portal blood flow in cirrhosis of the liver. *J Clin Invest* 1967;46:436-445.

11. Gourgoutis GD, Das G, and Lindsay M. Splenic uptake of ^{99m}Tc technetium-sulfur colloid as an index of portal hypertension. *Am J Gastroenterol* 1972;57:435-442.

12. Davis G, Alazaraki M, Taketa R, et al. Parameters of liver-spleen scans as an indication of portal hypertension. *Am J Gastroenterol* 1976;65:31-36.

13. Mettler FA. *Essentials of nuclear medicine imaging*, second edition. Orlando, FL: Grune and Stratton; 1986:206-220.