

Continuing Education

Lymphoscintigraphy: Internal Mammary and Iliopelvic Lymph Node Imaging

Susan M. Laffin and Clare A. Jennings

Department of Radiology, Harvard Medical School, Division of Nuclear Medicine, Dana-Farber Cancer Institute, Boston, Massachusetts

This is the fourth in a series of Continuing Education articles. After reading this article, the reader should be able to: 1) discuss the clinical applications of lymphoscintigraphy; 2) understand the imaging procedures for internal mammary and iliopelvic lymphoscintigraphy; and 3) recognize the potential technical pitfalls associated with these procedures.

One of the major difficulties facing the clinician is the early detection of neoplastic involvement of inaccessible lymph nodes in patients with malignant disease. The first modern attempt to visualize the lymph system used a procedure known as contrast lymphangiography. However, as this technique requires intralymphatic injection of a radiopaque contrast agent, it has limitations in patients (a) allergic to the contrast material; (b) with underlying pulmonary disease; and (c) with lymphedema.

Computed tomography (CT) is a useful aid in assessing diseased lymph nodes; however, this technique has not proven to be an optimal method for assessing sites of early microscopic lymph node involvement by tumor.

Lymphoscintigraphy, a noninvasive, safe, and reproducible technique, has been used to define lymphatic channels and lymph nodes for almost 30 years. When properly performed, lymphoscintigraphy provides key information about lymphatic drainage patterns as well as the location of lymph nodes. The clinical results can vary, however, depending upon (a) injection technique; (b) imaging procedure; and (c) image interpretation.

This article will focus on these aspects of the results for two specific lymph node groups, the internal mammary and the iliopelvic lymphatics, nodes which are of prime interest in the oncology population.

INTERNAL MAMMARY LYMPHOSCINTIGRAPHY

Injection Technique

Selection of the precise location of the injection site is extremely important in order to allow adequate lymphatic uptake and subsequent visualization of the internal mammary chain. We recommend a subcostal injection, 3 cm inferior to the xyphoid process and 1–2 cm medial to the midclavicular line (1).

The patient is positioned in the supine position with arms placed by the side. Using a 1.0-ml tuberculin syringe with a 22-gauge, 1.5-in. needle, 1.0 mCi of ^{99m}Tc antimony trisulfide colloid* in a volume preferably < 0.2 ml is injected just anterior to the posterior rectus sheath. The syringe is held at approximately a 45° angle from the horizontal plane, pointed toward the axilla of the side to be studied. Tension should be applied to the patient's skin with the free hand to control the depth of injection.

One key ingredient for a successful injection is a cooperative, relaxed patient; a tense patient with rigid abdominal muscles will be difficult to inject. In the relaxed patient, the technologist performing the injection will experience the tactile sensation of an elastic resistance when the posterior aspect of the rectus sheath is reached; the depth of this structure will, of course, vary from patient to patient.

Injection Assessment

Immediately after tracer administration, the injection site is imaged to confirm that the correct depth has been achieved (2). Using a low energy all-purpose parallel-hole collimator, an anterior image is obtained for 100,000 counts. For the cross-table lateral image, the supine patient is asked to bring the arm on the side of interest above the head. A radioactive point source is then held at the skin surface directly over the injection site and a second 100,000 count image is obtained (Fig. 1).

The anterior image should be evaluated for both the shape of injectate distribution and the degree of dispersion. Ideally,

For reprints contact: Susan M. Laffin, Division of Nuclear Medicine, Dana-Farber Cancer Institute, 44 Binney Street, Boston, MA 02115.

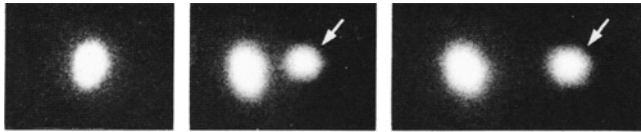


FIG. 1. The anterior image (left) demonstrates sharp, well defined, collection of radioactivity. The center image shows separation between the skin marker (arrow) and injectate on cross-table lateral view. The right-hand image demonstrates falsely increased separation between skin marker and injectate when lateral view is performed in the decubitus position.

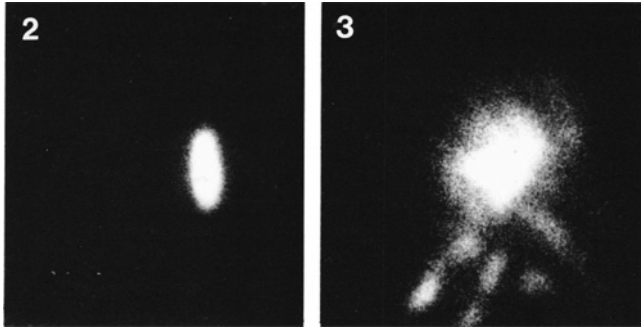


FIG. 2. Anterior view of injection site demonstrates ovoid activity, indicating an optimal injection (2).

FIG. 3. Anterior view of injection site after intraperitoneal administration of radiocolloid (2).

the injectate has been deposited at the correct depth if the image shows a sharp, ovoid configuration. The shape of the injectate can normally vary, however, from a vertical ellipse, to a circle, to an ellipse positioned horizontally (Fig. 2).

The cross-table lateral view is of prime importance to show a visible separation between the radioactive skin marker and the injectate denoting an optimal injection. If the marker and

injectate overlap, a subcutaneous injection should be suspected.

One potential problem is that of injecting the material too deeply into an intraperitoneal location. Typically, this is seen on the image as a region of dispersed tracer (Fig. 3).

To confirm the suspicion of a suboptimal injection, an anterior view of the thorax at 60 min with a 50 μ Ci cobalt-57 (^{57}Co) disk marker positioned at the sternal notch is obtained for 100,000 counts or 10 min, whichever is shorter. If no lymph nodes are seen on this image, a second, deeper injection is administered.

The patients tolerate the injection procedure well, commenting only upon the slight discomfort of the needle stick. On occasion they comment on an awareness of a mild burning sensation associated with the injection, which lasts between 5–10 sec.

Imaging

Patients are imaged 3 hr after injection. At this time, the following five 100,000 count images are acquired:

1. An anterior view with a sternal notch ^{57}Co marker in place.
2. An anterior view with sternal notch, midsternal, and xyphoid ^{57}Co markers in place (Fig. 4).
3. An anterior image with the three ^{57}Co markers in place along with markers denoting the costochondral junctions of the first four ribs.
4. & 5. Thirty degree slant-hole collimator images with the three ^{57}Co markers in place. The two slant-hole collimator images are acquired (a) directed to the right side of the patient (and without moving the patient or camera head, rotating the collimator 180°), and (b) directed to the left side of the patient. A "double exposed" film is therefore obtained (Fig. 5) (3). The slant-hole images were stored on the computer for depth determination (4).

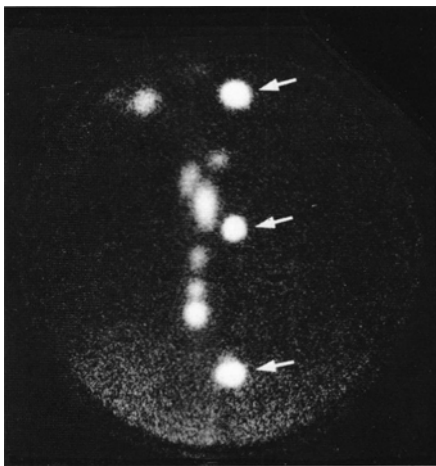


FIG. 4. Anterior view with sternal notch, mid-sternal, and xyphoid ^{57}Co markers denoted by arrows.

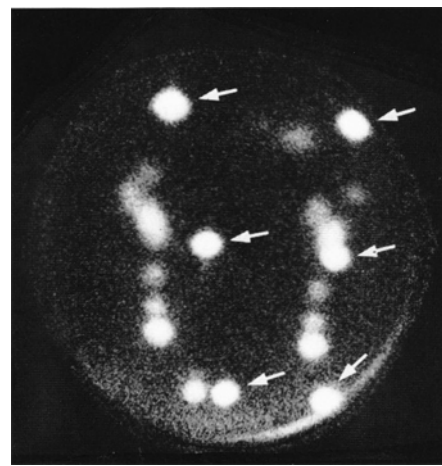


FIG. 5. Thirty degree slant-hole image; double exposure of two 100,000 count slant-hole images. Cobalt-57 markers are noted (arrows).

LYMPHOSCINTIGRAPHY-INTERNAL MAMMARY

NAME _____ DATE _____ AGENT _____

NUMBER _____ AGE _____ SIDE: RIGHT _____ LEFT _____

ROUTE _____ CROSSOVER _____ PLANNING DATE _____

CROSSOVER LOCATION _____ PHYSICIAN _____

TYPE OF SURGERY _____ DATE _____

AXILLARY SAMPLE ____ / ____ +

Right Breast Left Breast

ANTERIOR

Sternal Notch Marker: _____

DISTANCE (cm)

NODE	SIDE	BELOW SN	FROM MIDLINE	DEPTH	INTERSPACE	RIB

FIG. 6. Patient data form.

TABLE 1. Questions for Patients Undergoing Internal Mammary Lymphoscintigraphy

1. What type of breast surgery did you have? (lumpectomy, biopsy, or mastectomy)
2. What was the date of surgery?
3. Using a simple diagram, please indicate where on your breast the lump appeared.
4. Were any lymph nodes removed from under your arm (axillary sampling)? How many nodes were removed? Do you know the status of these lymph nodes? How many contained tumor cells?
5. Have you started chemotherapy or radiotherapy?

Image Interpretation

Patient History. Taking a patient history is important to help assess internal mammary lymph node status. The relevant questions to ask are found in Table 1; the information is record-

ed on a worksheet (Fig. 6).

For instance, knowing what type of surgery was performed, and when it occurred, will aid in evaluating the internal mammary lymph node scan. If the lymph node study is performed within the first 3–4 weeks after mastectomy (as opposed to lumpectomy or biopsy), it can result in a false-positive study because surgical debris present after extensive surgery can block tracer flow to the internal mammary lymph nodes. Radionuclide lymphoscintigraphy cannot differentiate between surgical debris and tumor invasion of the nodes.

Knowing in which quadrant of the breast the tumor first presented allows some prediction as to the pathway of lymphatic drainage. For instance, if a patient had an upper-outer or lower-outer quadrant breast lesion, the internal mammary lymph nodes would be less likely to be involved by tumor. Conversely, if a patient had an upper-inner or lower-inner quadrant lesion, the internal mammary lymph nodes would be more likely to be involved by metastatic disease.

Scintigraphic Pattern. As might be suspected, lymphoscin-

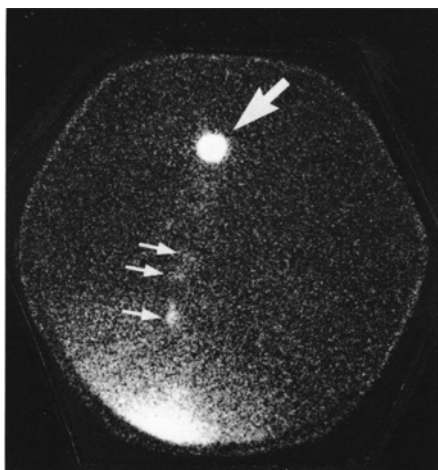


FIG. 7. Abnormal internal mammary study revealing diminished uptake along the nodal chain (70).

tigraphic results vary widely among patients. The most frequently asked question is how to determine a normal from an abnormal internal mammary study. In most cases this can be done quite easily.

As the image of all of the lymph nodes in the chain is examined, the relative intensity of each node should be noted. In general, the nodes closest to the injection site are a bit "brighter" than those at the level of the sternal notch, but there is not a great deal of variation in intensity between the proximal and distal aspects of the chain. If the chain is obstructed along its path, the radiocolloid will advance poorly beyond this point. If tumor cells have infiltrated the chain, diminished uptake of radiocolloid in the involved nodes will be noted (Fig. 7). We agree with Ege (1) that in order to best evaluate nodes for the presence of tumor, *both* sides should be injected sequentially (each injection followed by a 3-hr delay before imaging) and the relative intensities and patterns of radiocolloid uptake compared between the two lymphatic chains.

Scintigraphic Variations. In most cases, patients demonstrate two separate internal mammary lymph node chains, one on each side of the sternum. An uncommon finding noted in about 10%–20% of patients is a normal pattern of cross drainage to the opposite side of the sternum (Fig. 8) (1,4).

Clinical Application

A joint effort between nuclear medicine and radiation therapy services in our hospital has offered a team approach in dealing with breast cancer patients. This effort has produced a computer program that defines the position of the lymph nodes in three dimensions, i.e., the number of lymph nodes, their relationship to the chest wall, and their distance from the midline (3).

In the three-field radiation therapy technique, the tangential fields for breast cancer patients generally include the lymph nodes from the second through the fifth intercostal spaces. By knowing exactly where the internal mammary lymph nodes are in space, it is possible to deliver radiation optimally to these structures while decreasing the radiation exposure of normal tissue.

ILIOPELVIC LYMPHOSCINTIGRAPHY

In patients with genitourinary cancers, it is important to know the status of the ilio pelvic lymph nodes before therapy. Computed tomography is regarded as a sensitive and accurate test for defining the presence of bulky nodal disease during staging for cancer. For imaging lymph nodes, however, CT has two major drawbacks: (a) the test cannot identify small foci of intranodal tumor in normal size nodes; and (b) sufficient retroperitoneal fat is required to allow differentiation between normal retroperitoneal structures and nodal metastases.

Iliopelvic lymphoscintigraphy offers a physiologic method for visualizing pelvic nodes, particularly the internal iliac lymph node chain, which is often not visualized during contrast lymphangiographic studies. The results of ilio pelvic lymphoscintigraphy can influence both the type of therapy and the extent of treatment to be employed.

Injection

The patient is positioned in the lithotomy position on a standard gynecology examining table. The perianal region is aseptically cleansed by using an iodine solution. The skin is allowed to dry, and two separate injections of 1.0 mCi each of ^{99m}Tc antimony trisulfide colloid are administered using a 1.0-ml tuberculin syringe with a 22-gauge, 1.5-in. needle. The two injection sites chosen are at three and nine o'clock, just lateral to the anal margin. The needle is held parallel to the table top and is inserted to its fullest length into the ischio rectal fossa (5) (Fig. 9).

Patients tolerate this injection quite well; the initial needle stick is felt and they note a slight burning sensation when the radiopharmaceutical is given. Local anesthesia is not needed.

Imaging

Images are obtained 3 hr after injection. The patient is asked to void before imaging. Using a low energy all-purpose parallel-hole collimator, a 300,000 count anterior pelvic image is obtained first (Fig. 10). The injection sites should be either excluded from the field of view or shielded with lead. Subsequent

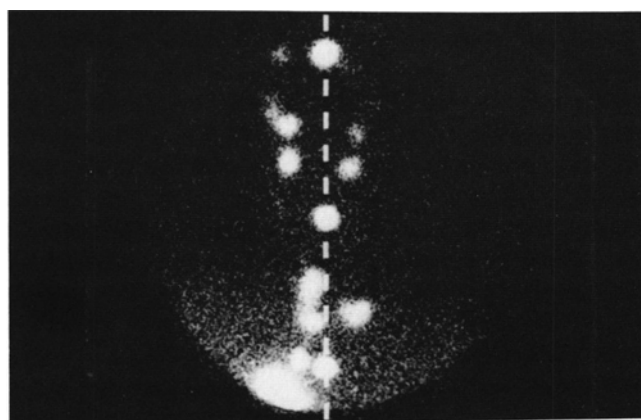


FIG. 8. Demonstration of crossover. After a single injection, lymph nodes appeared on both sides of the sternum. Midline defined by three ^{57}Co markers and dotted line.

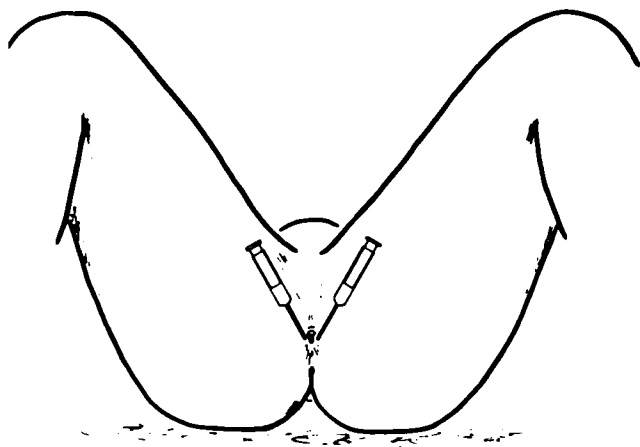


FIG. 9. Perianal injection sites for iliopelvic lymphoscintigraphy (5).

images are collected for 200,000 to 300,000 counts. Additional images routinely obtained include: (a) anterior abdomen (with the liver in the field of view); (b) posterior pelvis; (c) posterior abdomen; and (d) lateral pelvis. It is helpful to store digital images on a computer to allow later count thresholding when needed. This is especially important when the urinary bladder cannot be completely emptied.

Interpretation

A normal study will reveal symmetrical and uniform uptake of radiocolloid in both the internal and the common iliac nodes as well as in the para-aortic nodes to the level of the renal hila bilaterally (5). Less frequently seen are the pararectal, external iliac, and anterior pelvic lymph nodes.

An abnormal study appears as heterogenous nodal uptake of the tracer, or an asymmetric lymphatic chain. Total absence of tracer in a lymph chain or failure to fill the distal lymphatics also constitute an abnormal study, implying either intrinsic nodal disease or obstruction to the lymphatic flow (Fig. 11).

In the event of an abnormal study, it has been suggested that an additional injection be administered between the web spaces of the toes, or intradermally in the dorsum of the feet, to allow optimal visualization of the external iliac nodes (6). Images obtained after these additional injections can allow differentiation between nonvisualization of the distal lymphatics due to proximal tumor infiltration, and tumor infiltration within the entire lymphatic chain.

Clinical Application

Current imaging techniques for evaluating the iliopelvic nodes include both radiologic and radionuclide studies. The radiologic techniques, contrast lymphangiography, ultrasound, and computed tomography, are each associated with technical aspects which, on occasion, render these diagnostic tests less rewarding than anticipated. The radionuclide approach, iliopelvic lymphoscintigraphy, which is simple to perform and tolerated well by the patient, may offer the clinician the means to reliably evaluate what has been a relatively inaccessible lymph node group (7).

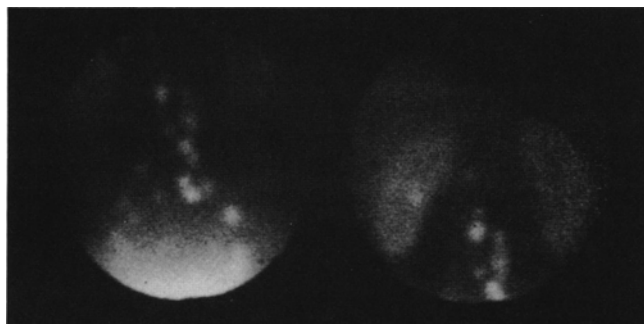


FIG. 10. A normal iliopelvic study (7).

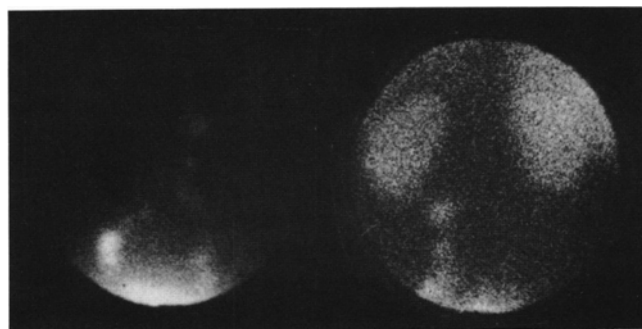


FIG. 11. Abnormal iliopelvic study demonstrating absence of radiocolloid to the level of the kidneys (7).

DOSIMETRY

A quantitative kinetic technique using a scintillation camera has been developed for investigating lymph drainage and the uptake in lymph nodes of ^{99m}Tc antimony trisulfide colloid injected subcutaneously (8). The estimated mean absorbed dose at the injection site based on this study was 35 rad/mCi. Assuming that a lymph node weighs approximately 1.0 g and that the percentage injected dose accumulated per node is 0.1% (an amount consistent with our experience [9]), Bergqvist et al. calculated a lymph node absorbed dose of 0.3 rad/mCi (8).

SUMMARY

Radionuclide lymph node imaging is a safe, simple, reproducible, and useful technique. It should be clearly understood, however, that no imaging test, including lymphoscintigraphy, may be able to define the smallest of micrometastatic tumor cells. However, this noninvasive and physiologic technique may offer the improved accuracy needed in the clinical setting of the staging and follow-up of the cancer patient.

ACKNOWLEDGMENTS

The authors wish to thank William Kaplan, M.D., for his editorial comments and Laurie Pugsley for her help in preparing this manuscript.

FOOTNOTES

*Cadema Medical, Middletown, NY.

REFERENCES

1. Ege GN. Internal mammary lymphoscintigraphy: The rationale, technique, interpretation and clinical application. A review based on 848 cases. *Radiology* 1976;118:101-07.
2. Dufresne EN, Kaplan WD, Zimmerman RE, et al. The application of internal mammary lymphoscintigraphy to planning radiation therapy. *J Nucl Med* 1980;21:697-99.
3. Siddon RL, Chin LM, Zimmerman RE, et al. Utilization of parasternal lymphoscintigraphy in radiation therapy of breast carcinoma. *J Rad Oncol Biol Phys* 1982;8:1059-63.
4. Kaplan WD, Andersen JW, Siddon RL, et al. Three dimensional location of internal mammary lymph nodes (IMLN) in patients undergoing radiation therapy: Implications for portal planning. *J Nucl Med* 1985;26:P65(A).
5. Ege GN, Cummings BJ. Interstitial radiocolloid iliopelvic lymphoscintigraphy: Technique, anatomy and clinical application. *Int J Rad Oncol Biol Phys* 1980;6:1483-90.
6. Ege GN. Augmented iliopelvic lymphoscintigraphy: Application in the management of genitourinary malignancy. *J Urol* 1982;127:165-69.
7. Kaplan WD. Iliopelvic lymphoscintigraphy. *Semin Nucl Med* 1983;13:42-53.
8. Bergqvist L, Strand SE, Persson B, Hafstrom L, et al. Dosimetry in lymphoscintigraphy of Tc-99m antimony sulfide colloid. *J Nucl Med* 1982;23:698-705.
9. Kaplan WD, Piez CW, Gelman RS, et al. Clinical comparison of two radiocolloids for internal mammary lymphoscintigraphy. *J Nucl Med* 1985;26:1382-85.
10. Kaplan WD. Internal mammary lymphoscintigraphy. In: Harris JR, Hellman S, Silen S, eds, *Conservative Management of Breast Cancer*. Philadelphia: JB Lippincott, 1983:189-200.