

---

# Continuing Education Series

---

## Principles of Instrumentation in SPECT

Robert L. Eisner

Emory University School of Medicine, Atlanta, Georgia

**This is the first CE article in a four-part series on single photon emission tomography (SPECT) imaging.**

*Nuclear emission tomography has rapidly gained acceptance as a viable clinical diagnostic tool. The challenge to the nuclear medicine technologist is to acquire a good working knowledge of the scientific principles. After studying this article, the reader should be able to discuss the technical issues of: 1) quality control; 2) filtering techniques; and 3) be able to identify acquisition related artifacts. A summary of new instrumentation for brain and elliptical tomography is presented as is a general discussion on system requirements for enhanced patient throughput.*

Over the past several years, there has been a dramatic increase in the routine use of tomographic procedures in the nuclear medicine department. The purpose of this paper is to present an overview of some of the important technical and scientific issues related to the use of this modality in the clinical setting. The basics of the tomographic approach are discussed followed by issues relating to center of rotation error, uniformity errors, filtering techniques, and 180° acquisition. They represent the framework of clinical application and image interpretation. These points are crucial and may cause confusion for many first time tomographic users. A summary of recent instrumentation developments in brain tomography will be discussed, followed by a basic discussion of elliptical rotation. Patient throughput issues and how they relate to the purchase of a tomographic system are also presented.

### BASICS

There are many types of nuclear tomographic systems. The tomographic procedures which we will discuss are those that satisfy the basic tomographic mathematics, whereby image data are acquired over at least a 180° arc about the patient to provide three-dimensional reconstructed images. Tomo-

graphic studies with seven-pinhole or rotating slant hole collimators obtain data over a more limited number of view angles (less than 180°) and the reconstructed images have been shown to be severely compromised by artifacts (1-2). Following an initial surge of interest in these limited angle tomographic techniques, all major manufacturers now sell and support equipment which rotate conventional large field of view Anger scintillation cameras about the patient and acquire data over an appropriate number of views. These systems provide a multitude of tomographic slices which are reconstructed from data obtained from one rotation about the patient. The data can be easily manipulated to obtain sagittal and coronal sections without the need for additional acquisitions. In addition, software is provided from which images can be produced at any obliquity. Such oblique angle reconstruction formats form the basis for evaluation of thallium-201 myocardial perfusion tomographic studies, where reconstructed slices are viewed in a coordinate system fixed to the heart.

Tomography provides clinical diagnostic advantages over conventional two-dimensional planar nuclear imaging with: increased contrast, absolute three-dimensional localization, cinematic display of rotating planar views which provides a pseudo three-dimensional effect that has been shown to be a useful tool for clinical diagnosis (3), and quantification in three-dimensions. Normal nuclear medicine planar images represent two-dimensional projections of three-dimensional objects. True quantification from these images is severely compromised from overlapping structure and background.

### TOMOGRAPHIC OVERVIEW

The tomographic system consists of a computer which is interfaced to and controls the rotational motion of the conventional gamma camera mounted on a rotating gantry. The tomographic process consists of calibration, acquisition, processing, display and review, and quantitation.

In addition to a basic understanding of standard nuclear medicine imaging techniques, good tomographic practice demands that the technologist understand the physics, mathematics, and

---

For reprints contact: Robert L. Eisner, Division of Nuclear Medicine, Emory University School of Medicine, 1364 Clifton Road, NE, Atlanta, GA 30322.

the fundamentals of good quality control. In nuclear emission tomography, there is much more operator interaction than there is, for example, in x-ray CT. The technologist must understand that rigid quality control of this system is an absolute necessity and must learn good tomographic procedures with the ability to recognize artifacts in the reconstructed images.

Most tomographic systems do not come with predefined clinical acquisition and processing protocols. The burden is on the clinical staff to decide on parameters such as the total acquisition time for the study, the number of views to be acquired, and the acquisition matrix size, i.e.  $64 \times 64$ ,  $128 \times 128$ , etc. Some helpful hints:

**Acquisition time.** As in any conventional nuclear medicine scan, the more statistics, the better the study. Consistent with patient comfort, allow as much time for the examination as possible.

**Number of views.** Theoretically, there is a well-defined relationship between the number of views needed to support a given tomographic resolution. An insufficient number of views results in a streak artifact pattern in the reconstructed image. (You can observe this structure in the reconstructed image of a point source acquired with 32 views over  $360^\circ$ .) Clinically, it appears that a minimum of 64 views acquired over  $360^\circ$  is sufficient to produce good quality tomograms.

**Acquisition matrix size.** The key factor is not whether  $128 \times 128$  is better than  $64 \times 64$ , but what the optimum pixel size is (in square millimeters). A good first approximation is that each pixel dimension (in millimeters) should be at least one-half the camera-collimator full width half maximum (FWHM) value. For almost all clinical tomographic studies, the system FWHM is no better than 12–16 mm, so that a pixel dimension of approximately 6–8 mm should be adequate. For high quality brain tomography, where the collimator can be placed close to the patient's head or for pediatric studies, it may be necessary to have a significantly smaller pixel size. For these studies, instead of increasing the pixel acquisition matrix size from  $64 \times 64$  to  $128 \times 128$ , a zoomed  $64 \times 64$  image can be acquired. The reason for shying away from  $128 \times 128$  acquisition for routine clinical imaging is that data so acquired require a fourfold increase in storage space and much longer processing times. Most importantly, the count density in the reconstructed slice is reduced by a factor of eight compared to  $64 \times 64$  (64 slices) which will have an adverse effect on perceived image contrast. The message is that it has not been shown that  $128 \times 128$  (128 slices) is better than  $64 \times 64$  (64 slices) for clinical imaging on standard field of view cameras with commercially available equipment.

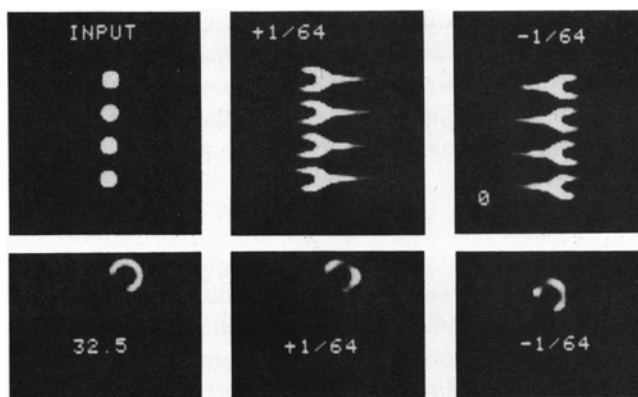
## QUALITY CONTROL

The next sections will deal with several fundamental topics in nuclear tomography. The focus will be on quality control procedures and the filtering techniques inherent in the reconstruction process. The artifacts in thallium-201 myocardial perfusion images, which result from inadequate attenuation and resolution corrections, are described.


## Center of Rotation

Our discussion will deal with systems in which a conventional gamma camera with attached parallel hole collimator rotates in a circular orbit about an object. The camera detector system rotates in a circular path about a point called the center of rotation. In order to perform the tomographic reconstruction process and to place the reconstructed image in a pixel array, it is necessary to know the exact pixel value of the center of rotation in this array. To do this, a point source is positioned anywhere inside the field of view of the camera system. Two  $180^\circ$  opposed views of the point source are acquired and the centroid of activity in the top view and in the bottom view are determined. The center of rotation is simply obtained by averaging these values. The exact procedure for collecting, maintaining, and checking specifications for adequate center of rotation values will vary depending upon the manufacturer; however, it is important that the operator recognize the image artifacts generated by an incorrect center of rotation value.

The effects of an incorrect center of rotation value in the tomographic reconstruction program are best isolated by performing  $180^\circ$  acquisitions and inspecting the resultant reconstructed images. Rather than doing the actual acquisition and processing, the results will be derived from computer simulations. The simulations, point sources and a thallium myocardium phantom, are acquired in a  $64 \times 64$  matrix with correct center of rotation value of 32.5. We have altered the value of the center of rotation by plus or minus one pixel and reconstructed the objects with the incorrect value of, in one case, 31.5 and in the other, 33.5 (Fig. 1A and B). In the case of the point sources, severe tuning fork distortion patterns are observed in the reconstructed images. A one pixel error in the value of the center of rotation causes a corresponding marked distortion of the reconstructed thallium uptake in the walls of the myocardium. A measure of this relative uptake is a key to clinical interpretation. Thus, an inadequate quality control procedure for center of rotation or misaligned system may ultimately alter the clinical interpretation of tomographic scans.



**FIG. 1.** Results of computer simulation study to show the effect of using an incorrect value of center of rotation on tomographic image quality. A) Four point sources. Tuning fork distortion pattern is evident in the tomographic reconstruction; B) Myocardium. Hot and cold spots are observed in the walls of the heart.

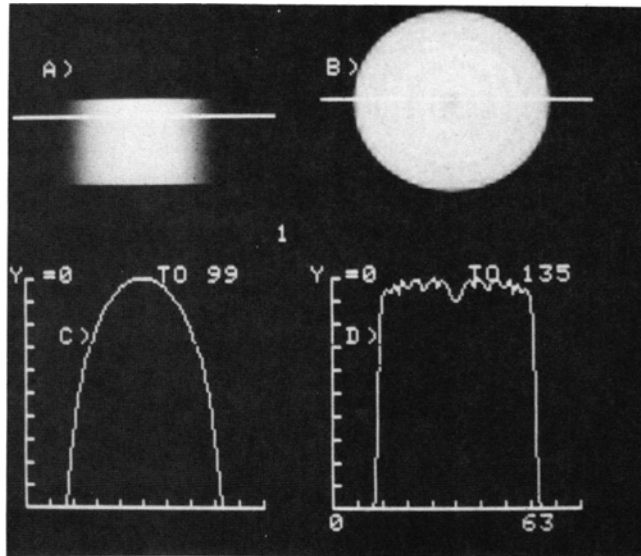


**FIG. 2.** Schematic representation of the rotating detector system. During one revolution a given projection bin maps out a circle at a well-defined distance from the center of rotation.

Center of rotation acquisitions must be performed on a routine weekly basis. The center of rotation value may have a dependence on the type of collimator, as well as on the rotational properties of a given collimator. These points should be checked. Manufacturers should provide software which automatically associates the correct value of the center of rotation with the appropriate patient acquisition.

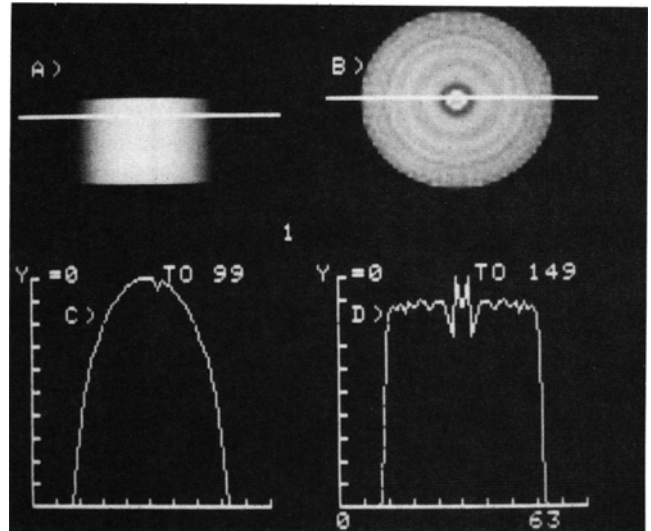
### Ring Artifacts: Causes and Cures

In the early days of x-ray CT development, it was shown that rotating detector systems were prone to creating ring arti-

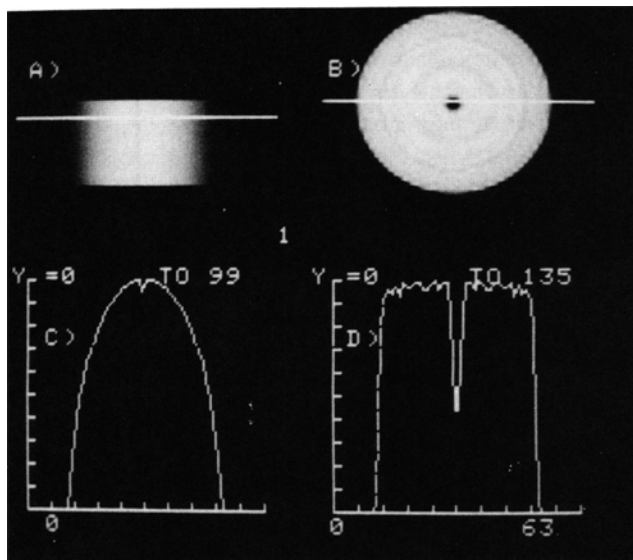


**FIG. 3.** A) One planar view of a cylindrical phantom filled with an infinite amount of radioactivity; B) Tomographic reconstructed slice at the level of the solid line in A; C) Count profile taken at the level of the solid line in A; D) Count profile taken at the level of the solid line shown in B. The oscillation observed in this profile is caused by ringing of the filter function from the edges of the cylinder. This low-level artifact is generated in all the noise-free reconstructions. Its presence will not affect any of the subsequent results.

facts in the reconstructed images. In order to see why this is also the case in nuclear medicine tomographic systems, let's focus on a given projection bin, say bin 35, in a 64 point projection of one tomographic slice. As shown schematically in Fig. 2, this particular bin maps out a circle at a well-defined distance from the center of rotation as the camera performs a  $360^\circ$  rotation. Assume that the object our camera rotates about is a cylindrical phantom containing a large amount of radioactivity. A planar view of this cylinder is shown in Fig. 3A. The curve shown in Fig. 3C corresponds to the profile through the level of the cylinder as denoted by the solid line in Fig. 3A. The corresponding tomographic reconstruction of this slice is shown in Fig. 3B with an appropriate profile through the reconstruction shown in Fig. 3D. Now, for reasons which will become clear later, assume that the absolute number of counts which are detected in bin 35 is altered and that this alteration occurs in all views. One of these planar views is shown in Fig. 4A with corresponding profile in Fig. 4C. It is not hard to imagine that a distortion will occur in the tomographic reconstruction of this cylinder at a radial distance from the center of rotation corresponding to that of the orbit of bin 35. Indeed, the tomographic reconstruction shown in Fig. 4B with appropriate profile in Fig. 4D, shows a ring artifact corresponding to the decrease of counts in bin 35 in the planar projections. A comparison of Fig. 4C and 4D shows that the decrease of counts in the tomographic reconstruction is significantly larger than the decrease of counts in each of the planar projections. Figure 5 shows the corresponding result for a decrease in counts, not at bin 35, but at the center of rotation (bin = 32). Here we observe that there is a much larger



**FIG. 4.** A) One planar view of a simulated cylindrical phantom filled with an infinite amount of radioactivity. In this and in all views, the count level in bin 35 has been decreased by 5% compared to the ideal case (See Fig. 3); B) Tomographic reconstructed slice at the level of the solid line in A. A large ring artifact is present; C) Count profile taken at the level of the solid line in A; D) Count profile taken at the level of the solid line shown in B. The relative decrease in counts at the location of the ring artifact is much larger than that observed in any of the planar views.



**FIG. 5.** A) One planar view of a simulated cylindrical phantom filled with an infinite amount of radioactivity. In this and in all views, the count level in bin 32 (center of rotation) has been decreased by 5% compared to the ideal case (See Fig. 3); B) Tomographic reconstructed slice at the level of the solid line in A. A large defect is observed at the center of the reconstruction; C) Count profile taken at the level of the solid line in A; D) Count profile taken at the level of the solid line shown in B. The relative decrease in counts corresponding to the center artifact is much larger than that observed in any of the planar views.

amplification of the defect in the tomographic reconstruction compared to that observed for the corresponding defect in bin 35 (Fig. 4B). What we have learned is that uncorrected flood field uniformities, e.g. defects at bin 35 or bin 32, cause circular artifacts (bull's-eyes) in tomographic reconstructions. Hence, it would appear that these artifacts could be removed by either having an excellent spatial distortion and energy correction in the camera system, or by using an adequate flood field corrector. However, return to the results of our cylindrical phantom example, which shows that for a high statistics planar acquisition, small non-uniformities are amplified in the reconstruction process. Any small deviation, which obviously exists in the energy and linearity corrector, or any statistical deviation in the flood field will cause observable ring artifacts in the reconstructed image. Remember that we are dealing with a case in which the statistics in the phantom acquisition are very large. As the acquisition statistics are decreased, the noise in the reconstructed image increases. At some level of statistics, the signal of the ring artifact should be masked by the noise contribution. This effect is shown in Fig. 6, where the ring caused by the defect in bin 32 is masked by the noise fluctuations inherent in the tomographic reconstruction process. Thus, the amount of flood field statistics necessary to correct a given tomographic acquisition is positively related to the statistics acquired in the study. Low count thallium-201 tomographic studies require smaller flood field statistics than does a higher count liver study.

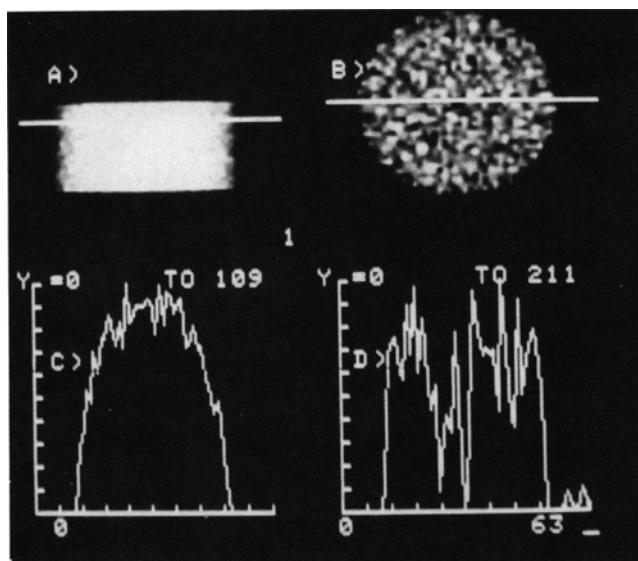
It is important to realize that the flood field statistics necessary for a clinical study may not satisfy those needed for a high statistics phantom acquisition. Phantom acquisitions de-

signed to test for ring artifacts in the clinically relevant setting should do so with cylindrical phantoms and statistics which correspond to that of the clinical acquisition.

## Filtering

All nuclear medicine computer systems employ the filtered backprojection algorithm to reconstruct transaxial slices from two dimensional projections. There are two distinct steps in this reconstruction procedure. First, the projection count data in each view for a given slice are filtered. Then, through the backprojection technique, the count value assigned to a pixel in the three-dimensional reconstructed image is derived by addition of the appropriate filtered count contributions from each of the planar projections.

General image filtering has become a standard nuclear medicine technique. Many software protocols in cardiac nuclear medicine have filtering algorithms designed to improve image quality through the reduction of noise. In emission tomography, image filtering or raw data modification is a mathematical necessity in order to produce a reconstructed image. Without some filtering of the raw planar images, the tomographic reconstruction process would lose its integrity and the reconstructed image would bear little resemblance to the input three-dimensional object. In the best of all possible worlds, we would acquire an infinite number of counts at an infinite number of view angles and with an infinite number of bin projection samples. The reconstruction filtering process would be straight-



**FIG. 6.** A) One planar view of a cylindrical phantom filled with radioactivity. The maximum count/pixel is 100 and the total counts/slice is 100,000. There is a 5% decrease in counts in bin 32 compared to the ideal case (See Fig. 3). Noise (Poisson) has been generated in each of the projections; B) Tomographic reconstructed slice at the level of the solid line in A. The large center artifact observed in Fig. 5B is now masked by the noise; C) Count profile taken at the level of the solid line in A; D) Count profile taken at the level of the solid line shown in B. There are large noise fluctuations in the tomographic reconstruction which mask the center artifact. The statistical fluctuations are larger in the tomographic reconstruction than in the planar view.

forward; however, in standard nuclear medicine practice, the requirement that the patient data acquisition take a reasonable amount of time places a significant limitation on the amount of counts per view that can be acquired. This factor and the degradation of resolution inherent in the normal nuclear medicine planar images implies that the theoretical constraints are not satisfied. Clinically, this means that the filtering will depend on the organ to be studied and the amount of view counts acquired.

The statistical variations in the tomographic reconstructed image do not have the same salt and pepper pattern (Poisson statistics) as do conventional nuclear medicine planar images. Moreover, the structure or texture of this noise intimately depends not only on the inherent statistics in the planar view acquisitions, but also on the tomographic filtering and reconstruction process itself. It is this fact that has led to the confusion regarding just what is real and what is artifact in a tomographic reconstruction. It is important to get a feeling for what tomographic image texture looks like for a particular clinical scan. This is best done by imaging a cylindrical phantom filled with radioactivity of a size near that of the organ of interest. Based upon our discussion above, we know that it is extremely important to acquire the data with the same number of planar views and approximately the same counts per pixel as in the patient acquisition, since total counts per slice is a key factor in the noise structure of the tomographic reconstruction. After acquisition, the data should be processed using the same filters as used clinically and the resultant images carefully analyzed. Only then will a clear understanding of the tomographic noise structure be obvious.

The projection data can be modified in many ways. The simplest approach is to filter the projection data in each slice without regard for the data in adjacent slices. This is the basic tomographic procedure which we call two-dimensional (2D) filtering. Similar to conventional filtering of planar images, an appropriate trade-off between noise and resolution must be made.

Other filtering procedures can be used to improve the signal to noise ratio in the final tomographic reconstructions. These techniques take advantage of the slice-to-slice correlations which exist in the raw data. In general, these procedures fall into the following two classes: preprocessing of the planar data and postprocessing of the transaxial data.

The preprocessing procedure modifies each of the planar views with the same filter before they enter the tomographic reconstruction process. Postprocessing of the transaxials can be performed using three-dimensional filters. These are functions which modify pixel values based upon the value of the other pixels in the three-dimensional neighborhood of the given pixel. Here again, there are many possibilities. Filters that are being used clinically include:

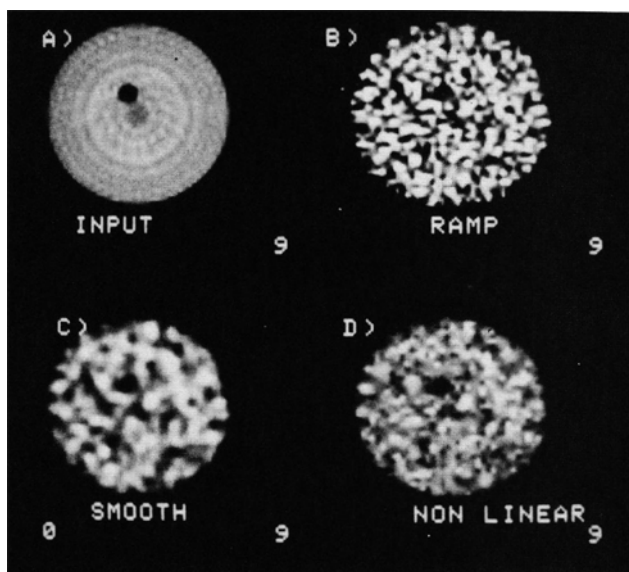
- Three-dimensional filters which are analogs of the basic two-dimensional smoothing functions (e.g. 9 point smooth becomes 27 point smooth in three-dimensions).
- Non-linear three-dimensional filters which are replacement filters, where a count value of a given pixel is compared to, for example, the average of the values of the pixels sur-

rounding it. The value of the pixel is replaced by the average if the deviation between it and its neighbors is large.

### Comparison of Different Filters

To show the effect of different filters on tomographic reconstructions, cylindrical phantoms with a radius of 20 pixels (6.2 mm/pixel) were generated. A void with a radius of 1.5 pixels and a height of three pixels (e.g. in the axial direction) was immersed in the phantom. Reconstructions were performed with 100,000 counts per slice. Figure 7 shows the reconstructed images at the level of the void. Figure 8 shows the reconstructed images for a slice which does not cut through the defect. Along with the noise-free reconstructions, the high resolution (Ramp), smooth and nonlinear 3D filter reconstructions are shown.\* Figure 9 shows profiles taken at the level of the void in each of the reconstructions. Note how the noise texture depends on the filter used for the tomographic reconstruction. The Ramp filter shows very high frequency oscillations which almost hide the fact that there is a defect present. The smooth filter reduces the high frequency fluctuations, but the patchy structures it creates are difficult to differentiate from the actual void present. The image resulting from application of the non-linear three-dimensional filter, which has been applied to each of the transaxial slices, shows a texture which is less patchy and without the high frequency oscillations of the Ramp. Dif-

\*The Ramp filter enhances the high frequency noise and maintains optimum resolution. The smooth filter used here is a Ramp-Hanning, which rolls off to zero at one-half the sampling frequency. The non-linear filter replaces a pixel value if the average value of neighborhood pixels deviate by more than three standard deviations.



**FIG. 7.** A) Tomographic reconstruction of a simulated cylindrical phantom with a void present. The projections were generated with no statistical noise; B) Ramp filter reconstructions for 100,000 cts/slice acquisition; C) Smooth filter reconstruction for 100,000 cts/slice acquisition; D) Nonlinear filter reconstruction for 100,000 cts/slice acquisition.

ferent filters can alter the final image quality so that filter functions must be investigated by each clinical investigator to determine what filter is best suited for a particular clinical study. Based upon our clinical experience, it appears that filters such as the 3D nonlinear filter, which limit the high frequency oscillations and reduce the patchy structures, are to be preferred in small statistics studies which involve lesion detectability.

Additionally, if only a two-dimensional smoothing filter is applied on a slice-by-slice basis, then an asymmetry in the third dimension (axial dimension) results. The horizontal streak patterns observed in the sagittal and coronal images shown in Fig. 10 are caused by non-symmetric three-dimensional filtering.

### 180° Acquisition: Effects of Attenuation and Resolution

The basic details related to traditional 360° tomographic data acquisition have been well described by others (4). Since tomographic thallium-201 myocardial perfusion imaging has become a widely used clinical tool, it is important to understand the basic technical details associated with data acquired over 180° arcs (5). A series of point sources located at various distances from a rotating gamma camera system are imaged. Folded into the computer simulations is the variation in planar view resolution that is dependent upon object depth and distance from camera. Symmetric and asymmetric 180° acquisitions are investigated. The symmetric acquisition about the point source is schematically illustrated in Fig. 11A. In this instance, the camera acquires the same number of planar views on the right and left side of the point. The center of rotation of the camera system is at 20 cm. Observe that in the anterior

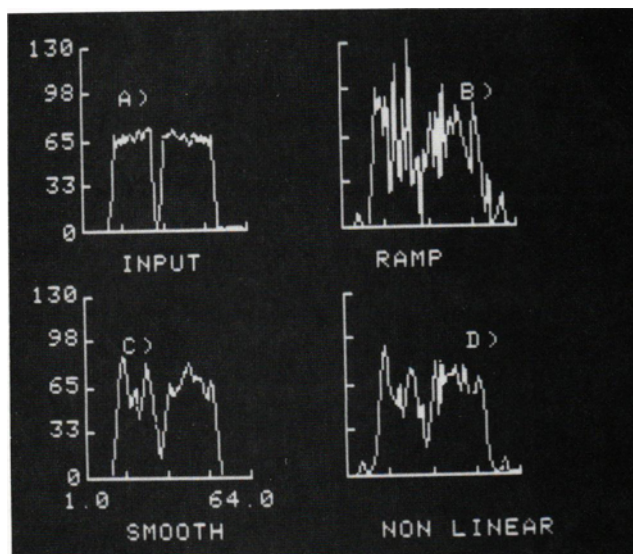


FIG. 9. Count profiles obtained from the corresponding reconstructions shown in Fig. 7.

views, the camera passes closest to the point source located at 5 cm. The tomographic reconstruction of these simulated point sources is shown in Fig. 11B, where the tomographically derived point source reconstructions are observed to be elliptical, with the minor axis of the ellipse corresponding to the direction of best resolution. The most anterior point (at 5 cm) shows the most asymmetric elliptical reconstruction, while the 20 cm point reconstruction (at the center of rotation) is observed to be large and circular. Therefore, on the basis of resolution variation with planar view angle, the tomographic reconstructions show resolution variations with depth. Figure 11C shows the corresponding schematic representation of an asymmetric 180° acquisition where the camera spends no time on the left side of the point sources. The tomographic reconstructions in Fig. 11D show severe distortions. These results imply that structures imaged with 180° asymmetric acquisitions are going to be severely distorted by the tomographic reconstruction process. Attenuation effects are also predicted to similarly distort the tomographic reconstructed images.

In our studies we have gone a step further and looked at simple models of tomographic myocardium acquisition which include similar resolution and attenuation effects. Such effects can alter the tomographically derived relative uptake of thallium-201 in the walls of the myocardium. For the nominal

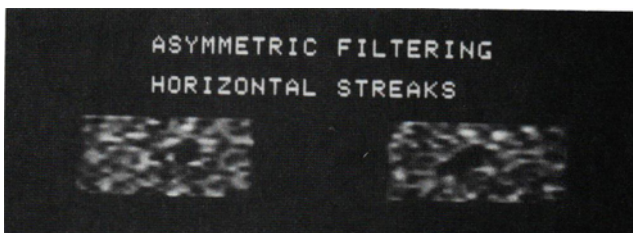


FIG. 10. Sagittal (left) and coronal (right) images show horizontal streak pattern caused by asymmetric three-dimensional filtering.

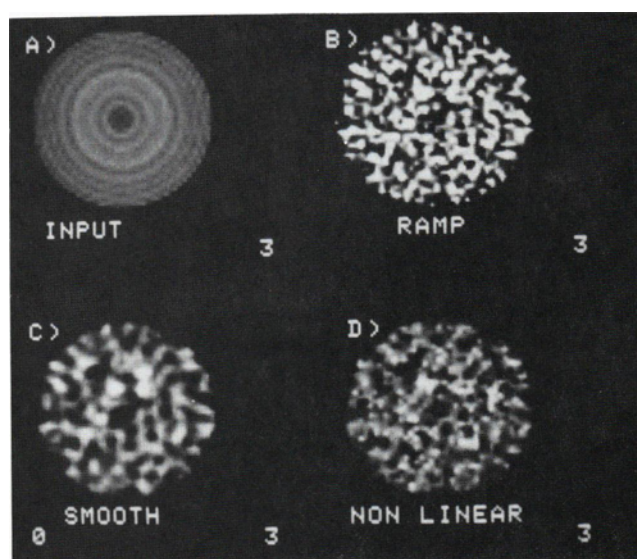
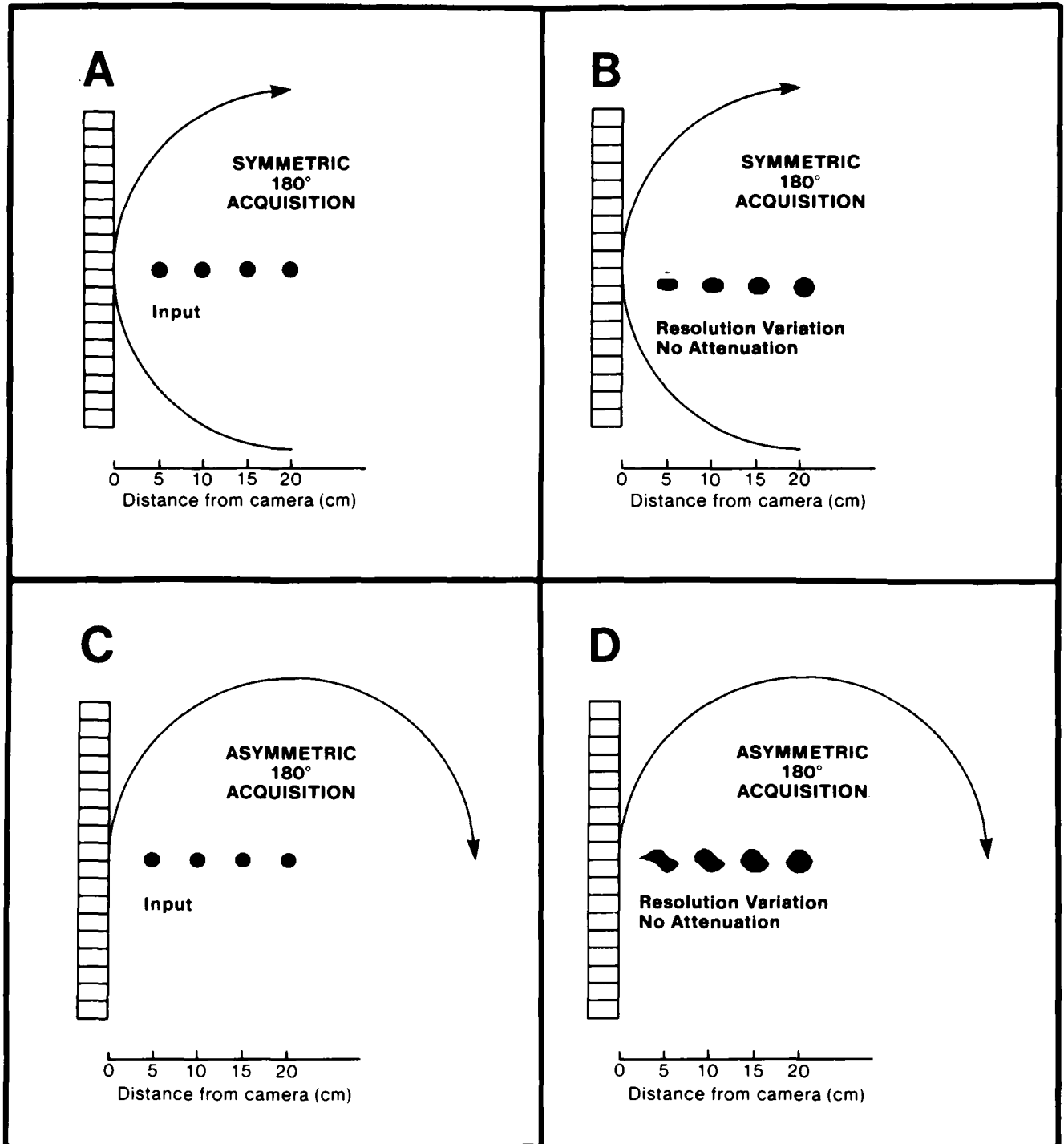


FIG. 8. A) Same as Fig. 7A, but for a region of the cylinder in which the void was not placed; B) Ramp filter reconstruction for 100,000 cts/slice acquisition; C) Smooth filter reconstruction for 100,000 cts/slice acquisition; D) Nonlinear filter reconstruction for 100,000 cts/slice acquisition.

180° acquisition arc (4) starting at the 45° RAO view and proceeding to the left lateral view, we have observed in normal subjects: 1) a relative decrease in the septum to lateral wall ratio of thallium-201 uptake; and 2) a relative decrease in the apex to lateral wall ratio of thallium-201 uptake. Our simulation study suggests that such distortions are caused by inadequate attenuation and resolution corrections. It should be stressed,

even for 360° acquired data, that the thallium-201 uptake in the myocardium is similarly predicted to be distorted. In either case, unless adequate deconvolution algorithms are invented which correct for attenuation and resolution changes with depth, clinically relevant interpretation and ultimate quantification of abnormality will depend upon comparison with normal patient data.



**FIG. 11.** A) Schematic representation of symmetric 180° camera acquisition of four point sources located at 5, 10, 15, and 20 cm from the camera in the anterior view; B) Tomographic reconstruction of the symmetric 180° acquisition; C) Schematic representation of asymmetric 180° camera acquisition of the four point sources; D) Tomographic reconstruction of the asymmetric 180° acquisition.

## BRAIN TOMOGRAPHY

Development and introduction of new radiopharmaceuticals such as I-123 iodoamphetamine, which penetrate the blood brain barrier and reflect brain perfusion, has stimulated interest in single photon emission computed tomographic studies of the brain. Conventional gamma camera systems, which use parallel hole collimators, are unable to get close to the head because they cannot clear the patient's shoulders during the 360° revolution. Thus, resolution in the tomographic reconstructions of the brain is severely compromised. As a first attempt to try to obtain better resolution, new collimator systems have been tried on conventional rotating gamma cameras. Among the most interesting are: 1) the long bore collimator, designed to produce better resolution by increasing the length of the holes as compared to conventional parallel hole collimators (6). However, the sensitivity of the system is severely compromised, limiting its usefulness for tomographic studies. 2) the slant hole collimator (7,8) has sensitivity equal to that of the parallel hole collimator and has been shown to produce better resolution for brain tomographic studies. Very rigid quality control procedures are necessary in the manufacture of the collimator and the clinical setup with this collimator is difficult. For the lower half of the head, there is only a slight improvement in image resolution.

The best approach currently on the market is one in which the detector head is cut off at the base so that there is no interference from the shoulders as the camera rotates about the patient. This system improves resolution through reduction of the distance of the camera to the brain.

## ELLIPTICAL SCANNING

If the detector head can be made to follow the non-circular contour of the patient during acquisition, better planar resolution as compared to that obtained from a circular orbit will result in better tomographic resolution. Gottschalk, et al (9) have shown that the tomographic resolution and contrast is improved in phantom studies obtained from elliptical (as compared to circular) acquisitions. Most manufacturers will soon deliver systems capable of performing elliptical rotation. However, we will see very different methodology involved in obtaining the orbit. Elliptical rotation is usually achieved by moving the camera in an elliptical path around a stationary patient or by moving the camera in a circular path around the patient who is on a table which moves in synchrony with the camera, resulting in an elliptical motion. The characteristics of the systems will be different. The degree of ring artifact, the time to set up the acquisition protocol, and the extent of the reduction of field of view are the main trade-off areas.

The tomographic software for systems in which the camera or the patient move along radial paths, outward from the center of rotation, is identical to the conventional software designed for circular rotation. On the other hand, systems which move so that the center of rotation changes with view angle will be more immune to circular artifacts as compared to conventional circular orbiting systems.

## CLINICAL ISSUES

Tomography has changed the basic methodology upon which the nuclear medicine department operates. Issues relating to throughput must be addressed if tomography is to be incorporated into the nuclear medicine clinical routine. These include:

**Acquisition.** The time to complete a typical tomographic acquisition is 20 min or longer. The technologist has essentially little to do during this time, except to insure that the patient is stationary, comfortable, and the gamma camera is rotating and acquiring data. Some time may be available for the technologist to process other studies. However, safety procedures, which may become even more critical when elliptical and body contour orbits are introduced, demand that the operator remain near the rotating camera system. Such constraints require that the computer system possess the intrinsic capability to acquire and process data at the same time. The system should provide for simultaneous acquisition and processing to accommodate additional technological computer systems and additional reconstruction of transaxial, sagittal and coronal sections.

**Processing.** Configurations which include array processors for reconstructions or for fast Fourier transforms or hard wired back projectors for reconstruction, may significantly increase tomographic throughput. This is particularly true for procedures which require a large number of transaxial slices to be reconstructed, such as liver or bone scans. However, it is important to realize that the quantitation of data and the subsequent review of data take a significant portion of the time spent on the interpretation of the tomographic scans.

**Review.** Compared to a normal nuclear medicine study, a tomographic scan produces a large increase in the number of images which must be reviewed. There is an increasing demand on the clinician to spend a significant amount of time reviewing patient data at the computer terminal. Independent display systems and/or separate review terminals, which are away from the patient acquisition system, may be an important system requirement and should not be overlooked when configuring a tomographic system.

**Dual Headed System.** Some manufacturers provide an upgrade of their basic single headed tomographic unit to one with two 180° opposed camera heads. Acquisition times are reduced by one-half those needed for single headed systems, with no loss in sensitivity. Alternatively, the statistics can be increased by a factor of two for the same acquisition time.

Important issues to be addressed when considering a two headed camera purchase:

- There is a large cost differential compared to that of a single headed tomographic system.
- Cardiac applications such as Tl-201 myocardial perfusion imaging only require data from a 180° acquisition. If used, the data from the second (posterior) head may actually degrade image quality.
- The software on the computer must support dual headed quality control calibration, acquisition, and processing.
- The camera manufacturer should provide an upgrade plan to a dual headed elliptical scanning system.



In summary, the past several years have seen nuclear tomography come out of the research laboratory to become a viable clinical tool. As in many areas of nuclear medicine, the statistics are limited and the resolution in most studies is no better than 1 cm. Nonetheless, compared to conventional nuclear imaging, there is enhanced clinical diagnostic value. The challenge for the nuclear medicine technologist is to thoroughly grasp the fundamentals related to the tomographic process.

## REFERENCES

1. Williams DL, Ritchie JL, Harp GD, et al. In vivo simulation of Tl-201 myocardial scintigraphy by seven-pin-hole emission tomography. *J Nucl Med* 1980;21:821-28.
2. Tamaki N, Mukai T, Ishii Y, et al. Clinical evaluation of Tl-201 emission myocardial tomography using a rotating camera: Comparison with seven-pin-hole tomography. *J Nucl Med* 1981;22:849-55.
3. Keyes JW. Perspective on tomography. *J Nucl Med* 1982;23:633-40.
4. Larsson SA. Gamma camera emission tomography. *Acta Radiol (Suppl)* 1980;363:1-75.
5. Eisner RL, Gullberg GT, Malko JA, et al. Effects of 180° acquisition on tomographic image quality. *J Nucl Med* 1984;25:P30.
6. Muller S, Polak JF, Holman BL, et al. SPECT imaging with the long bore collimator. Loss in sensitivity vs. improved contrast resolution. *J Nucl Med* 1984;25:P106.
7. Polak JF, Holman BL, Moretti JL, et al. I-123 HIPDM brain imaging with a rotating gamma camera and slant-hole collimator. *J Nucl Med* 1984;25:495-98.
8. Esser PD, Alderson PO, Mitnick RJ, et al. Angled-collimator SPECT (A-SPECT): An improved approach to cranial single photon emission tomography. *J Nucl Med* 1984;25:805-09.
9. Gottschalk SC, Salem D, Lim CB, et al. SPECT resolution and uniformity improvements by noncircular orbit. *J Nucl Med* 1983;24:822-28.