

Case Report: Spectral Overlap Artifact During Dual Isotope Imaging with Tc-99m and In-111

Susan A. White, Donald H. Mueller, Hilton E. Smith, Harinder S. Brar, Leo K. Min, Paul H. Brown, and Fredrick E. Turner

Veterans Administration Medical Center, Portland, Oregon

Dual isotope imaging with Tc-99m sulfur colloid and In-111 autologous leukocytes has been suggested as an appropriate technique to exclude abscesses when they are located in the liver or spleen (1). Image artifacts were created when such a technique was used and we report the necessary steps to be taken to avoid such problems in the future.

Case Report:

A fifty-year-old male was referred to nuclear medicine for liver-spleen imaging in order to rule out hepatic abscess following abdominal surgery. Five mCi Tc-99m sulfur colloid was administered and 500k count images were obtained using a large field-of-view scintillation camera with a low energy high resolution collimator. One lesion was seen on the anterior image (Fig. 1A) and two lesions on the right lateral image.

An In-111 leukocyte study (2,3) was then requested to confirm hepatic abscess. Imaging was performed twenty-four hours after intravenous administration of 0.5 mCi In-111 labeled autologous leukocytes. A large field-of-view gamma camera with a medium energy parallel hole collimator was used to acquire 500k count (or 10 minute) images (Fig. 1B) from two 20% windows centered around the 173 and 247 keV In-111 photopeaks. A Tc-99m sulfur colloid image subtraction technique was then performed using 2 mCi of Tc-99m sulfur colloid to subtract liver tissue from the In-111 image (1).

Upon reviewing the In-111 and 2 mCi Tc-99m subtraction images, the nuclear medicine physician then requested an additional In-111 image in the right anterior oblique position (Fig. 1C). The In-111 image contained discrete "hot spots" resem-

bling photomultiplier tube artifact. It was suspected that spectral overlap from Tc-99m into the 20% window centered on the 173 keV photopeak of In-111 was responsible for this artifact. Narrowing the 173 keV window from 20% to 10% eliminated the artifact (4). Counting efficiency of In-111 was slightly diminished.

In order to eliminate a camera hardware malfunction as the source of the image artifacts, the camera was "tuned" with a Tc-99m point source by the camera manufacturer's service representative. We then tried to duplicate this artifact using a flood phantom. Initially, 0.3 mCi In-111 oxine was used to obtain a flood field image (Fig. 2A) with 20% windows centered around 173 keV and 247 keV photopeaks. No artifacts were present in the image of the flood containing only In-111. The gamma spectrum obtained is illustrated in Fig. 3A. Next, 2 mCi [^{99m}Tc] pertechnetate was added to the flood phantom. The gamma spectrum demonstrated overlap of Tc-99m into the 20% window (156–190 keV) centered on the 173 keV In-111 gamma photopeak (Fig. 3B). The artifact observed in the previous patient study was present using the flood phantom containing both In-111 and Tc-99m (Fig. 2B). Note that the gamma camera used is a modern design which incorporates a microprocessor for an automatic energy uniformity correction. This correction system did not eliminate artifactual results (Fig. 2C).

Discussion and Conclusion

This artifact occurs because of the presence of spectral overlap of millicurie amounts of Tc-99m when imaging microcurie amounts of In-111. The artifactual In-111 floods are similar to the results which would be obtained with off-center peaking for Tc-99m. The automatic energy correction did not prevent

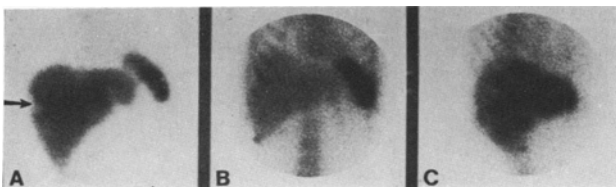


FIG. 1. (A) Anterior Tc-99m sulfur colloid liver image demonstrating one lesion (arrow). (B) Anterior In-111 labeled leukocyte image in the same patient before Tc-99m sulfur colloid. (C) Right anterior oblique In-111 image following the administration of 2.0 mCi Tc-99m sulfur colloid demonstrating photomultiplier tube artifact.

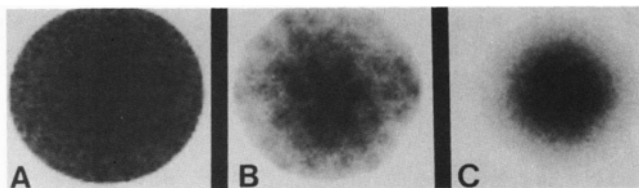


FIG. 2. (A) Flood field image obtained with 0.3 mCi In-111 oxine. Twenty percent windows were centered around 173 and 247 keV. (B) Indium-111 flood field image obtained following addition of 2.0 mCi [^{99m}Tc] pertechnetate without automatic energy uniformity correction. (C) Indium-111 flood field image obtained following addition of [^{99m}Tc] pertechnetate with automatic energy uniformity correction.

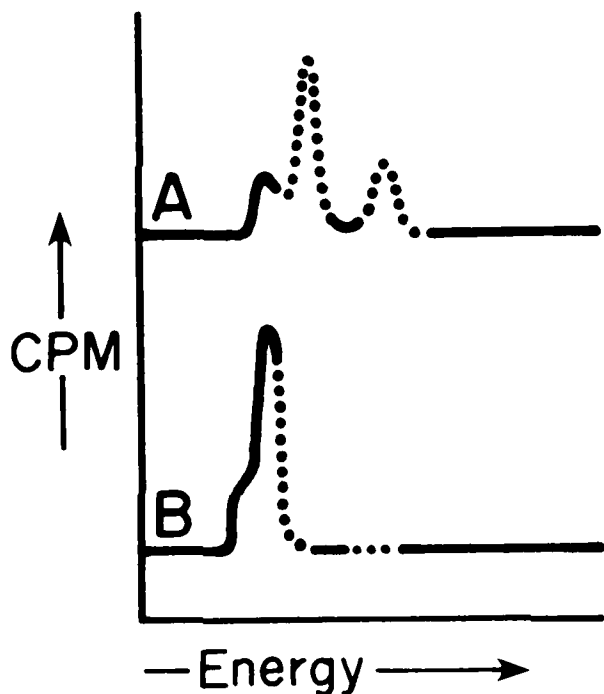


FIG. 3. (A) Gamma spectrum obtained from 0.3 mCi In-111 with 20% windows around 173 and 247 keV. The dotted line indicates the imaging window settings. (B) Gamma spectrum obtained following the addition of 2.0 mCi [^{99m}Tc] pertechnetate into the flood phantom with 20% windows centered around 173 and 247 keV.

artificial results when using a 20% window around the 173 keV photopeak in the presence of much larger amounts of Tc-99m.

Careful technique must be followed to avoid technical artifacts during In-111 imaging in the presence of Tc-99m (4). Always use a pure In-111 source to select and adjust imaging windows. A patient does not constitute a pure source because the rest of his body acts as a scattering medium. This is true for imaging with any radionuclide. Select a 10% window around the 173 keV In-111 gamma peak to prevent spectral overlap with the Tc-99m. Tc-99m is usually present in much larger amounts than the In-111 which may result in artificial results if a 20% window is selected.

Acknowledgment

We wish to thank Barbara Wright for her assistance in the preparation of this manuscript.

References

1. Rovekamp MH, van Royen EA, Folmer SCCR, et al. Diagnosis of upper-abdominal infections by In-111 labeled leukocytes with Tc-99m colloid subtraction technique. *J Nucl Med* 1983;24:212-16.
2. Thakur ML, Coleman RE, Welch MJ. Indium-111 labeled leukocytes for the localization of abscesses: preparation, analysis, tissue distribution, and comparison with Gallium-67 citrate in dogs. *J Lab Clin Med* 1977;89:217-28.
3. Thakur ML, Lavender JP, Arnot RN, et al. Indium-111-labeled autologous leukocytes in man. *J Nucl Med* 1977;18:1014-21.
4. Fernandez-Ulloa M, Hughes JA, Krugh KB, et al. Bone imaging in infections: artifacts from spectral overlap between a Tc-99m tracer and In-111 leukocytes. *J Nucl Med* 1983;24:589-92.