

# False-Positive Meckel's Diverticulum Scan of Nonpathologic Origin

Mary E. Maxwell and Bonnie Baggenstoss

St. Paul-Ramsey Hospital and Medical Center, St. Paul, Minnesota

Numerous articles have been published concerning the reliability and usefulness of  $^{99m}\text{Tc}$ -pertechnetate scanning to diagnose Meckel's diverticulum. The Meckel's diverticulum is an appendage of the ileum near the cecum. To be demonstrated by scanning, the Meckel's diverticulum must contain gastric mucosa which will actively concentrate and secrete the  $^{99m}\text{Tc}$ -pertechnetate. Meckel's diverticulum is not readily visualized by conventional radiographic techniques (1). Short of surgical exploration, the  $^{99m}\text{Tc}$ -pertechnetate scan is currently probably the most reliable method for diagnosing the Meckel's diverticulum.

One of the serious pitfalls of this study is the incidence of false-positive scans due to a variety of maladies: ulceration (peptic) of the small intestines, abdominal aneurysm, hemangioma in the small intestines, partial obstruction of a ureter resulting in accumulation of the isotope proximal to the site of obstruction, hydronephrosis with collection of isotope in the dependent part of the renal pelvis, and abscesses in the right pelvic area (2). Strangulation of the bowel and intussusception may also cause false-positive findings in scanning for Meckel's diverticulum (1). We have encountered still another type of false-positive scan of nonpathologic origin.

## Case Report

A four-year-old black boy presented with bright red rectal bleeding. The child was well until several hours before admission when his bleeding started. The child was essentially asymptomatic, with no abdominal pain or discomfort. He was admitted with a diagnosis of rectal bleeding of unknown etiology. The physical exam was within normal limits. Abdomen films and proctoscopy were essentially normal. The patient experienced a rather sharp drop in hemoglobin from 10.7 to 6.8 during the first 4 hr after admission. He was transfused

with 500 cc of whole blood and sent to the Nuclear Medicine Department for an abdominal scan to rule out Meckel's diverticulum. Since this was considered an emergency procedure, the patient was not in a fasting state before the study.

## Technique

The patient received 100 mg  $\text{NaClO}_4$  orally and 1.7 mCi  $^{99m}\text{Tc}$ -pertechnetate i.v. Scans were done at 2, 6, and 24 hr using a Nuclear-Chicago HP gamma camera with a low-energy, parallel-hole, high-sensitivity collimator. Five hundred thousand counts were accumulated for each scintiphoto on the 2- and 6-hr studies, and 50,000 counts were accumulated for the 24-hr scintiphoto.

## Results

The 2- and 6-hr studies were negative for the presence of a Meckel's diverticulum. Duszynski, et

---

For reprints contact: Mary E. Maxwell, St. Paul-Ramsey Hospital and Medical Center, 640 Jackson St., St. Paul, Minn. 55101.


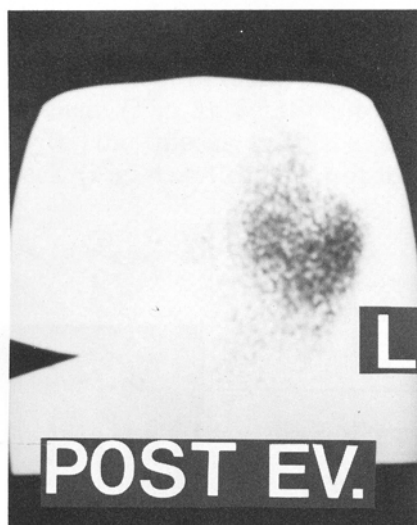


FIG. 1. Twenty four-hour film taken in AP position shows area (indicated by arrow on right) of increased activity in region of cecum.



**FIG. 2.** Previously noted activity in cecal region is no longer present following cleansing and barium enemas.

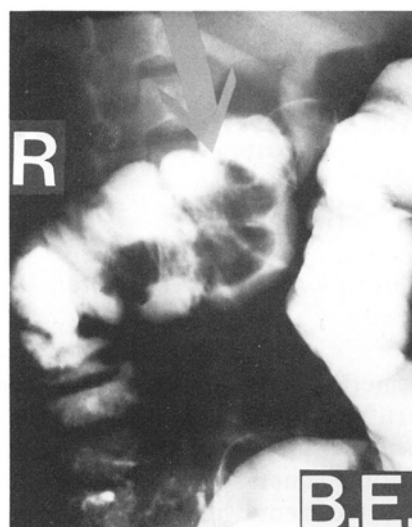
al (1) reported positive demonstration of a Meckel's diverticulum at 24 hr after most of the isotope is decreased in the surrounding structures. It was elected to do a 24-hr study on this patient in light of his clinical history and symptoms.

The 24-hr study (Fig. 1) showed activity present in the stomach and a single area of increased activity in the right lower quadrant. Following the 24-hr study a barium enema to include air contrast study was performed on the patient. An irregular filling defect was noted in the region of the hepatic flexure, but the terminal ileum appeared normal. However, the defect was considered an equivocal finding because large amounts of residual feces were noted in the ascending colon. Cleansing enemas and repeat barium enema were recommended. A repeat scan was done after cleansing enemas had been given (Fig. 2), and the area of increased activity noted in the right lower quadrant on the 24-hr examination was no longer present.

The repeat barium enema confirmed the presence of a large 4-cm-diam pedunculated polypoid lesion with a 1.5-cm-diam stalk measuring approximately 3 cm in length (Fig. 3). Findings were characteristic of a large juvenile polyp. Pediatric surgery elected to avoid surgery and allow the patient to slough the polyp.

### Conclusions

For obvious reasons, emergency studies are



**FIG. 3.** Arrow indicates location of large polyp in proximal portion of transverse colon.

often performed without adequate preparation. Ideally, the patient should be in a fasting state to reduce stomach size and should have an empty bladder to avoid masking any pathology in the region when trying to rule out Meckel's diverticulum.

As demonstrated in this reported case, accumulation of radioactivity around fecal material contained in the cecal region can present problems in interpretation of the scintiphotos. In this case, only the 24-hr study was affected, but conceivably sufficient activity could also accumulate in the cecum by the 6-hr scintiphoto. Earlier scintiphotos probably would not be affected. Therefore it is recommended that Meckel's diverticulum scan protocols include cleansing enemas before doing the 6- and 24-hr scintiphotos. This may avoid hasty and unnecessary surgical intervention in the event the study turns out to be a false-positive finding.

### References

1. Duszynski DO, Jewett TC, Allen JE: Tc-<sup>99m</sup> Na pertechnetate scanning of the abdomen with particular reference to small bowel pathology. *Am J Roentgen* 113: 258-262, 1971
2. Chaudhuri TK, Chaudhuri, TK, Christie JH: False positive Meckel's diverticulum scan. *Surgery* 71: 313-314, 1972