

## **Brain Quality Assurance - How to Acquire the Best Brain Images Possible**

Barbara J. Grabher BS, CNMT, RT(N)<sup>1</sup>

<sup>1</sup>Grabher Consulting & Specialty Services (GCSS), Abingdon, MD and Life Molecular Imaging, Inc. (fka - Piramal Imaging), Boston, MA

**Brief Title:** Brain Quality Assurance

**Corresponding Author/1<sup>st</sup> Author:** Barbara J. Grabher, BS, CNMT, RT(N), 3113 Pouska Rd., Abingdon, MD 21009, phone: 443-504-9104, email: [barbara.grabher@gmail.com](mailto:barbara.grabher@gmail.com)

**Word Count:** 5313

### *Abstract*

Multiple factors affect image quality regardless of the organ a Nuclear Medicine Technologist (NMT) is imaging. It is extremely important that every aspect of an image protocol be followed properly to ensure the highest image quality. If image protocols are not followed properly, image quality as well as a nuclear medicine physician's interpretation and final report, and conceivably a patient's care plan and management by their physician, could be negatively affected. It is important that NMTs understand the elements that can affect brain image quality and learn ways to overcome challenges they may face when acquiring any type of brain image, whether it is Single Photon Emission Computerized Tomography (SPECT), dopamine transporter (DaT) imaging, amyloid imaging or Fluorodeoxyglucose (FDG) Positron Emission Tomography (PET) brain imaging.

**Key words:** brain imaging; image quality; patient positioning; technical; quality assurance

## **Introduction**

Optimal imaging of the brain using molecular imaging techniques relies on multiple factors to achieve optimal results. The aim of this continuing education article is to review the administrative, technical and interpretative factors that can affect image quality when acquiring any type of nuclear medicine or PET brain image. The article will help the nuclear medicine technologist (NMT) understand the relationship between proper patient positioning and image quality regardless of the type of brain imaging being performed. These techniques are applicable to both SPECT and PET imaging. Examples for DaT imaging, amyloid imaging, FDG PET brain imaging, are provided; however, the positioning techniques in this article can also be applied to perfusion imaging with Tc-99m tracers. The article also illustrates the importance of following the instructions in a radiopharmaceutical package insert, including acquisition and processing parameters, to maximize image quality. Lastly, this article reviews how to make post-acquisition adjustments to improve image quality when needed. A report published by Future Market Insights in September 2017 stated that the Compounded Annualized Growth Rate (CAGR) for molecular imaging is expected to be 7.5% between 2017 and 2027. This growth rate is being fueled by the use of cutting-edge technology such as PET/CT and PET/MR as well as new molecular imaging radiotracers being introduced into the market for movement disorders, amyloid plaque imaging, and prostate imaging just to name a few (*1*); making it imperative that NMTs and interpreting physicians understand all factors that can affect quality brain imaging and how to improve scan quality when challenges arise.

### ***What is Quality***

Quality can be defined and measured in different ways depending on what industry you are in. In manufacturing quality is defined as “A measure of excellence or a state of

being free from defects, deficiencies and significant variations” (2). Many manufacturing companies like Toyota, General Electric, and Motorola use Six Sigma and Lean Six Sigma process improvement practices and techniques to help measure and improve quality in the products they manufacture and the services they provide. Six Sigma is defined as 3.4 defects per 1 million opportunities (3). Most average companies operate at a 3 or 4 sigma; while world-class companies operate at 5 or 6 sigma (4). Let me ask you a question – Do you think a company, hospital or radiology/nuclear medicine department operating at 99.9% efficiency is good? More than likely you’re probably going to say yes 99.9% is excellent but let’s look at some examples and see if 99.9% is as good as you think it is. From a Six Sigma perspective 99.9% means:

- 50 new born babies are dropped at birth by a doctor/day<sup>[LT1]</sup>
  - 10 hours of unsafe drinking water is produced every month
  - There would be 2 unsafe plane landings at Heathrow or Chicago O'Hare International Airport each day or 4,380 unsafe landings each year
  - 16,000 pieces of mail would be lost by the post office every hour or over 140M pieces of mail per year would be lost
  - 500 incorrect surgical operations would be performed/week or 26,000 incorrect operations per year
  - 22,000 checks would be deducted from the wrong bank account/hour or over 192M checks deducted from wrong accounts per year
  - 32,000 missed heartbeats, per person, per year
- Source – Chi Solutions Inc. October 2008 Newsletter (4)

From the examples mentioned above, you can see that 99.9% is not as good as you may think. There is always room for improvement no matter what industry you work in. Many 6 sigma professionals have estimated that a company operating between a 3 and 4 sigma can expect about a 10% loss in revenues from inefficiency (5). In the competitive business environment, we compete in today, no company, hospital or nuclear medicine department can

afford to lose revenue due to inefficiency. We can have it all – satisfied patients and physicians, and lower costs with higher quality.

In healthcare, quality is measured and described in many ways. According to Carolyn M. Clancy M.D. who provided testimony before the Committee on Finance, Subcommittee on Health Care, United States Senate in March 2009, stated: “Healthcare quality is getting the right care to the right patient at the right time – every time” (6). Failure in getting the right care to the right patient at the right time – every time costs organizations money. Additional labor, materials, and customer dissatisfaction from both the patient and physician, results in loss of revenue, which takes away from the hospital’s profitability and overall success of the healthcare system. Table 1 provides some examples of profitability achieved by healthcare organizations by implementing Six Sigma process improvement projects and thus eliminating waste and insufficiencies.

Providing the right care and information to patients and their physicians in the timeliest, most efficient manner possible the first time is key to any healthcare system’s success and future growth. In the past decade, many healthcare organizations have also started utilizing Six Sigma and Lean Six Sigma practices and procedures to help ensure they are providing the highest and most efficient quality care possible to the people they serve, ensuring continued success and profitability of their healthcare system (4). Six Sigma process improvement methodologies are used to analyze and streamline routine processes and procedures to improve every aspect of quality and care provided to patients and physicians. Table 2 provides some examples of projects that could be implemented in a nuclear medicine or radiology department setting to improve efficiency and quality.

Nuclear Medicine healthcare professionals, both technologists and physicians, play a key

role in providing patients and their physicians the highest quality images and reports possible, ensuring that the right patient gets the right care, at the right time, the first time – every time.

### ***Three Areas of Quality in Imaging***

There are three general areas of quality in imaging – administrative, technical and interpretative quality (5). Figure 1 illustrates the different components that need attention when imaging patients to produce optimal results. Administrative, technical and interpretative quality can have an effect on each other. One can do everything right regarding the administrative and technical quality of a scan; but if the interpretative quality is not up to par, the final report and overall quality of the scan could be suboptimal for purposes of patient care. Suboptimal reporting can potentially result in missing or misleading information being communicated to the referring physician. Even worse, the scan could be misread, potentially leading to a wrong diagnosis. It is essential that all areas of image quality are followed properly to ensure the highest quality scan and results provided to the referring physician.

### ***What makes a Good Brain Image?***

The first step in a good brain image is to follow all the administrative, technical and interpretative guidelines for a particular brain imaging protocol that is being required, as well as following the prescribing information in the radiopharmaceutical package insert. If the package insert says inject at six seconds per milliliter, then make sure you inject the radiopharmaceutical at that rate. Instructions in a package insert are there for a reason and should be followed for best results. However, there is one more thing the NMT can do to make sure we are getting the best brain images possible, no matter what type of procedure we are performing: be “technically consistent” with everything done. Technical consistency in patient preparation, positioning, acquisition and reconstruction parameters, proper orientation of amyloid and FDG brain slices

(Transverse, Sagittal, Coronal), and proper orientation regarding DaTscan images (especially coronal tilt) will result in the best possible quality. It is also important that we are technically consistent in the display parameters we use and that we avoid over-processing making images look too smooth; possibly causing the images to be misinterpreted by the reading physician. Not being technically consistent in how we position our patient or how images get processed could negatively impact the interpretation of the scan. If individual NMTs changed processing parameters based on their individual eye, the Nuclear Medicine physician could get inconsistent results depending upon which NMT did the processing. Being technically consistent in all aspects of an imaging protocol is key to getting the highest quality scan and highest quality report. According to Sajdak et al., following Standard Operating Procedures (SOPs) helps ensure that NM Physicians and NMTs follow an imaging protocol helping to ensure reproducibility and consistency which in turn is key in producing the highest quality images (7).

### ***Patient Positioning***

Patient positioning is a critical technical step in the imaging protocol. Proper positioning of the patient reduces the likelihood of artifacts due to motion, promotes patient comfort and most importantly helps interpretation by providing standardized and artifact-free scans. Make sure you take the extra time to ensure your patient is comfortable and secure on the table... You will be glad you did! If you don't make sure your patient is comfortable and secure on the imaging table there is a greater chance that your patient is going to move, and the scan will have to be repeated.

Before starting any type of brain scan, make sure the patient uses the restroom as well as removing their glasses, earrings, hair clips/combs, and hearing aids. Place the patient's head in a head holder, so the vertex of their head is at the superior edge of the head holder. See Figure 2A

for where the head should be positioned in the head holder. Figure 2B shows improper head placement. If you are using a head holder with extended sides, use foam wedges, folded sheets or blue [chux](#)<sup>[LT2]</sup> (absorbent pad) to slide between the patient's head and the head holder to stabilize the head. This technique allows the patient to feel something against the side of their head and face, which can be a reminder for them to hold their head still during the scan.

The cantho-meatal line is another landmark or reference point that helps position the patient's head properly in the head holder. It is defined as an imaginary vertical line drawn from the external canthus (external corner) of the eye to the meatus (center) of the ear. It is important to make sure that the cantho-meatal line is vertical and also perpendicular to the imaging table. The black line in Figure 2A shows where the cantho-meatal line is located. If for some reason you cannot position the cantho-meatal line vertically and perpendicular to the imaging table, position the patient's head in a natural relaxed position and secure the patient's head with a chin strap and a head strap to ensure the patient's head is perfectly still during the acquisition of the scan. You can reorient the brain into its proper position when you process the images. According to an article entitled "The Semicolon Sign: Dopamine Transporter Imaging Artifact from Head Tilt" by Covington et al. in [2013](#)<sup>[LT3]</sup> "Small deflections of the cantho-meatal line from the vertical position can signify abnormal head tilt" as seen in Figure 2B.

Once you have the patient's head properly positioned in the head holder, the next step is [to](#)<sup>[LT4]</sup> secure the patient's head using self-adherent chin and head wraps (cohesive tape) to make sure they do not move their head. Even if the patient states they can hold still for the scan you still want to use the chin and head straps to ensure there is not patient motion. You want to position the patient's arms at their sides and stabilize them by using bed straps or other measures to minimize patient movement during the scan. If you let the patient put their arms on their



stomach without using a body strap their arms may get tired during the scan and start moving, which in turn could move their shoulders, which in turn could possibly make their neck and head move. Place a foam wedge or pillow under the patient's knees and cover them with a blanket to ensure they are warm and comfortable on the imaging table. If your scanner is equipped with lasers, use the laser system to properly position the patient's head and adjust the table height to ensure the patient's head is in the center of the field of view (FOV). With all brain imaging you want to position the patient's brain in center of the FOV, making sure to include the complete coverage of the cerebellum; especially when you are performing amyloid or FDG brain imaging. Figures 3A and 3B show images of proper patient positioning on the imaging table using the head strap, chin strap, body strap and knee cushion as well as the laser light system. The last thing you want to do before you start the scan is while standing at the bottom of the scanning table look up to make sure the patient's head is correctly positioned and correct for any signs of head rotation if need be.

As we all know not all patients are able to lay flat and still on the imaging table for their scans. These types of patients can be very challenging when it comes to positioning them on the imaging table and achieving the best quality images possible. Patients with severe arthritis and back issues are usually very difficult to position properly; patients with kyphosis or severe neck issues can be extremely challenging to position as well. With a little coaching, support and a few pillows even these difficult patients can be positioned and scanned achieving the best quality possible. Figure 3C illustrates the best way to position patients with kyphosis or severe neck and back pain. I learned this positioning trick many years ago from an x-ray technologist. It looks a little scary, and it appears like you are dumping the patient on their head, but it works every time.

You need to make sure the patient is comfortable and strapped securely on the table. These positioning tricks can be used for all kinds of brain imaging.

Another patient positioning challenge pertains to DaTscan imaging. While a patient may be able to lay flat and hold still for the entire 30-minute scan; one of the other critical steps when positioning a DaTscan patient is how close the camera head is to the patient. We all learned during our general nuclear medicine training that the resolution of an image decreases as the camera distance increases away from the patient (8). So, positioning the camera head as close as possible is key to good quality DaTscan images. With DaTscan imaging it is recommended in the package insert that the camera radius must be between 11cm and 15 cm (9). The reason for getting the camera radius so close is important when imaging a DaTscan patient is because the caudate and putamen you are imaging are very small structures positioned in the middle of the brain and are approximately the size of a cashew (10). Figure 4 illustrates where the caudate and putamen are located within the brain. Imaging two very small structures the size of a cashew in the middle of the brain with a large field of view camera with camera heads approximately 36 inches long and 24 inches wide; you can see why the camera radius must be as close as possible. Figure 4c illustrates what happens to image quality when the camera radius increases from the recommended 12.8 centimeter (cm) radius to 15.0 cm and 20.0 cm respectively. As the camera radius increases you can see the putamen or tails of the DaTscan image appear shorter; potentially causing the interpreting physician to call this image positive when in reality the scan is negative based on the 12.8 cm image. Figure 4d illustrates how close the camera head should be to the patient when positioning them under the camera. I can tell you from experience this is not easy to do; the patient is nervous that camera is going to hit them, you might be nervous to get the camera heads that close to them especially if this is your first time performing a DaTscan. Sometimes a patient will say I am nervous and instinctually you are going to back the camera

head away from the patient, but it's extremely important that you get the camera heads as close as possible. The best advice I can give for this camera radius positioning challenge is to practice positioning your nuclear medicine colleagues, the more comfortable and confident you are at positioning the camera radius as close as possible to the patient the more comfortable your patient will feel. You can get close it just takes a little bit of practice. Shoulder clearance is an important factor to consider with setting the radius.

### ***Head Orientation***

Head orientation is also another important aspect of patient positioning in all brain imaging; if head orientation is incorrect or not fixed manually during processing - displayed images could be difficult to interpret by the nuclear medicine physician possibly reducing image quality and affecting the nuclear medicine physician's final report. Sagittal tilt (forward or backward head tilt) has little effect on image quality when acquiring a DaTscan, but when acquiring amyloid or FDG imaging, sagittal tilt can affect image quality. With a forward head tilt on amyloid imaging, you will see the frontal lobes before you will see the lateral temporal lobes and with a backward head tilt you will see the cerebellum and parietal lobes before you will see the lateral temporal lobes. Figures 5a illustrates how a sagittal head tilt (forward or backward head tilt) does not affect DaTscan images. Unfortunately, lateral tilt can cause difficulties in both DaTscan and amyloid imaging; Figure 5b illustrates the effect that lateral head tilt has on both DaTscan and amyloid images. There are several ways to improve image quality related to head orientation; the steps a NMT can take include:

- Properly position patient and patient's head at the beginning of scan making sure laser positioning lights are used to aid in proper orientation of patient's head and height of imaging table.

- Manually adjust processing angles to re-orientate the brain correcting for sagittal and coronal head tilt. The coronal image on the image display is a good image to use to see if a patient's head is tilted. Figure 5c illustrates properly and improperly positioned images and a solution to achieve the best-orientated images.
- Communicate with interpreting NM Physician that positioning the patient was challenging and out of the norm and that the orientation of the patient's head during the processing may be affected.

### ***Processing and Display Parameters***

Processing and display parameters are another component of the imaging protocol that can affect image quality if not followed properly and should not be overlooked. Properly positioned processing lines is a critical step when reconstructing all types of brain imaging and if not done properly can affect what the reconstructed images look like. Proper reconstruction processing techniques are based on the intercommissural (ICL) line. The (ICL) passes through the center of the anterior and posterior commissure. The anterior commissure and posterior commissure line (AC-PC line) pass through the superior surface of anterior commissure and the center of the posterior commissure. Figure 6 illustrates where the AC-PC line and the ICL are located and as mentioned are commonly used to help consistently position patients' brains during the processing of all types of brain imaging be it in Nuclear Medicine for both SPECT and PET as well as MRI and CT (11).

Not using the ICL, AC-PC line and other reference images such as the coronal image to correctly position the brain during processing can lead to poor quality images. Incorrectly positioning the processing lines when processing any brain scan can be an issue. With FDG or amyloid imaging, incorrect line placement can result in seeing different regions of the brain before the other, i.e. seeing the frontal lobes before the lateral temporal lobes. If lateral head tilt

is not adjusted properly during processing poor image quality can also result; see Figure 5b for poor images due to head tilt. With a DaTscan study, incorrectly positioned processing lines can make a normal scan look abnormal, so care needs to be taken when processing these types of scans. Figure 6ab illustrates the correct and incorrect way to position processing lines when reconstructing a DaTscan study.

Another important component related to the processing of images that can affect image quality is the filter settings used and whether or not the images are processed using filter back projection or iterative reconstruction. When performing amyloid imaging the “Out of the Box” preset filter settings for the brain protocol on the scanner is usually fine to use; however, filters can be changed if the interpreting physician feels the images need to be smoother or have more contrast. It is important that once a filter setting is chosen that it is used consistently and not changed. DaTscan filter settings also need to be set properly; selecting a cutoff setting that is too low say a .2 will make the images look too smooth and selecting a cutoff setting that is too high say a .6 will cut out too many counts and the image will look too grainy. Figure 7 illustrates what a DaTscan study looks like with different filter settings. A good cutoff filter setting to use is between a 0.4 and a 0.5 but depends on what the interpreting physician’s feels is the best setting based on their liking. It is important to note that each SPECT camera manufacturer is different, and it is up to the interpreting physician to decide what the correct filter setting should be.

The color display used when displaying brain scan images can also influence image quality. Each manufacturer and their radiopharmaceutical package insert prescribing information will usually recommend a particular color display that should use when interpreting images. If no recommendation is given as to the color scale to use it is important for the

interpreting physician to be consistent with whatever color scale they choose to use. Using a color scale that does not provide enough color scale gradient could make a physician over-read a scan because there is not enough color scale gradient within the image to interpret properly.

### *Considerations and Adjustments*

As healthcare professionals, we want to provide patients with optimal quality through the entire procedure from beginning to end but sometimes for whatever reason things happen, and their experience and image quality can be negatively affected. Issues that could affect optimal quality include the camera going down, and the patient or dose arriving late. We want to make sure we utilize appropriate imaging techniques and protocols to ensure the highest image quality possible. We want to make sure we can recognize potential sources of errors that could cause artifacts and learn how to correct them if possible or find an alternative way to correct the issue. We want to make sure we communicate any out of the ordinary issues that might arise to the nuclear medicine physician, so they can make the appropriate discussion on how to proceed. A good example of that would be, a patient arrives late and the dose to be injected into the patient is slightly out of its prescribed dose range so technically you should not inject the dose...Do you cancel the scan and waste a very expensive PET radiopharmaceutical, or do you inject the patient and perform the scan anyway? It's up to the nuclear medicine physician on whether to proceed or not. If the nuclear medicine physician says its ok to proceed and inject the patient than its important for the NMT to know to increase the scan time slightly to ensure enough counts are acquired to get a good quality scan.

Other things to consider is that we want to make sure we always “Do the right thing” even if it is “not your job,” we should do it anyway or assist with finding someone who can help. Maybe you are a senior technologist, and a less experienced technologist is processing a brain

scan, and you notice they are doing something wrong; jump in and use this as a teaching moment to help them learn. It's important that if you see something, say something! We always want to do the right thing for the patient and make sure we use dose optimization to help eliminate unnecessary scans.

### ***Image Interpretation and Reporting***

Image interpretation and reporting is the final step in the quest for the best quality brain images possible. We as NMTs can do everything right on our end at positioning, acquiring and displaying the best images but if the interpreting physician misreads something or leaves something out of a report, the quality of the scan will be affected. Interpreting physicians should review the radiopharmaceutical package insert information, equipment/software manufacturers instructions and professional organizations as related to the images they are interpreting; as well as taking any necessary required training (i.e. amyloid imaging). If anyone (technologist or physician) has any questions, they should reach out to the camera manufacturer and/or clinical applications specialists to help optimize camera settings or to the radiopharmaceutical manufacturer about the use of the radiopharmaceutical, all to ensure the highest quality images are acquired, processed, displayed and interpreted.

Another important step during the interpretation process is to make sure the interpreting physician reads images in the appropriate color scale if required as mentioned previously. Making sure the dictated report has all the necessary contents in the report is also important to achieving the highest quality scan. For amyloid imaging, refer to Section VI of the Society of Nuclear Medicine and Molecular Imaging (SNMMI) Procedure Standard-European Association of Nuclear Medicine (EANM) Practice Guideline for Amyloid PET Imaging of the Brain for reporting guidelines for all necessary components that need to be included in a report (13).

Another helpful document for interpreting physicians as well as ordering physicians and NMTs regarding amyloid imaging is the Appropriate use criteria for amyloid PET (14). Both documents provide useful information on all aspects of amyloid imaging ensuring the highest quality amyloid images possible if followed properly. For FDG and DaTscan imaging refer to the SNMMI Imaging Guidelines (15,16). It is important for the NM Physician to report any abnormal finding to Neurologist/Ordering Physician as soon as possible.

***Checklist to Position, Acquire and Display the BEST Brain images possible every time***

The biggest thing we can do as NMTs and interpreting physicians is to make sure we are positioning, acquiring, displaying and interpreting the “BEST” brain images possible every time is to practice consistency in everything we do. If something happened during the positioning of the patient out of the ordinary, communication with the interpreting physician is important letting them know there was a problem. Consistency and communication is key to achieving the best quality brain images every time. Another thing that can help us position, acquire, display and interpret brain images is to have a checklist that we can follow to reminder to do the same thing every time. Below is a checklist to follow with some reminders to help you position, acquire, display and interpret the best brain images possible.

1. Follow all package insert prescribing information for the radiopharmaceutical you are using.
2. Explain to the patient the importance of following instructions and being still.
3. Empty patient bladder immediately prior to imaging.
4. Position the patient comfortably on the table and head comfortably in the head holder
5. Secure patient’s head using the head strap and chin strap - regardless if the patient states they can hold still! If extra time is needed to make sure the patient is comfortable on the imaging table take the extra time to make sure they are as comfortable as possible
6. Use positioning lasers to make sure patient’s head is straight and in the FOV
7. For SPECT images – Make sure you get the camera radius as close as possible to the patient’s nose (11cm to 15 cm). Clearing the patient’s shoulders is critical to check.
8. Stay with patient to watch for movement
9. Review raw data images prior to patient leaving to look for movement



10. Review reconstructed images for patient motion; do not rely on auto processing
11. If head looks tilted - manually adjust processing lines accordingly using AC/PC commissure lines
12. Use correct filter cutoff and display settings
13. Communicate with the interpreting physician anything out of the ordinary regarding the patient or scan

### ***Conclusion***

Nuclear Medicine brain imaging is being utilized by more and more physicians across the country to evaluate many different brain pathologies including the presence or absences of amyloid plaque, differentiating movement disorders such as Essential Tremor and Parkinson's disease and many other neurological disorders. Many factors can affect brain image quality; following the appropriate imaging technique and required standards per the radiopharmaceutical's package insert prescribing information is necessary to achieve optimal image quality as well as accurate and reliable image results.

There are many critical steps in acquiring good quality brain images. Patient positioning is one of the first technical critical steps in acquiring any good quality brain image. It is important to take the extra time if needed to thoroughly explain the procedure to the patient and position them on the imaging table, so they are as comfortable as possible. When it comes to DaTscan imaging, the camera radius is another critical technical step that can affect imaging quality if not followed properly. The camera heads should be positioned between 11 and 15 cm. Improper head position during acquisition or brain slice orientation during processing can also decrease image quality which could lead to improper interpretation by nuclear medicine physician.

The best way to make sure you achieve the highest quality brain images is to be technically consistent in every aspect of a patient's scan. Each area of quality - administrative, technical and interpretative can influence the other and if not followed properly can affect image

quality. Following all administrative and technical guidelines but not following image interpretation guidelines can still result in a poor-quality result for the patient. Image interpretation is only as good as the quality of the images obtained. Successful patient management, treatment, and outcomes can be directly related to the quality of the images and the interpretation of the scan. Remember NMTs have a huge role to play in making sure the highest quality brain images are achieved. To help achieved this goal, make it personal so that every brain scan you perform you perform it as if it were on your family member helping ensure that the highest quality images will be achieved; allowing us to achieve the Healthcare quality Dr Clancy discussed during her testimony to Congress – *“Healthcare quality is getting the right care to the right patient at the right time – every time”*(6).

**Financial Disclosures:** The author received no funding for this research.

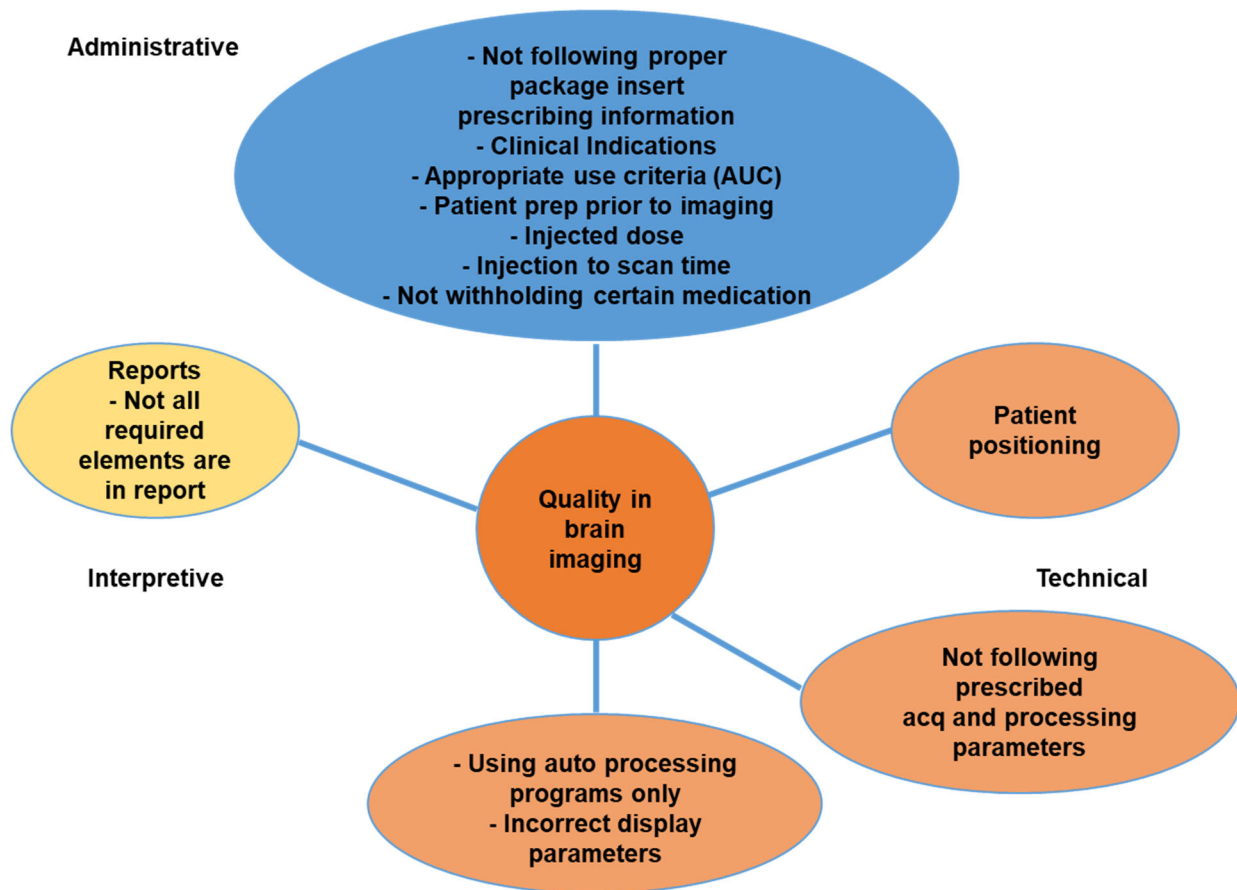
**Disclaimer:** Author Grabher is CEO of Grabher Consulting & Specialty Services and an employee of Life Molecular Imaging, Inc. (f.k.a. PIRAMAL Imaging), Boston, MA. No other potential conflict of interests relevant to this article was reported.

**Acknowledgment (s):** I would like to thank Mary Beth Farrell for her editorial assistance with this article. I would also like to mention that the information outlined in this article was presented at the Society of Nuclear Medicine and Molecular Imaging Annual Meeting held in Philadelphia, Pennsylvania, on June 23, 2018.

## References

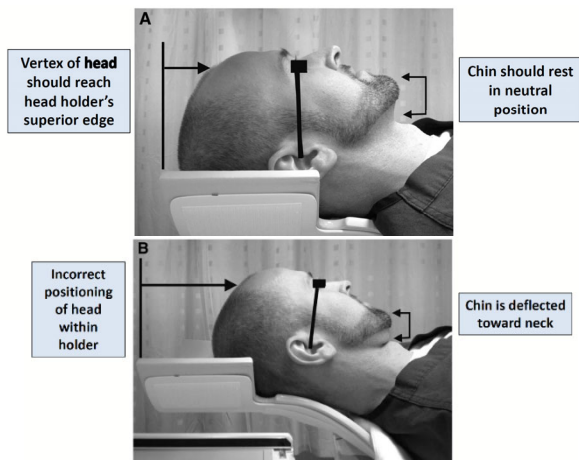
1. Future Market Insights Global and Consulting Pvt. Ltd., Molecular Imaging Market to be worth US\$ 6,445.8 Mn by 2027 with CAGR 7.5% - Future Market Insights. (Dec. 20, 2017) Retrieved from <https://globenewswire.com/news-release/2017/12/20/1266788/0/en/Molecular-Imaging-Market-to-be-worth-US-6-445-8-Mn-by-2027-with-CAGR-7-5-Future-Market-Insights.html> Accessed on April 26, 2018.
2. BD Business Directory (2018) Retrieved from <http://www.businessdictionary.com/definition/quality.html> Accessed on April 26, 2018.
3. What Is Six Sigma? Retrieved from <http://asq.org/public/six-sigma-training/asqsigma.pdf> Accessed on April 26, 2018.
4. Chi Solutions Inc. (October 2008) [https://www.chisolutionsinc.com/wp-content/uploads/2015/01/2008\\_10\\_Lean-Newsletter-Article.pdf](https://www.chisolutionsinc.com/wp-content/uploads/2015/01/2008_10_Lean-Newsletter-Article.pdf) Accessed on April 26, 2018.
5. Evans, MH. Reaching for Six Sigma [http://www.exinfm.com/board/reaching\\_for\\_six\\_sigma.htm](http://www.exinfm.com/board/reaching_for_six_sigma.htm) Accessed on April 26, 2018.
6. What is Healthcare Quality and who decides? Hearing before the subcommittee on Healthcare of the Committee on Finance United States Senate One hundred eleventh Congress – First Session, March 18, 2009. S. HRG. 111–848. <https://www.finance.senate.gov/imo/media/doc/640431.pdf> Accessed March 25, 2018.
7. Sajdak, R., Trembath, L., and Thomas, K. The importance of standard operating procedures in clinical trials. *J Nucl Med.* 2013;41: 231-233.
8. Rosenthal, MS. et al. Quantitative SPECT Imaging: A review and recommendations by the Focus Committee of the Society of Nuclear Medicine Computer and Instrumentation Council *J Nucl Med.* 1995;36: 1489-15.
9. DaTscan [prescribing information]. Arlington Heights, IL: GE Healthcare; 2015.

10. Lanciego, JL., Luquin, N., and Obeso, JA. Functional neuroanatomy of the basal ganglia. *Cold Spring Harb Perspect Med.* 2012 Dec; 2(12): a009621. Retrieved from <https://www.ncbi.nlm.nih.gov/pmc/articles/PMC3543080/> . Accessed on April 28, 2018.
11. Trembath, A., and Opanowski, A., PET Imaging of the Brain for Technologists – Society of Nuclear Medicine and Molecular Imaging CTN Webinar Series 2016. Retrieved from [https://www.ideas-study.org/wp-content/uploads/2017/01/PET-Imaging-of-the-Brain-for-Technologists\\_04Apr16.pdf](https://www.ideas-study.org/wp-content/uploads/2017/01/PET-Imaging-of-the-Brain-for-Technologists_04Apr16.pdf) Accessed on April 28, 2018.
12. Mehrotra, S. Lean Six Sigma methodologies: How do they improve Health Care industry? (December 1, 2017). Retrieved from <https://www.greycampus.com/blog/quality-management/health-care-industry-can-reduce-wastage-by-these-lean-six-sigma-methodologies> Accessed on April 30, 2018.
13. Johnson, KA. et al., Appropriate use criteria for amyloid PET: A report of the amyloid imaging task force, the Society of Nuclear Medicine and Molecular Imaging, and the Alzheimer's Association. *J Nucl Med.* 2013;54: 476–490.
14. Minoshima, S. et al., SNMMI Procedure Standard-EANM Practice guideline for amyloid PET imaging of the brain 1.0, *J Nucl Med.* 2016;57:1316-1322.
15. Djang, D. et al., SNM Practice Guideline for dopamine transporter imaging with 123 I-Ioflupane SPECT 1.0\*, *J Nucl Med.* 2012;53:154-163.
16. Waxman, A. et al. Society of Nuclear Medicine Procedure Guideline for FDG PET brain imaging version 1.0, (February 8, 2009) Retrieved from <http://www.snmmi.org/ClinicalPractice/content.aspx?ItemNumber=6414> Accessed on August 2, 2018.



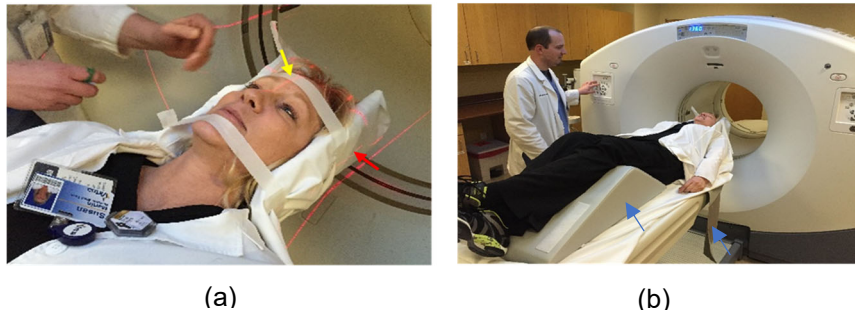**Figure 1 – Applying Quality in Brain Imaging** - Three areas of quality in imaging – Administrative (blue) quality, Technical (orange) quality, and Interpretative (yellow) quality and their components.

## Figure 2 for Brain Quality Manuscript

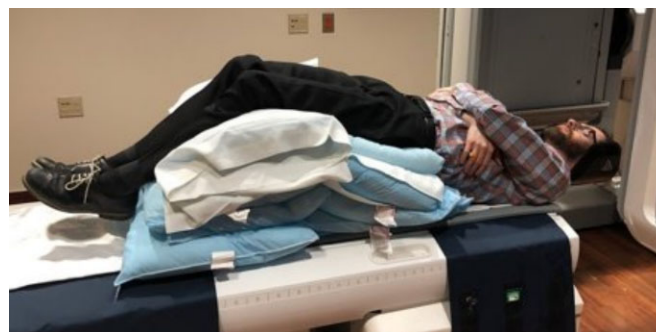


**Figure 2A** – Proper Patient head position in head holder. Cantho-meatal line is an imaginary line that runs from lateral corner of eye to the ear canal – indicated by thick black line in photo. Figure 2B Improper Patient head position in head holder. Cantho-meatal line is slightly deflected downward and not vertical and perpendicular to the imaging table.

Image used with permission – Covington et.al. J. Nucl. Med. Technol. 2013; 41:105-107

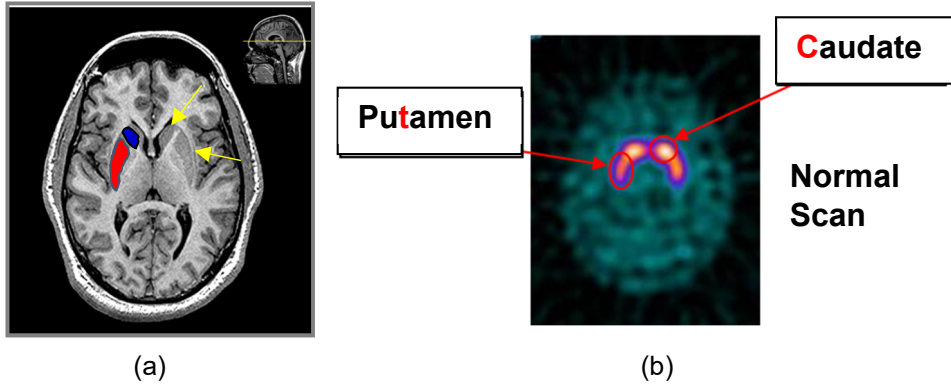


**Figure 3** – (a) Proper Patient positioning on the imaging table using the head strap, chin strap and laser lights - indicated by arrows. The yellow arrow highlights laser light that divides the head in half and should go through the center of the patient's nose and forehead. The laser light helps make sure the patient's head is not rotated. The red arrow highlights the laser which is positioned at the level of the patient's ear and helps position the scanner's table height so that the patient's head is positioned in the middle of the field of view. (b) The two blue arrows point out the body strap and knee cushion. A blanket to cover the patient may also be helpful to keep the patient warm during the scan  
 Images courtesy of Barbara J Grabher and used with permission by Virtua Health, Voorhees, NJ.

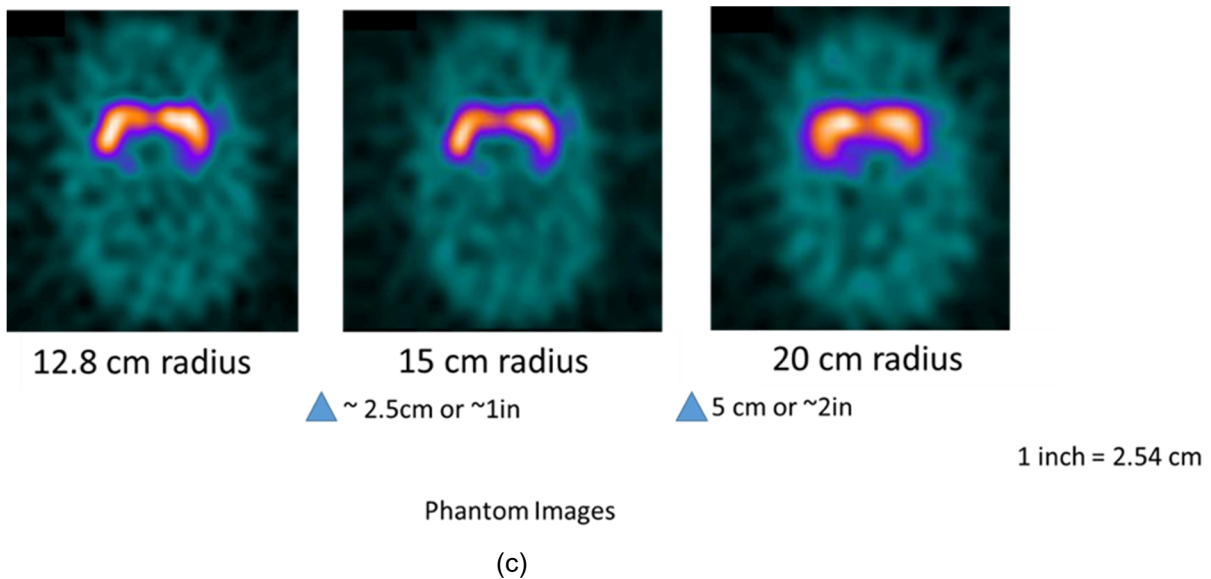


**Figure 3c – Patient positioning challenge** – Patient with kyphosis, neck or severe back pain. Place multiple pillows under the patient's legs, buttock and low back to help patient lay flat on imaging table for scan. It is important to use body straps to make sure patient is secure on imaging table and does not fall off. (Image from SNMMI DaTscan QA Presentation - 2018 Annual Meeting – Philadelphia, PA)



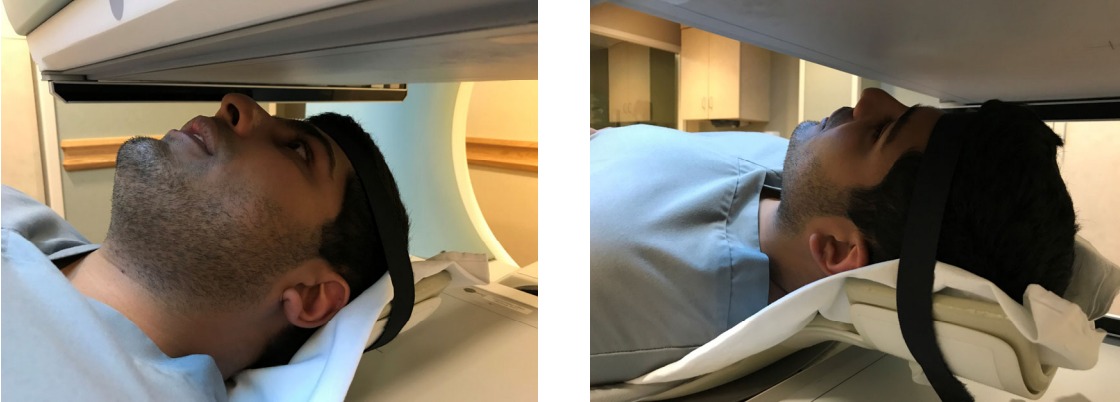


**Figure 4 – Key DaTscan Positioning considerations** - Location of caudate nucleus and putamen within the brain (a) on an MRI - Blue shaded structure - Right caudate, Red shaded structure Right putamen. The left caudate and putamen are not shaded but are indicated by the two yellow arrows. (b) Transverse slice of DaTscan image. A simple way to explain the location of these structures to a patient is to say if you draw an imaginary line through your ears and through your nose where the two lines cross is where the caudate and putamen are located. (Images courtesy of Holy Name Hospital, Teaneck, NJ)

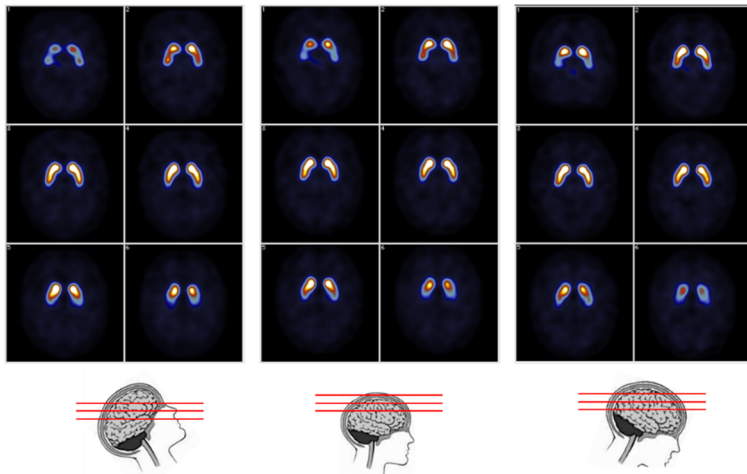


**Figure 4c** - Effect of increasing camera radius on DaTscan image quality (a) 12.8 cm radius. (b) 15.0 cm radius and (c) 20.0 cm radius. As the camera radius increases image quality decreases. Notice the 20 cm radius image and how the putamen looks shorter and not as well defined as they do on the 12.8cm image. (Images used with permission from Liz Clarke)

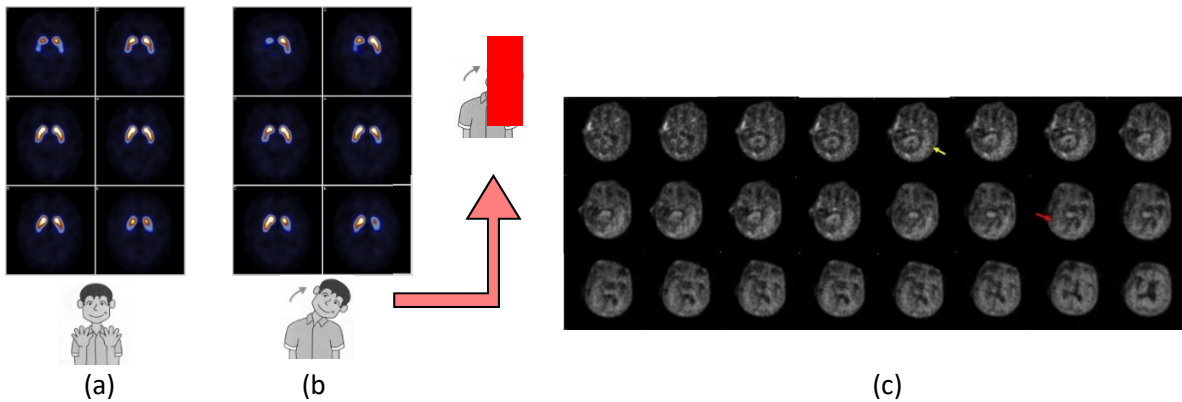
**Figure 4d** – Photos showing how close the camera head must be when positioning for a DaTscan study. The camera head must be as close as possible to the patient's nose to insure the best image quality. The camera head must also clear the patient's shoulders.



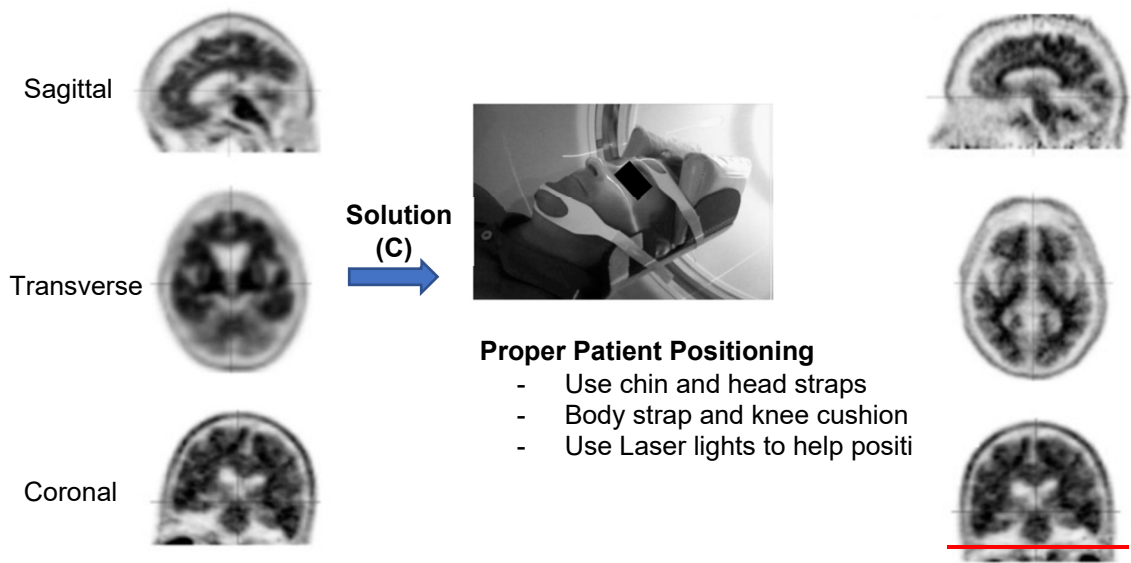
(Image used with permission – Barbara J Grabher and Holy Name Hospital, Teaneck, NJ)



**Figure 5a** – Effect of head orientation on DaTscan imaging – There is no effect on image quality with a forward or backward head tilt. Image quality is not affected with sagittal head tilt (Images courtesy of Glasgow Southern Hospital)



**Figure 5b** – Effect of lateral head tilt orientation on DaTscan images - (a) no head tilt and (b) Lateral head tilt. With lateral head tilt you see one putamen before the other putamen making the images difficult to interpret. (c) Lateral head tilt with Amyloid imaging. Yellow arrow indicates the visualization of the left lateral temporal lobe. The right lateral temporal lobe is visualized almost 10 frames later indicated by the red arrow. (Images courtesy of Liz Clarke and Piramal Imaging)



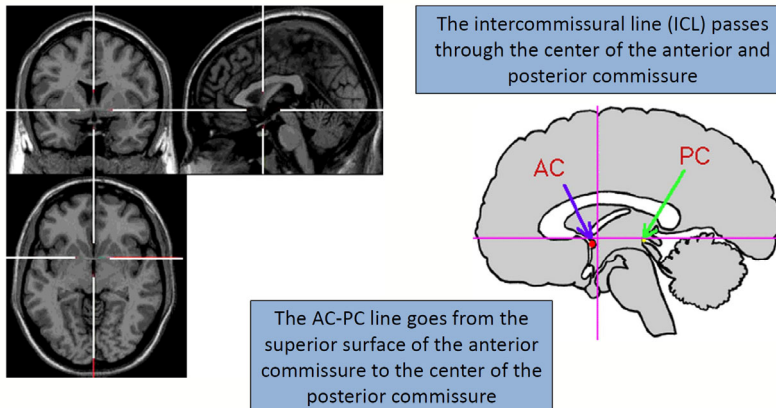
**(A)** Improper head orientation during processing

**(B)** Proper head orientation during processing

**Figure 5c** – Illustration of Improper and Proper head orientation during brain image processing – In sagittal slice A – head is tilted too far forward and in coronal slice A the head is tilted toward the right. The patient’s head position can be corrected during processing, but the best solution is correctly position the patient and the patient’s head during set up as shown in Solution C. The red line in coronal slice (B) helps you know the patient’s head is properly positioned and once processed will result in properly oriented brain images for display. Improperly positioned images during processing could lead to an interpreting physician mis-interpreting images when reading the final images displayed by the NMT.

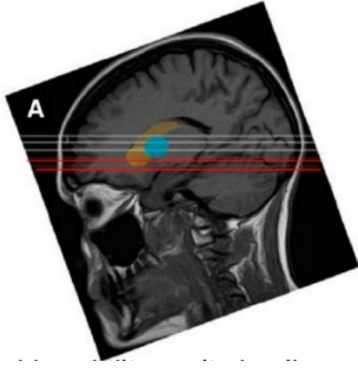
Images used with permission - PET Imaging of the Brain for Technologists – SNMMI CTN Webinar Series 2016  
 LisaAnn Trembath and Adam Opanowski.

## Intercommissural line (ICL)

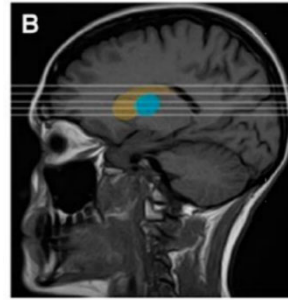


**Figure 6** – Location of the Intercommissural line (ILC), Anterior commissure (AC) and Posterior commissure (PC) line. Proper reconstruction processing techniques are based on the intercommissural line. The ICL passes through the center of the anterior and posterior commissure. The anterior commissure and posterior commissure line (AC-PC line) pass through the superior surface of anterior commissure (purple arrow) and the center of the posterior commissure green arrow). The AC-PC line and the ICL are commonly used to help consistently position patients' brains during the processing of all types of brain imaging be it in Nuclear Medicine for both SPECT and PET as well as MRI and CT.

Images used with permission - PET Imaging of the Brain for Technologists – SNMMI CTN Webinar Series 2016 LisaAnn Trembath and Adam Opanowski.



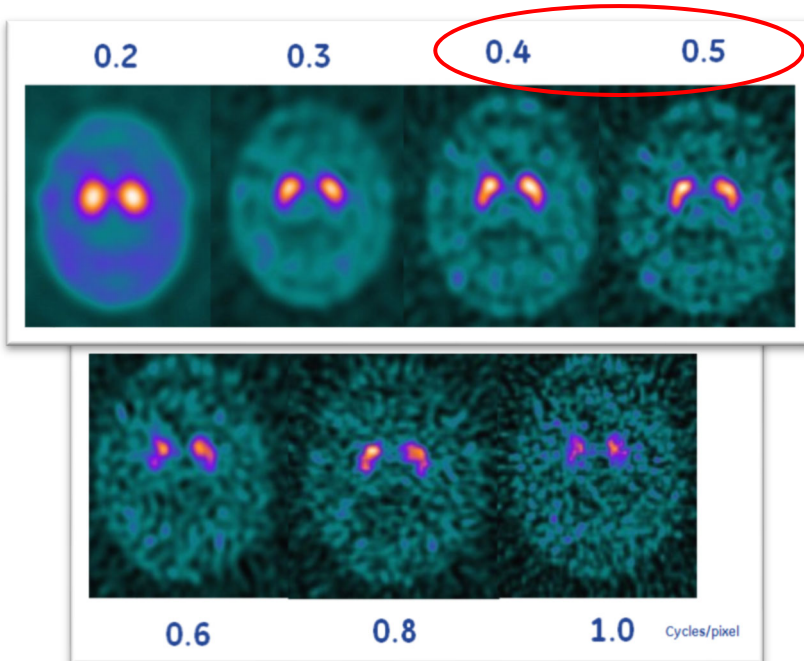
Improper line placement during processing



Proper line placement during processing

**Figure 6A and B** – MRI study of the brain showing (A) incorrectly and (B) correct positioned processing lines. Forward head tilt in (Image A) results in slices (red lines) through caudate head that do not include the putamen. With correct positioning (Image B) - all slices through caudate head also include putamen (White lines in Image B). Even though we do not use an MRI scanner for DaTscan imaging; it is important for the NMT to understand proper line placement during DaTscan SPECT processing. A normal scan can look abnormal if processing lines are incorrectly positioned. Care must be taken when processing DaTscan images so no false positive images are reconstructed and the highest image quality is given to the interpreting physician to interpret.

Images used with permission – Convington et.al. J Nucl Med Technol 2013; 41 :105-107



Phantom Images

**Figure 7** – DaTscan study with different filter settings. A good cutoff filter setting to use is usually between a 0.4 and a 0.5. It is important to note that each SPECT camera is different, and it is up to the interpreting physician to decide what the correct filter setting should be. Once a filter setting is chosen it is important to consistently use that filter setting so the interpreting physician gets used to seeing similar processed images using the same filter settings. Changing filter setting for each study is not recommended.

Images used with permission by Liz Clarke

### Tables for Brain Quality Manuscript

Examples of Profitability for Healthcare Organizations by implementing Six Sigma/LEAN Quality Improvement Projects to eliminate waste and insufficiencies		
Hospital	Event	COST
<b>Boston Medical Center</b>	An emphasis on diagnostic imaging was initiated.	Brought cost savings and revenue increases of more than \$2.2 million.
<b>Rapides Regional Medical Center</b>	Reduce defects in its emergency department.	Wait times dropped; Providers saw more patients; Saved more than \$950,000 annually.
<b>Valley Baptist Health System</b>	Reduced surgery cycle time.	Helped hospital to add adequate capacity to handle 1,100 more cases per year. Increased potential annual income by \$1.3 million.
<b>Yale-New Haven Medical Center</b>	Many Six Sigma projects implemented in the surgical intensive care unit.	Lead to a 75% reduction in bloodstream infections which in turn resulted in an estimated \$1.2 million in annual savings.
<b>Other types of Six Sigma Healthcare Projects include:</b> Reduce noise at Night, Reduce Hospital Readmissions, Reduce OR Cancellations, Improve Pain Management, Improve Call-bell response time, Improve Discharge Process, Improve Medication Education, Improve ED Patient Flow, Improve Rehab Patient Satisfaction – All lead to improved quality of care for patients and a stronger more financially secure healthcare organization.		

**Table 1** - Examples of Healthcare Organization's profitability by eliminating waste and insufficiencies within the Healthcare System by using Six Sigma/LEAN Quality Improvement Projects (12)



Project	Purpose
<b>Analyze report generation times</b> - From time study was ordered by Physician to when Physician received final report	Decrease report generation times Physicians must wait to get reports on scans they have ordered on their patients
<b>Analyze Patient escort times</b> to and from Nuclear Medicine department	On time arrivals of patients help department run more efficiently and enables department to scan more patients. Analysis also helps make sure Escort department is properly staffed
<b>LEAN/Six Sigma 5S Kizan Events</b>	To decrease waste and improve efficiencies within imaging department

**Table 2** – Examples of possible Six Sigma Projects in Radiology/Nuclear Medicine Department and their purpose