

The appearance of Maffucci's Syndrome by Combined F-18 FDG PET/CT

Sayf Al-Katib, Zaid Al-Faham, Paul Grant, Jane C. Palka.

Department of Diagnostic Radiology and Molecular Imaging

Oakland University William Beaumont School of Medicine

Please direct all Correspondence to:

Zaid Al-faham

William Beaumont Hospital

3601 W. 13 Mile Road

Royal Oak, MI 48073

P: (+1) 248-898-4126

F: (+1) 248-898-0768

Key words: Maffucci's Syndrome, F-18 FDG PET/CT, enchondromas

Word count: 708

Abstract:

Maffucci's Syndrome is a rare condition with multiple enchondromas and hemangiomas. Fewer than 200 cases have been reported in the United States. There is a high predilection for neoplastic changes; therefore PET/CT scan has an important role in detecting these changes.

Introduction:

Maffucci's Syndrome is a rare condition with multiple enchondromas and hemangiomas. Fewer than 200 cases have been reported in the United States. To our knowledge this is the second case report that shows the appearance of Maffucci's Syndrome on PET/CT scan.

Case report:

45 year old male with history of Maffucci's syndrome. Right knee x-ray was performed because of knee pain (figure 1). A restaging F-18 FDG PET/CT for chondrosarcoma was ordered. Sixty minutes after intravenous administration of 16.56 mCi (61272 becquerel) of F-18-fluorodeoxyglucose (FDG), sequential unenhanced CT and then PET images were acquired. A PET/CT scan shows multiple osseous lesions that have similar appearance. A benign etiology, such as an enchondroma would be highly favored over an aggressive tumor (figure 2). Also, there are multiple soft tissue nodular densities seen throughout the subcutaneous tissues; there was no abnormal FDG uptake within the lesions, favoring the benign etiology, hemangiomas (figure 3). Several of the subcutaneous nodules located in the right-sided abdominal wall demonstrate punctate calcifications. These represent phleboliths, a typical finding of hemangiomas. Abnormal FDG uptake within a subcutaneous nodule would raise concern for malignant transformation to hemangiosarcoma.

Discussion:

Maffucci's Syndrome is a rare condition with multiple enchondromas and hemangiomas. Fewer than 200 cases have been reported in the United States (1). If a patient has multiple enchondromas, without hemangiomas, then the condition is known as Ollier disease. Maffucci's syndrome is a congenital nonhereditary condition. It usually presents before the onset of puberty and is often located within the long bones. It has been estimated that

approximately 25-30% of the enchondromas develop into a chondrosarcoma(2,3).

The average age for neoplastic change from an enchondroma to chondrosarcoma in Maffucci's Syndrome patients is 40 years old. There is also an increased risk of malignant transformation of hemangiomas into hemgiosarcomas and hemangioendotheliomas(4). An SUVmax above 2.0 can be used to distinguish benign from malignant cartilaginous tumors with 90.9% sensitivity, 100% specificity and 96.6% accuracy (5).Maffucci's syndrome is often distinguished from Ollier disease by physical examination. The presence of red or purplish growths in the skin would be consistent with a hemangioma. Affected individuals can also have lymphangiomas.

Conclusion:

Maffucci's syndrome is a congenital nonhereditary rare condition. There is a high predilection for neoplastic changes; therefore PET/CT scan has an important role in detecting these changes.

References:

1. Faik A, Allali F, El Hassani S, Hajjaj-Hassouni N. syndrome: a case report. *Clin Rheumatol*. 2006;25 :88-91.
2. Lewis RJ, Ketcham AS. Maffucci's syndrome: functional and neoplastic significance. Case report and review of the literature. *J Bone Joint Surg Am*. 1973;55:1465-79
3. Makis W, Hickeson M, Lisbona R. Maffucci syndrome with extraosseous chondrosarcoma imaged with F-18 FDG PET-CT. *Clin Nucl Med* 2010;35:29–31
4. Zwenneke Flach H, Ginai AZ, Wolter Oosterhuis J. Best cases from the AFIP. Maffucci syndrome: radiologic and pathologic findings. *Armed Forces Institutes of Pathology. Radiographics*. 2001;21:1311-6.
5. Morimoto S, Futani H, Tsuchiyama K, Fukunaga S, Tsukamoto Y, Yoshiya S. Usefulness of PET/CT for diagnosis of periosteal chondrosarcoma of the femur: A case report. *Oncol Lett*. 2014; 7: 1826–1828.

Figure 1.

Right knee radiograph demonstrates marked deformity of the distal femur and proximal tibia and fibula. There are expansile lucent lesions with cortical thinning and calcified matrix are consistent with chondroid type lesions. The presence of multiple chondroid lesions is consistent with Maffucci's syndrome in patients who have the characteristic bluish subcutaneous hemangiomas on physical examination.

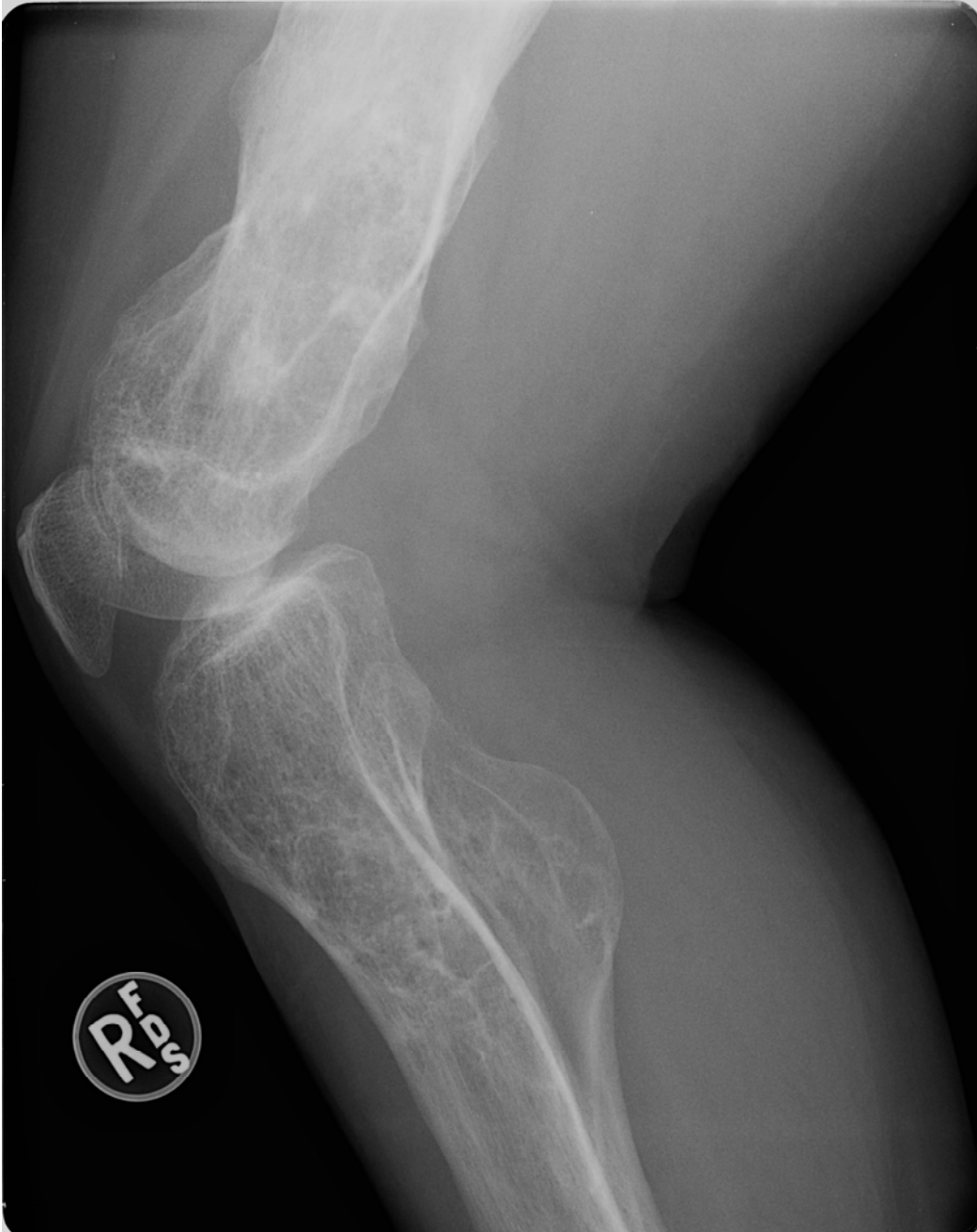

Figure 2

A combined F-18 FDG PET/CT scan demonstrating only mild FDG uptake in the right hemipelvis. The SUVmax is 1.8, similar to the surrounding osseous structure.

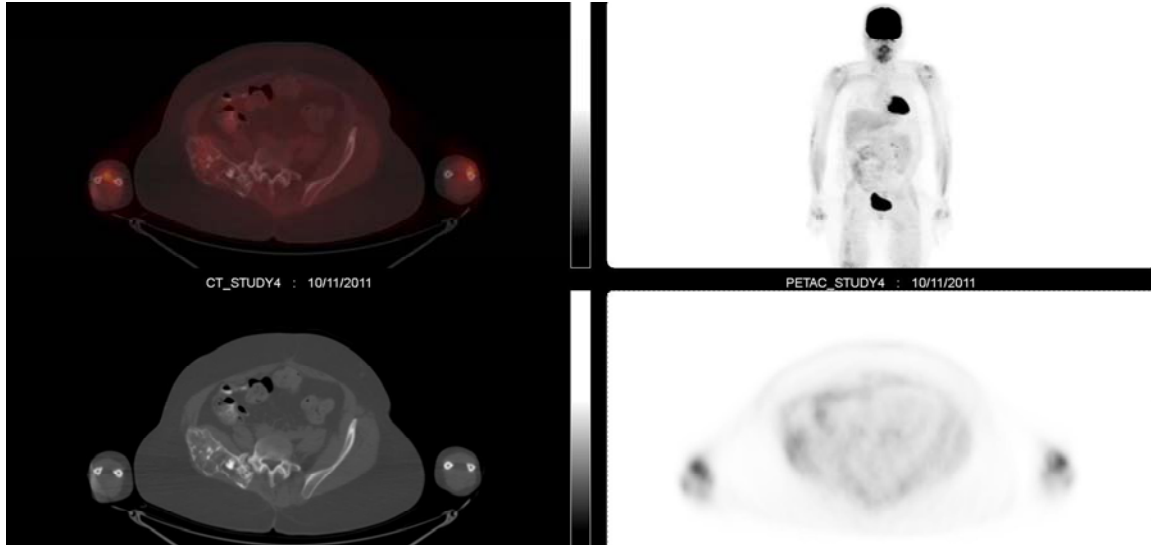


Figure 3

The PET/CT scan demonstrated multiple soft tissue nodular densities seen throughout the subcutaneous tissues; phleboliths.

