Case of the Quarter

Leo R. LaRocque

Hartford Hospital, Hartford, Connecticut

Case History

A 39-year-old female was admitted to the hospital for clinical evaluation and followup examinations with a prior diagnosis of carcinoma of the breast. She had received chemotherapy from the oncology center of the hospital.

For reprints contact: Leo R. LaRocque, Dept. of Clinical Nuclear Medicine, Hartford Hospital, Hartford, CT 06115.

Liver-spleen and bone scans were ordered to rule out breast metastases. The bone scan was performed and compared to the previous scan dated ten months before. Both were read as normal. The following day a four-view scintillation camera study of the liver and spleen was performed following the intravenous administration of 3 mCi of Tc-99m sulfur colloid (Fig. 1). When the 70-mm images were developed and mounted, a small area of increased radioactivity exhibiting a crescent shape was noted in the lower central portion of the anterior image (Fig. 2).

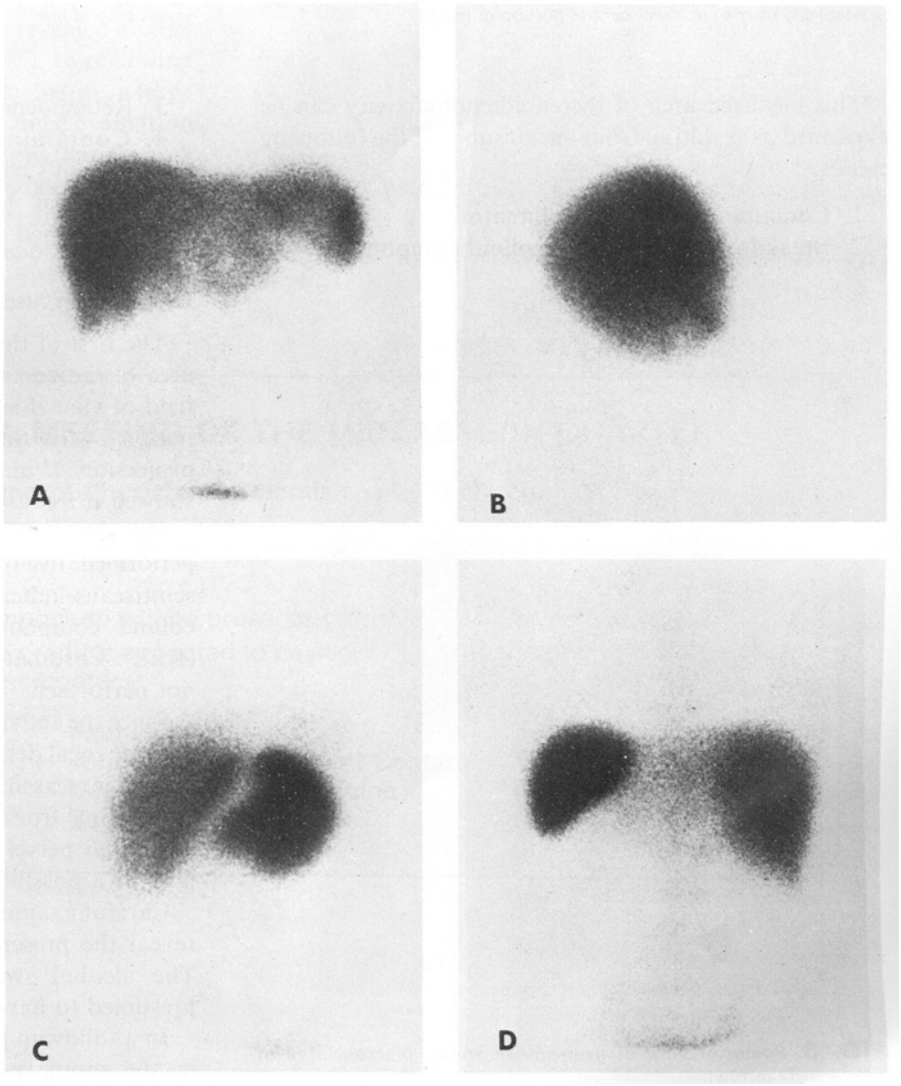

FIG. 1. (A) Anterior view of liver-spleen. (B) Right lateral view of liver. (C) Left lateral view of liver and spleen. (D) Posterior view of liver-spleen.

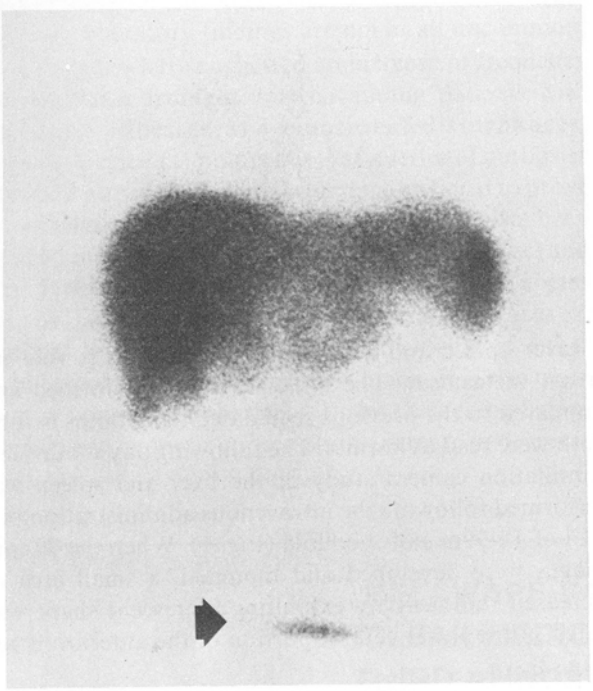

FIG 2. Anterior view of liver-spleen showing crescent shape area of radioactivity (arrow) in lower central portion of image.

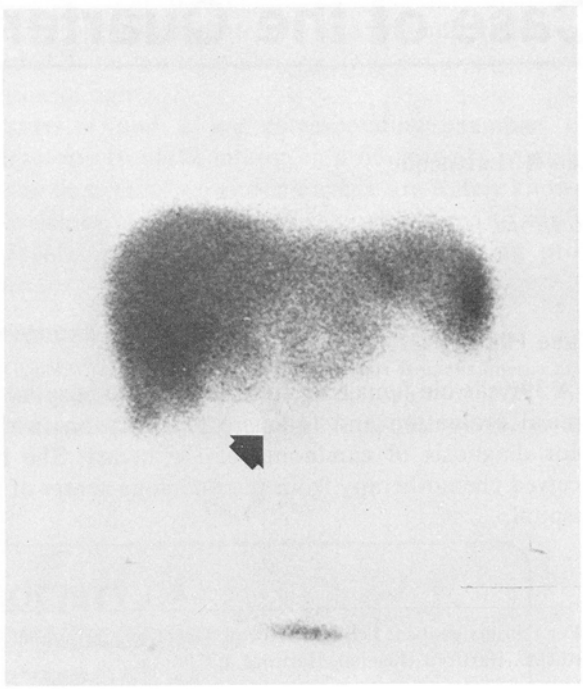

FIG 4. Anterior view of liver-spleen shows discrete focal defect (arrow) in left lobe of liver.

This localized area of increased radioactivity can be explained as resulting from one or more of the following causes:

1. Contamination of the collimator.
2. Breakdown in the sulfur colloid compound.
3. Reticuloendothelial system (RES) dysfunction.
4. Contaminated alcohol swab lodged into the patient's clothing.
5. Residual bladder activity from the bone scan performed one day earlier.

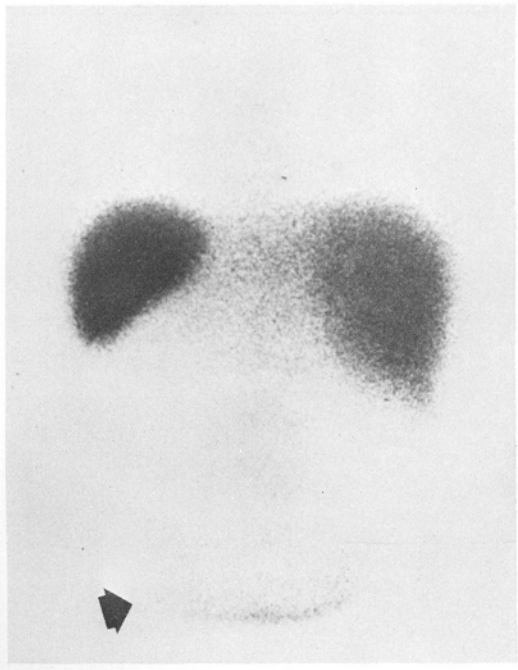

FIG. 3. Posterior view of liver-spleen shows discrete area of radioactivity (arrow).

Discussion and Solution

The first of these causes is unlikely, since the discrete area of radioactivity in the central lower portion of the field of view does not appear on the other scintigraphic images, with the possible exception of the posterior projection (Fig. 3). Examination of the collimator showed it free from radioactive contamination.

On the morning this particular procedure was performed, five other patients earlier received liver-spleen scintiscans indicating normal phagocytosis of the sulfur colloid compound by the reticuloendothelial system (RES). Chromatographic analysis of the compound was not performed.

Since the activity in the liver appears nonuniform and a discrete focal defect was noted in the left lobe (Fig. 4), the area of increased activity could possibly be bone marrow originating from the sacroiliac region. Note that both spine and pelvis are visible. Therefore, the third cause may be a possible choice.

Careful examination of the patient's clothing did not reveal the presence of any radioactive contamination. The alcohol swab could not be found and it was presumed to have been discarded prior to imaging.

In a followup procedure, the patient was again placed in the supine position for an anterior view with the

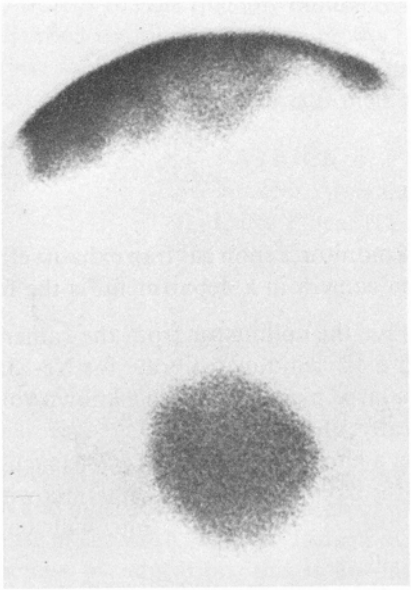

FIG. 5. Anterior view of abdomen and pelvis shows large rounded area of increased radioactivity.

scintillation camera positioned over the lower abdomen and pelvic area. The repeat scintiphoto revealed a large rounded area of increased activity (Fig. 5). In reviewing the bone scan that was performed the day before, a large distended bladder was noted which prevented evaluation of the sacrum (Fig. 6). It was then apparent that the area of increased activity noted on the liver-spleen scintiscan was caused by increased residual bladder activity due to the incomplete voiding of urine from the bone scan performed one day earlier.

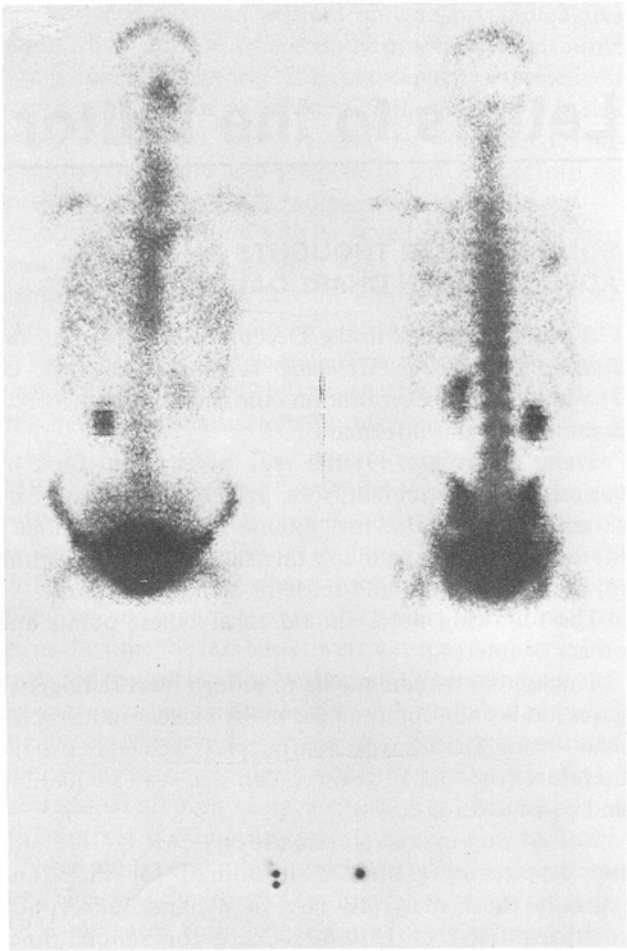

FIG. 6. Anterior and posterior view of bone scan performed one day earlier.