

^{18}F -FDG PET/CT Prediction of an Aggressive Clinical Course for Dermatofibrosarcoma Protuberans

Sandip Basu¹ and Fahim Goliwale²

¹Radiation Medicine Centre, Bhabha Atomic Research Centre, Tata Memorial Hospital Annexe, Mumbai, India; and ²Solapur Cancer Center, Solapur, India

The ability to assess tumor biology is a benefit of molecular imaging with ^{18}F -FDG PET/CT, which performs better than anatomic imaging in evaluating malignancies. We present an unusual case of fatal dermatofibrosarcoma protuberans, a usually indolent entity for which high-grade ^{18}F -FDG uptake was predictive of an aggressive clinical course unabated by tyrosine kinase inhibitor imatinib mesylate, to which the patient showed a poor response.

Key Words: FDG PET-CT; dermatofibrosarcoma protuberans; tumor biology

J Nucl Med Technol 2016; 44:88–89

DOI: 10.2967/jnmt.115.163212

Uptake of ^{18}F -FDG is a useful index of tumor biology and heterogeneity in several types of malignancy (1–3). Although the potential of this application of ^{18}F -FDG in PET/CT imaging has been postulated and published in multiple studies, its routine use in clinics continues to evolve. Here, we discuss a case in which a malignancy that typically is relatively indolent showed high ^{18}F -FDG uptake, which was subsequently found to be commensurate with increased metastatic potential and an aggressive disease course.

CASE REPORT

The patient was a 63-y-old man with left lumbar dermatofibrosarcoma protuberans, for which he had undergone a second surgery about 1 y previously because of local recurrence. In view of the recurrence, he had received local radiotherapy. Recently, he had presented with a left axillary mass for which ^{18}F -FDG PET/CT was performed to assess his whole-body disease status (Fig. 1). Multiple ^{18}F -FDG-avid well-defined lesions were seen bilaterally in the lung parenchyma (the largest, in the left lower lobe, measuring

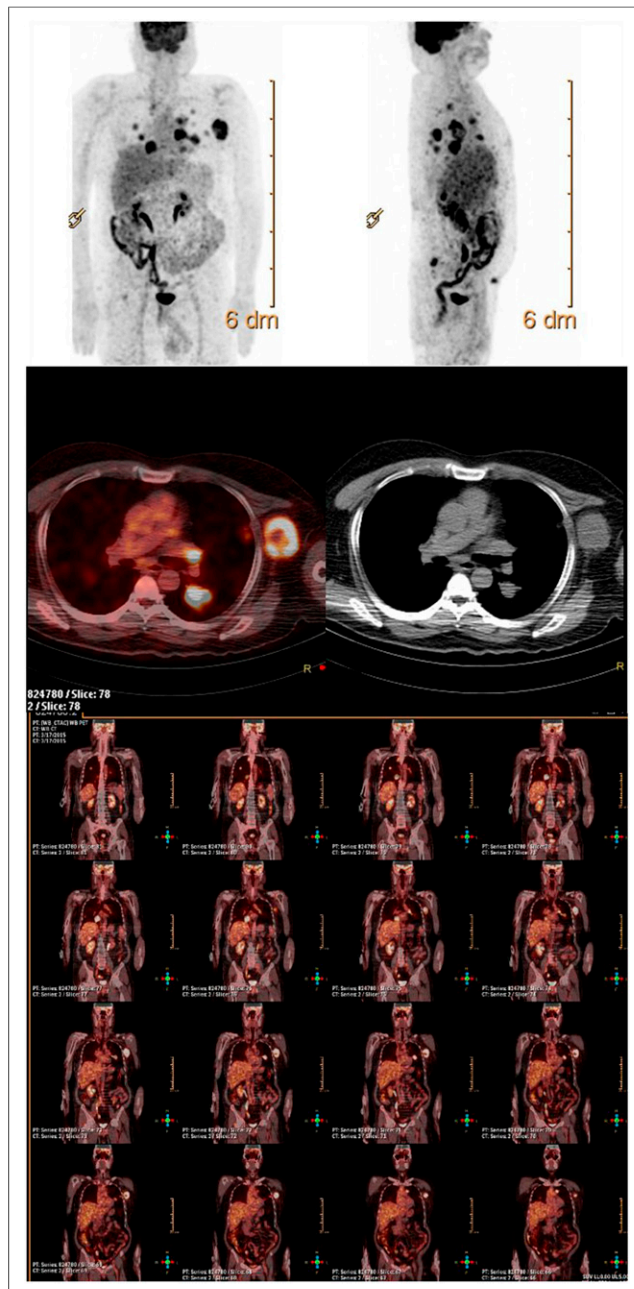


FIGURE 1. Maximum-intensity-projection (top), transaxial (middle), and coronal (bottom) ^{18}F -FDG PET/CT images showing high uptake in lung, soft-tissue, subcutaneous, and iliac lesions.

Received Jul. 2, 2015; revision accepted Jul. 24, 2015.

For correspondence or reprints contact: Sandip Basu, Radiation Medicine Centre, Bhabha Atomic Research Centre, Tata Memorial Hospital Annexe, Jerbai Wadia Rd., Parel, Mumbai, Maharashtra, India, 400 012.

E-mail: drsanb@yahoo.com

Published online Sep. 3, 2015.

COPYRIGHT © 2016 by the Society of Nuclear Medicine and Molecular Imaging, Inc.

4.2 × 2.8 cm and having an SUV_{max} of 14.38). Also noted was a large, well-defined soft-tissue mass in the left axilla (4.9 × 4.1 cm; SUV_{max}, 13.31), a subcutaneous nodule in the right anterior abdomen (2 × 2 cm; SUV_{max}, 5.82), and a sclerotic lesion in the right iliac bone (SUV_{max}, 7.40), all of which showed high ¹⁸F-FDG uptake. The patient was started on imatinib mesylate tyrosine, a kinase inhibitor approved for unresectable or metastatic dermatofibrosarcoma protuberans. Early PET/CT monitoring of the treatment was planned, but the patient's condition deteriorated rapidly and he died about 1 mo after beginning the therapy.

DISCUSSION

Dermatofibrosarcoma protuberans is usually a slow-growing tumor that behaves in a benign fashion. Although it can recur locally, it rarely metastasizes (incidence < 5%) and typically has a relatively good prognosis (4,5). Here, we have illustrated the imaging features of ¹⁸F-FDG PET/CT in an unusual case of dermatofibrosarcoma protuberans in which high-grade ¹⁸F-FDG uptake correctly predicted an aggressive course. The ability to depict tumor biology is a benefit of ¹⁸F-FDG PET/CT imaging (1–3), which performs better than anatomic imaging in evaluating malignancies. There have been a couple of reports (6,7) on the role of ¹⁸F-FDG PET/CT in detecting distant metastasis of dermatofibrosarcoma protuberans, highlighting the fact that metastasis of this entity, though rare, is possible. Two reports (8,9) have also illustrated a possible role for ¹⁸F-FDG PET/CT in monitoring the response of dermatofibrosarcoma protuberans to treatment with imatinib mesylate. However, to our knowledge there has been no specific literature on its role in predicting aggressive biology in individuals showing high uptake at the diseased sites.

CONCLUSION

As illustrated by this case, the ability to predict tumor biology is an important advantage of ¹⁸F-FDG PET/CT imaging that has the potential to form the basis of personalized medicine in oncology.

DISCLOSURE

No potential conflict of interest relevant to this article was reported.

REFERENCES

1. Jadvar H, Alavi A, Gambhir SS. ¹⁸F-FDG uptake in lung, breast, and colon cancers: molecular biology correlates and disease characterization. *J Nucl Med*. 2009;50:1820–1827.
2. Kwee TC, Basu S, Saboury B, Ambrosini V, Torigian DA, Alavi A. A new dimension of FDG-PET interpretation: assessment of tumor biology. *Eur J Nucl Med Mol Imaging*. 2011;38:1158–1170.
3. Basu S, Sirohi B, Shrikhande SV. Dual tracer imaging approach in assessing tumor biology and heterogeneity in neuroendocrine tumors: its correlation with tumor proliferation index and possible multifaceted implications for personalized clinical management decisions, with focus on PRRT. *Eur J Nucl Med Mol Imaging*. 2014;41:1492–1496.
4. Mendenhall WM, Zlotecki RA, Scarborough MT. Dermatofibrosarcoma protuberans. *Cancer*. 2004;101:2503–2508.
5. Rutkowski P, Debiec-Rychter M. Current treatment options for dermatofibrosarcoma protuberans. *Expert Rev Anticancer Ther*. 2015;15:901–909.
6. Suman S, Sharma P, Jain TK, Sahoo MK, Bal C, Kumar R. Recurrent dermatofibrosarcoma protuberans with pulmonary metastases presenting twelve years after initial diagnosis: ¹⁸F-FDG PET/CT imaging findings. *Clin Nucl Med*. 2014;39:77–78.
7. Al-Tamimi A, Zaheer S, Pierce CK, Osmany S, Sittampalam K. Recurrent dermatofibrosarcoma protuberans of the shoulder with rare distant abdominal metastasis detected by fluorodeoxyglucose-positron emission tomography/computed tomography (FDG-PET/CT). *Sultan Qaboos Univ Med J*. 2012;12:371–374.
8. Rubin BP, Schuetze SM, Eary JF, et al. Molecular targeting of platelet-derived growth factor B by imatinib mesylate in a patient with metastatic dermatofibrosarcoma protuberans. *J Clin Oncol*. 2002;20:3586–3591.
9. Mizutani K, Tamada Y, Hara K, Tsuzuki T, Saeki H, Tamaki K. Imatinib mesylate inhibits the growth of metastatic lung lesions in a patient with dermatofibrosarcoma protuberance. *Br J Dermatol*. 2004;151:235–237.