

Case of the Quarter

Artifact in Combined Lung Transmission-Liver Emission Scintiphotos

Marc Wojciechowski

Columbia Hospital, Milwaukee, Wisconsin

Case History

A 67-year-old woman with a history of splenectomy underwent a hemigastrectomy and Bilroth II gastrojejunostomy for upper gastrointestinal bleeding. Postoperatively she developed progressive respiratory distress and high fever. An abdominal abscess was suspected; a combined lung transmission-liver emission scan was order to rule out subphrenic abscess.

The patient arrived in our department with a nasogastric tube in place, although there was no suction being applied. Three millicuries of ^{99m}Tc -sulfur colloid was injected iv. Imaging was begun after 15 min using a Nuclear Data Camera with a parallel-hole collimator.

The patient was placed supine on a radiolucent cart and an anterior image of the dome of the liver was acquired. A flood source containing 10 mCi of ^{99m}Tc was placed under the patient and a transmission-emission image of the lung and liver was taken. Radioactivity below the left hemidiaphragm was noted [Fig. 1(A)]. The flood source was removed and another image was acquired showing no activity except in the liver [Fig. 1(B)]. The cause of the radioactivity is most likely:

1. Splenosis or accessory spleen.
2. Normal spleen.
3. Contamination of chest wall with ^{99m}Tc .
4. Flood source transmission through gastrointestinal gas.

5. Free technetium in stomach mucosa.

Solution and Discussion

It is known that the 140-keV gamma radiation of ^{99m}Tc will transmit through stomach or bowel gas to cause an image on a scintigraph (1). The stomach and the splenic flexure of the colon are in the area of the suspect radioactivity, and although a nasogastric tube was in place, it was not under suction. Also, the activity in question disappeared when the flood source was removed. Therefore, the correct answer is 4: flood source transmission through gastrointestinal gas.

Normal spleen activity is precluded by history since a splenectomy has been performed. Splenosis or accessory spleen imaging have been reported in the literature (2), but these, as well as chest wall contamination and free ^{99m}Tc in stomach, are emission images not dependent upon flood source placement.

References

1. Anger HO, McRae J: Transmission scintiphotography. *J Nucl Med* 9:267-269, 1968
2. Jacobson SJ, DeNardo GL: Splenosis demonstrated by splenic scan. *J Nucl Med* 12:570-572, 1972

For reprints contact: Marc Wojciechowski, Nuclear Medicine Section, Beloit Memorial Hospital, 1969 West Hart Road, Beloit WI 53511.

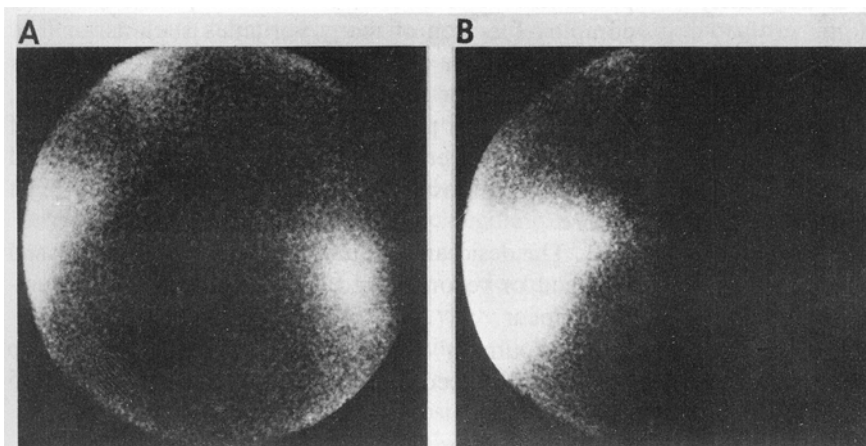


FIG. 1. (A) Transmission-emission image of lung and splenic area shows radioactivity simulating spleen; (B) emission image of same area showing no radioactivity simulating spleen.