
^{99m}Tc -Depreotide Chest SPECT Demonstrates Pulmonary Metastases from Renal Cell Carcinoma

Wei-Jen Shih, MD^{1,2}; Ramon A.L. Romero, MD^{3,4}; Mullet Timothy, MD^{3,4}; and Primo P. Milan, MD⁵

¹Nuclear Medicine Service, VA Medical Center, Lexington, Kentucky; ²Department of Diagnostic Radiology, College of Medicine, University of Kentucky, Lexington, Kentucky; ³Surgical Service, VA Medical Center, Lexington, Kentucky; ⁴Department of Surgery, College of Medicine, University of Kentucky, Lexington, Kentucky; and ⁵Radiology Service, VA Medical Center, Lexington, Kentucky

^{99m}Tc -Depreotide has been used on single pulmonary nodules to identify somatostatin receptor-positive lung cancer. We report that pulmonary metastases of a 78-y-old man with postradical nephrectomy for renal cell carcinoma were detected by ^{99m}Tc -depreotide chest SPECT. Thus, ^{99m}Tc -depreotide chest SPECT can be used to diagnose secondary lung cancer, such as pulmonary metastases from renal cell carcinoma with somatostatin receptor-positive tumor, other than primary lung cancer. Depending on whether the ^{99m}Tc -depreotide was positive for pulmonary metastases, the patient underwent an appropriate therapy without further invasive procedures.

Key Words: oncology; SPECT; renal; ^{99m}Tc ; somatostatin receptor

J Nucl Med Technol 2004; 32:19–21

Somatostatin receptor-binding peptide (^{99m}Tc -depreotide) has been used in the imaging of suspected malignant tumors in the lung for the evaluation of solitary pulmonary nodules (1,2) and secondary lung cancer (3). This peptide agent has been used to detect breast cancer (4,5). We report that ^{99m}Tc -depreotide SPECT demonstrated pulmonary metastases in the case of a patient with renal cell carcinoma to guide the subsequent course of treatment.

CASE REPORT

Seven months after a left radical nephrectomy for renal cell carcinoma, a 78-y-old man was referred for ^{99m}Tc -depreotide chest SPECT because a follow-up surveillance chest CT scan showed bilateral upper lobe lesions (Fig. 1).

He was incidentally found to have a left renal mass lesion on ultrasonography of the abdomen for gastrointestinal symptoms, most likely a result of gallstones, 9 mo previously, and subsequent CT of the abdomen showed a 6-cm cystic mass in the left kidney. Three weeks later the patient underwent a radical left nephrectomy. The renal tumor was found to be extensive, invading the renal capsule and colonic mesentery. The removed kidney confirmed sarcomatoid renal cell carcinoma. ^{99m}Tc -Depreotide lung images (Fig. 2) showed 2 lung lesions in the lungs, one in the right upper lung and another in the left upper lung corresponding to the CT scan of the chest (Fig. 1). Because of the positive findings for lung lesions on SPECT as well as CT, the patient was being worked up for surgical lung resections. Four and one-half weeks later, this patient underwent a wedge lung resection of the right upper lobe; the removed 3.0 × 2.0 × 0.6 cm lesion confirmed metastatic sarcomatoid renal cell carcinoma. Two weeks later, the patient underwent a right upper lobe lobectomy; the results of the pathologic examination also confirmed metastatic renal cell carcinoma, and surgical parenchymal margins were free from tumor cells.

DISCUSSION

One third of patients with a renal cell carcinoma have pulmonary metastases at the time of diagnosis, and one half of those who had a radical nephrectomy for renal cell carcinoma develop pulmonary metastases later (2). Our patient developed pulmonary metastases 9 mo later and fit this category.

^{99m}Tc -Depreotide, a relatively new somatostatin analog tumor imaging agent, targets somatostatin receptor-positive tumors. Overexpression of somatostatin receptors has been shown in a multitude of tumors, including breast carcinoma, carcinoid, and renal cell carcinoma (2). Primary breast carcinoma has been detected by this agent (4,5); this agent has also been used to detect non-Hodgkin's lymphoma (6)

For correspondence or reprints contact: Wei-Jen Shih, MD, Nuclear Medicine Service, College of Medicine, University of Kentucky, 1101 Veterans Dr., Lexington, KY 40502.
E-mail: wshih0@uky.edu

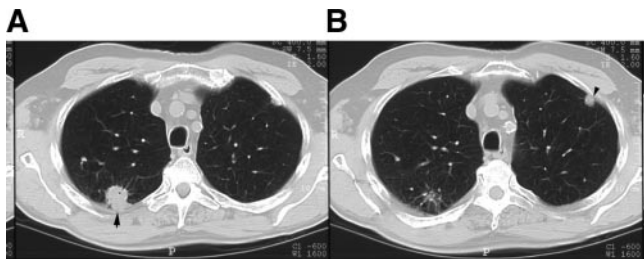


FIGURE 1. CT scans of the chest show a 2.3-cm pleural-based speculated mass in the right lobe posterior segment (A, arrow) and a 0.6-cm pleural-based mass in the left upper lobe anterior segment (B, arrow).

and low-grade lymphoma (7). Although ^{99m}Tc -depreotide had not been used in a primary renal cell carcinoma, we described a renal cell carcinoma patient's pulmonary metastases detected by ^{99m}Tc -depreotide chest SPECT.

^{99m}Tc -Depreotide has been shown to have almost no gastrointestinal activity because of its predominantly renal excretion (8). Thus, renal activity has been graded as the highest uptake, even higher than the uptake in the liver and spleen on ^{99m}Tc -depreotide normal biodistribution (9). Be-

cause ^{99m}Tc -depreotide is normally localized in the normal renal tissue, both kidneys are normally visualized. Absent visualization of one kidney might indicate renal disease or absence due to surgery, as was the case with our patient whose left kidney is not visualized (Fig. 2A). In addition, overexpression of renal cell carcinoma of ^{99m}Tc -depreotide cannot be differentiated from the normal renal tissue; thus, primary renal cell carcinoma is practically undetectable. On the other hand, renal cell carcinoma metastasized to the lung would easily be identified on ^{99m}Tc -depreotide chest SPECT from the normal lung tissue such as shown in Figure 2.

Because pulmonary metastases from renal cell carcinoma are resistant to chemotherapy and radiotherapy—and immunotherapy at present does not considerably improve long-term survival—surgical resection currently is the only effective therapeutic option in renal cell cancer metastatic to the lung (10). Thus, this patient underwent surgical resection.

REFERENCES

1. Morehead RS, Shih WJ. Tc-99m labeled somatostatin receptor-binding peptide imaging for a pulmonary nodule. *Clin Nucl Med.* 2001;26:910–912.

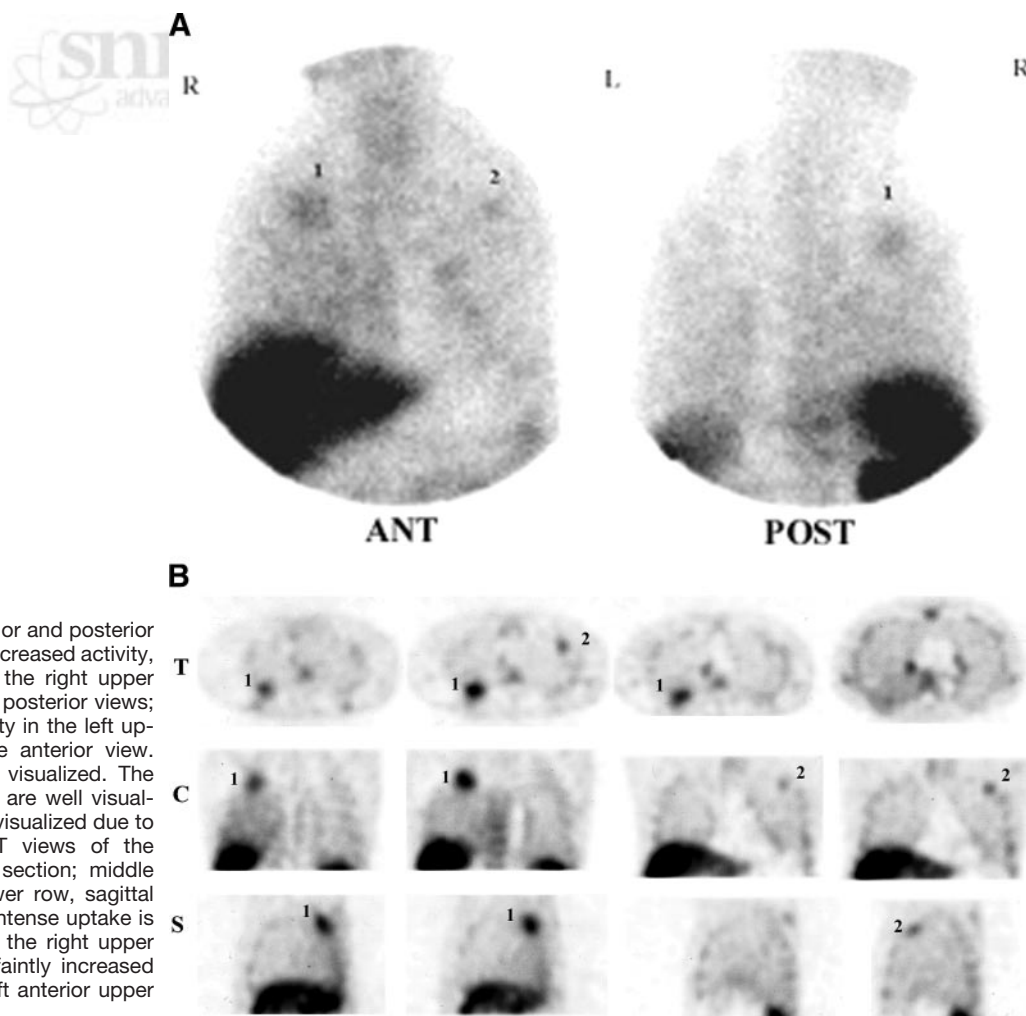


FIGURE 2. (A) Planar anterior and posterior images show a larger area of increased activity, as indicated by the arrow in the right upper lung, seen on the anterior and posterior views; a small faintly increased activity in the left upper lung is seen only on the anterior view. Spine, sternum, and ribs are visualized. The liver, spleen, and right kidney are well visualized, but the left kidney is not visualized due to the nephrectomy. (B) SPECT views of the chest: upper row, transaxial section; middle row, coronal section; and lower row, sagittal section. 1 = A larger area of intense uptake is seen in the posterior edge of the right upper lung; 2 = a smaller area of faintly increased radioactivity is noted in the left anterior upper lung.

2. Dekernion JB, Ramming KP, Smith RB. The natural history of metastatic renal cell carcinoma: a computer analysis. *J Urol*. 1978;120:148–152.
3. Miliziano JS, Bradley YC. Soft tissue metastases and lung cancer recurrence detected by Tc-99m depreotide scintigraphy. *Clin Nucl Med*. 2002;27:410–412.
4. Montilla-Soler JL, Bridwell RS. Tc-99m depreotide scintigraphy of breast carcinoma. *Clin Nucl Med*. 2002;27:202–204.
5. Vikić-Topic S, Raisch KP, Kvols LK, et al. Expression of somatostatin receptor subtypes in breast carcinoma, carcinoid, and renal cell carcinoma. *J Clin Endocrinol Metab*. 1995;80:2974–2979.
6. Bushnell D, Menda Y, Madsen M, et al. Tc-99m depreotide tumor uptake in patients with non-Hodgkin's lymphoma [abstract]. *J Nucl Med*. 2003;44(suppl):420P.
7. Waxman AD, Williams CM, Lyass O, et al. Tc-99m depreotide (DEP) in the evaluation of patients with low grade lymphoma (LGL) [abstract]. *J Nucl Med*. 2003;44(suppl):420P.
8. Vallabhajosula S, Moyer BR, Lister-James J, et al. Preclinical evaluation of Tc-99m labeled-somatostatin receptor-binding peptides. *J Nucl Med*. 1996;37:1016–1022.
9. Shih WJ, Hirschowitz E, Bensadoun E, Woodring J, Ryo UY, Kraman S. Biodistribution on Tc-99m labeled somatostatin receptor-binding peptide (depreotide, NeoTec) planar and SPECT studies. *Ann Nucl Med*. 2002;16:213–219.
10. Friedel G, Hurtgen M, Penzenstadler, Kyriss T, Toomes H. Resection of pulmonary metastases from renal cell carcinoma. *Anticancer Res*. 1999;19:1593–1596.

