

---

# Enterogastric Reflux Mimicking Gallbladder Disease: Detection, Quantitation and Potential Significance

Alberto J. Arroyo, J. Bradley Burns, Wayne A. Huyghe, Ann E. Dollman and Yogesh P. Patel

Department of Nuclear Medicine, Division of Radiology, St. Vincent Mercy Medical Center, Toledo; and Department of Radiology, Medical College of Ohio, Toledo, Ohio

---

**Objective:** Visualization of enterogastric reflux (EGR) may be present during hepatobiliary imaging. Reflux of bile may damage the gastric mucosa, altering its function, and cause such symptoms as epigastric pain, heartburn, nausea, intermittent vomiting and abdominal fullness. These symptoms also are associated with gallbladder disease. The aim of this study was to quantitate the EGR index (EGRI) and to determine if a difference exists in normal and abnormal responses using standard cholecystokinin (CCK)-augmented hepatobiliary imaging.

**Methods:** This study used 129 patients. LAO dynamic data on a  $128 \times 128$  matrix at a rate of 1 frame/min were obtained. After the gallbladder ejection fraction (GBEF) was determined, the EGRI (%) was calculated by relating the counts in the gastric ROI to the counts in the hepatobiliary ROI at a specified time. The results were compared with the patient's final clinical diagnosis.

**Results:** Normal responders (GBEF  $\geq 35\%$ ) had a higher EGRI than abnormal responders with a  $P = 0.001$  EGR observed in 75 patients (58.1%). Significant reflux (EGRI  $\geq 14.2\%$  at 15 min) was observed in 29 additional patients (22.5%). Patients with EGRI  $\geq 24.5\%$  showed a strong association with the pathophysiologic syndrome of gastritis, alkaline reflux, gastric ulcer and gastro esophageal reflux disease. There was no EGR observed in the remaining 25 patients (19.4%).

**Conclusion:** This simple addition to the CCK-augmented hepatobiliary imaging may both detect and quantitate abnormal EGR as the cause of the patient's symptoms in the presence of a normal GBEF result, and/or those patients with risk factors for gastritis.

**Key Words:** hepatobiliary imaging; cholecystokinin; enterogastric reflux; gastritis; esophagitis

*J Nucl Med Technol* 1999; 27:207–214

---

The value of hepatobiliary imaging in diagnosing biliary disease is well established (1). It is not uncommon to visualize

enterogastric reflux during such studies performed to evaluate gallbladder (GB) disease (2). Gastric reflux may damage the gastric mucosa, alter its function and cause such symptoms as epigastric and postprandial pain, intermittent vomiting of bilious contents, heartburn, nausea and abdominal fullness (3). These symptoms are associated also with GB disease.

The role of bile and pancreatic enzymes in the pathogenesis of dyspeptic symptoms and mucosal lesions of the stomach and esophagus has been extensively investigated (4). Questions persist including whether the presence of bile in the stomach is a physiologic phenomenon, and what amount of bile the stomach can tolerate without pathologic or clinical manifestations (5).

The aim of this study was to assess the incidence of enterogastric reflux (EGR) and to quantitate the enterogastric reflux index (EGRI) (6) to determine if the EGRI is different in normal individuals compared with abnormal responders during standard CCK-augmented hepatobiliary imaging.

## MATERIALS AND METHODS

Data from 129 studies were collected. There were 83 female patients and 46 male patients, with an age range of 12–82 y and an average age of 47 y. The patients were in a minimum fasting state of 3 h (range = 4–6 h) when they were injected intravenously with 1 mCi  $^{99m}\text{Tc}$ -mebrofenin, (Choletec; E.R. Squibb and Sons Inc., New Brunswick, NJ). Oral lipids were withheld from inpatients for 5 h. Those patients who were fasting for > 18 h were pretreated with CCK. Imaging was performed using a large field-of-view (LFOV) gamma camera with a low-energy, medium sensitivity/medium resolution, parallel-hole collimator.

All patients were studied in the supine LAO position. Continuous computer data acquisition was performed at a rate of 1 frame/min for 120 min (minimum 90 min) in a  $128 \times 128$  matrix. The importance of remaining as still as possible was emphasized to all patients. At 60 min postradiotracer injection, 0.02  $\mu\text{g}/\text{Kg}$  OP-CCK (Kinevac, the active octapeptide of cholecystokinin (OP-CCK); E.R. Squibb and Sons Inc. New Brunswick, NJ) was infused over 30 min to stimulate GB

---

For correspondence or reprints contact: Alberto J. Arroyo BA, CNMT, ARRT(N), FSNM(TS), Dept. of Nuclear Medicine, Div. of Radiology, St. Vincent Mercy Medical Center, 2213 Cherry St., Toledo, OH 43608.

**TABLE 1**  
Percent Gallbladder Ejection Fraction (GBEF) and Statistical Analysis

	N	Minimum %GBEF	25th percentile	Median	75th percentile	Maximum %GBEF	Mean ± SD
Abnormal responders	45	3%	15%	20%	26%	33%	20.4% ± 7.7
Normal responders	84	35%	55%	73%	84%	95%	68.5% ± 17.7

**TABLE 2**  
Percent Enterogastric Reflux Index (EGRI) and Statistical Analysis

	N	Minimum EGRI	25th percentile	Median	75th percentile	Maximum EGRI	Mean ± SD
Abnormal responders	45	0	0	0	5.6%	51%	6.4 ± 12.8
Normal responders	84	0	0	1.95%	25.5%	97%	16.2 ± 26.8

Normal responders have a higher EGRI than abnormals (median 1.95% versus 0, respectively), with a *P* value = 0.001.

emptying. A GB ROI was used to evaluate the dynamics of the contraction after OP-CCK administration.

According to the following formula (7):

$$GBEF (\%) = \frac{GB \text{ max} - GB \text{ min}}{GB \text{ max}} \times 100, \quad \text{Eq. 1}$$

where:

GB max = GB maximum counts (before OP-CCK); and  
GB min = GB minimum counts at 30 min (post OP-CCK).

Thirty-five percent or greater ejection fraction (GBEF) was considered a normal response.

Each study was analyzed for the occurrence of enterogastric reflux by drawing a gastric ROI and an ROI encompassing the entire hepatobiliary system, and then generating the corresponding time-activity curves. Evaluation for overlap of the left lobe of the liver or proximal small bowel with the gastric ROI was performed.

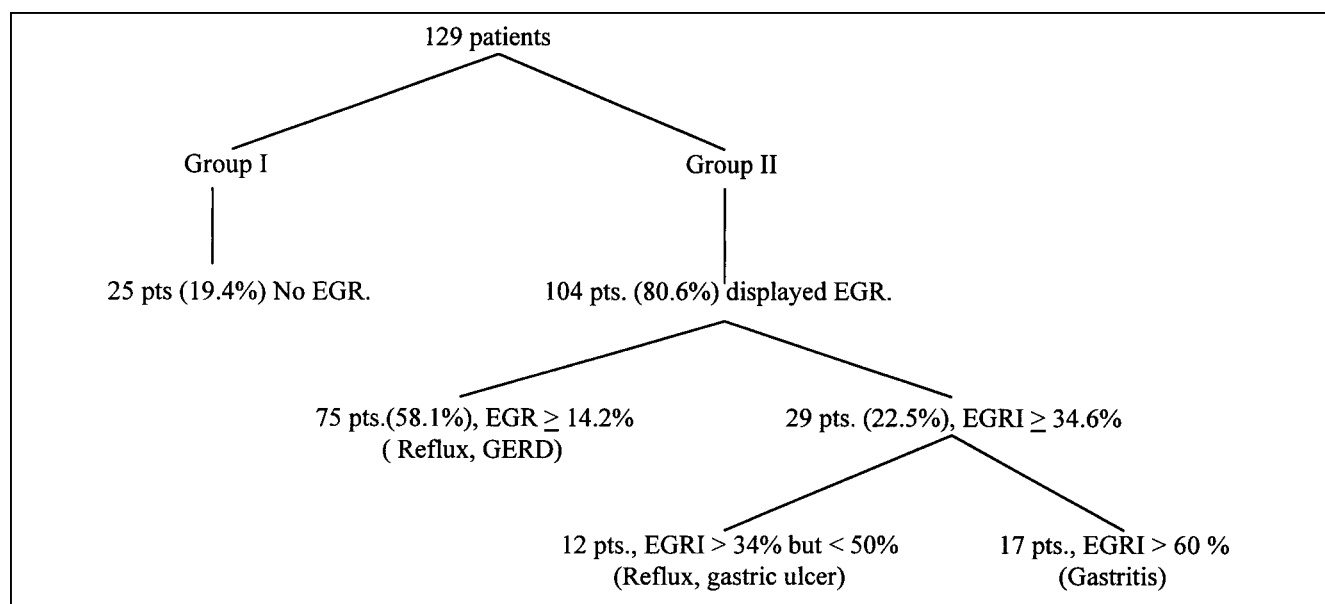
Patient motion also was evaluated. The EGRI (6) over a specified time period (from time = 0 to time = t) is defined as the increase in <sup>99m</sup>Tc activity in the gastric ROI (the numerator of the formula), divided by the decrease in <sup>99m</sup>Tc activity in the hepatobiliary system. This is expressed as:

$$EGRI (\%) = \frac{St - So}{Hbo - Hbt} \times 100, \quad \text{Eq. 2}$$

where:

So = stomach activity at time of GB stimulation (CCK);  
St = stomach activity at time t;  
Hbo = hepatobiliary activity a time of GB stimulation (CCK); and  
Hbt = hepatobiliary activity at time t.

The denominator in Equation 2 represents the amount of activity which has left the hepatobiliary system and, therefore,



**FIGURE 1.** Flow diagram of study results.

is available for reflux into the stomach. A minor modification of the technique by Tolin et al. (6) was used. The modification consisted of continuous data acquisition, which resulted in a continuous time-activity curve of gastric activity. Second, OP-CCK infusion over 30 min was used and, finally, an LAO projection was used for data acquisition.

The final clinical diagnosis was determined by upper gastrointestinal endoscopy, review of the patient's medical record and/or from the patient's primary physician.

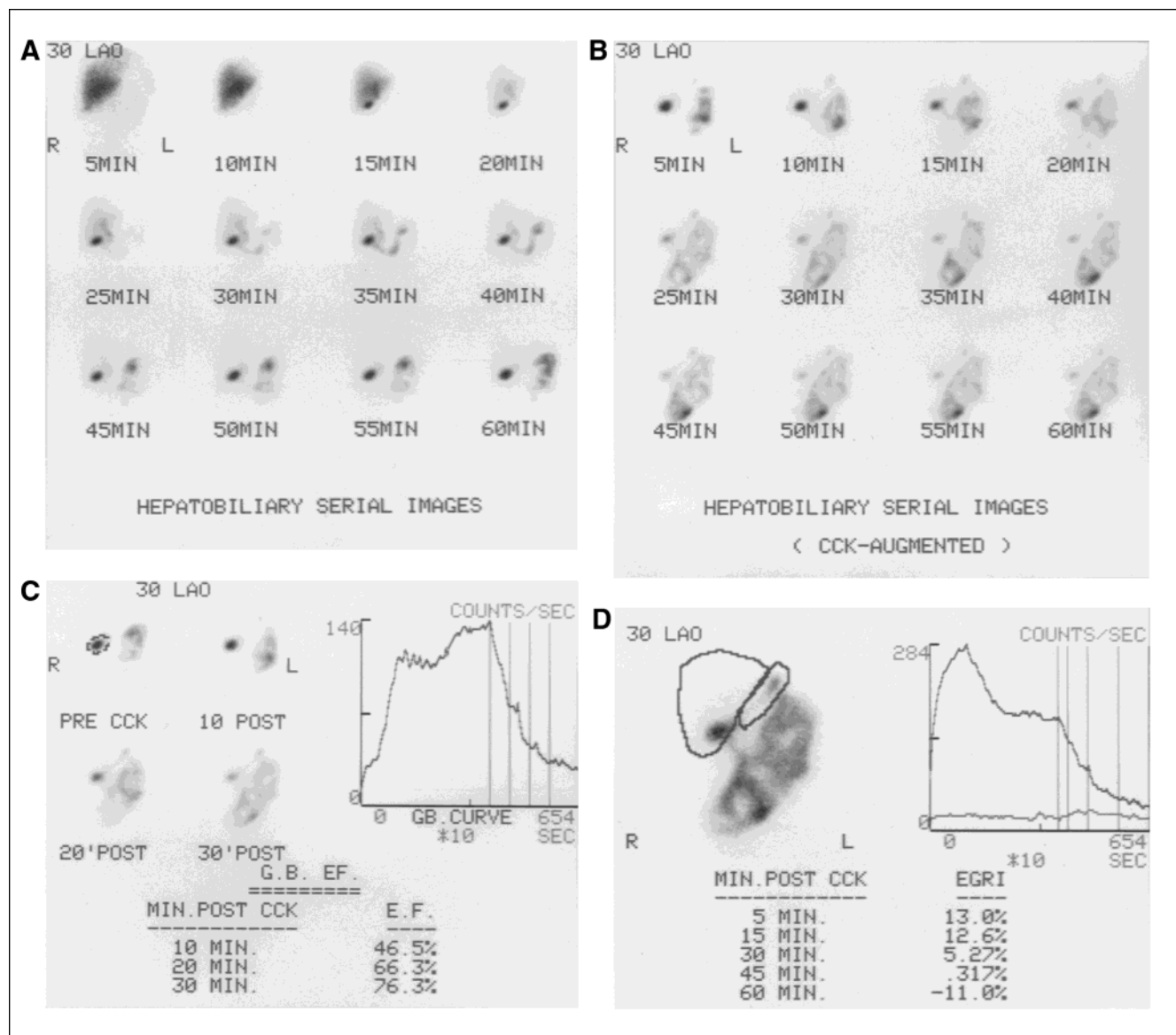
The normal distribution cannot be assumed because many subjects had an EGRI of 0. Data are presented as minimum, 25th percentile, median (or 50th percentile), 75th percentile, maximum and the mean  $\pm$  SD. The interquartile range contains 50% of the data and is defined from the 25th to 75th percentile. A nonparametric Mann-Whitney-Wilcoxon 2-tailed

test is used for the statistical comparison. A  $P$  of  $< 0.05$  indicates a statistically significant difference between normal and abnormal responders to OP-CCK.

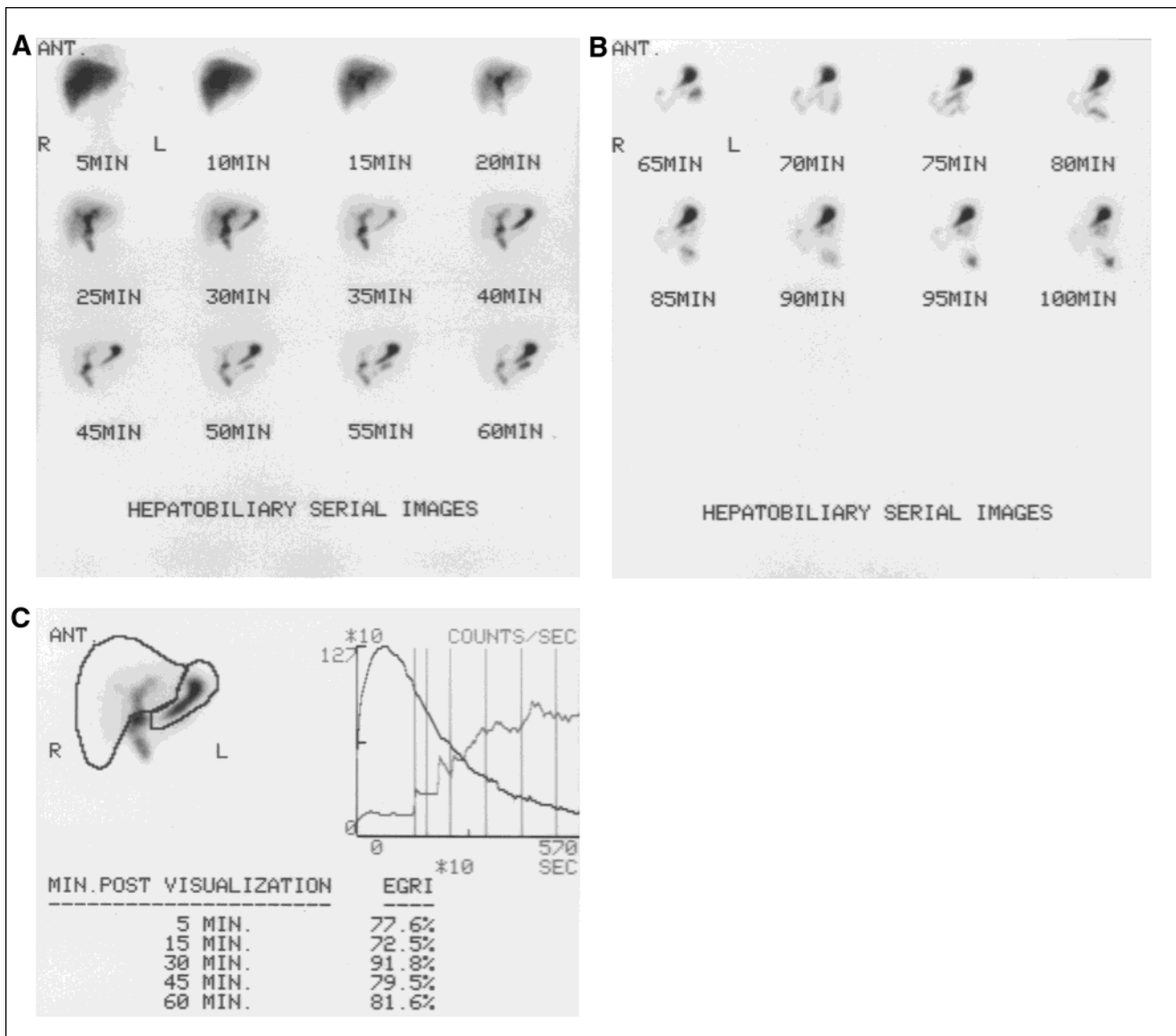
## RESULTS

The results of this study are summarized in Tables 1 and 2 and in Figure 1. There were 84 normal individuals. The mean GBEF was  $69\% \pm 18$  (range = 35–95%) and the mean EGRI was  $16\% \pm 27$  (range = 0–97%). There were 45 patients with pathology. The mean GBEF was  $20\% \pm 8\%$  (range 3–33%) and the mean EGRI was  $6\% \pm 13$  (range = 0–51%).

Eight patients with gastritis showed normal or no detection of entero-gastric reflux. Four of these patients were responding to appropriate therapy. Two had gastrointestinal endoscopy showing gastritis. No reflux was detected in the OP-CCK study



**FIGURE 2.** Normal subject: (A) pre-OP-CCK images showing normal hepatobiliary imaging pattern; (B) post-OP-CCK images showing gallbladder emptying; (C) normal ( $> 35\%$ ) GBEF quantitation; and (D) EGRI quantitation within normal limits.



**FIGURE 3.** Postcholecystectomy patient: (A) and (B) show hepatobiliary imaging performed for 100 min and (C) EGRI quantitation showing an abnormally high degree of reflux.

presumably due to the intermittent or transient nature of reflux (8). The reasons still remain unexplained as to why the last 2 patients also failed to demonstrate reflux.

#### DISCUSSION

The reflux of duodenal contents (bile and digestive enzymes) into the stomach and, perhaps, eventually into the esophagus occurs either in patients with intact gastrointestinal tracts (4) or in those with a variety of gastrointestinal disorders, including postsurgical (post-Bilroth II gastroenterostomy) alkaline gastritis, gastric ulcer, reflux esophagitis, gallstone dyspepsia, and functional dyspepsia (6). It also has been reported in scleroderma (9), an idiopathic, multisystem connective-tissue disorder with frequent involvement of the gastrointestinal tract, in which dilation and hypomotility of the esophagus often is

accompanied by marked gastroesophageal reflux and esophagitis.

Duodenal reflux occurs in approximately 67% of unoperated normal individuals (Fig. 2). Reflux may be an important cause of gastritis after duodenal ulcer surgery. Hepatobiliary imaging has been used to evaluate these patients and to assess subsequent antireflux surgery (2).

Pancreatitis also may cause enterogastric reflux. This may be related to decreased pancreatic secretion into the duodenum, important in maintaining an orderly outward flow of gastric contents and the patency of the gastroduodenal sphincter (10). Conceivably, duodenal inflammation caused by adjacent structures, such as in acute cholecystitis and pancreatitis, also may contribute to enterogastric reflux (11). It also is likely that the postsurgery functional loss of the GB as a bile reservoir

contributes to enterogastric reflux, since it is more common after cholecystectomy (Fig. 3), and a defective pylorus (12).

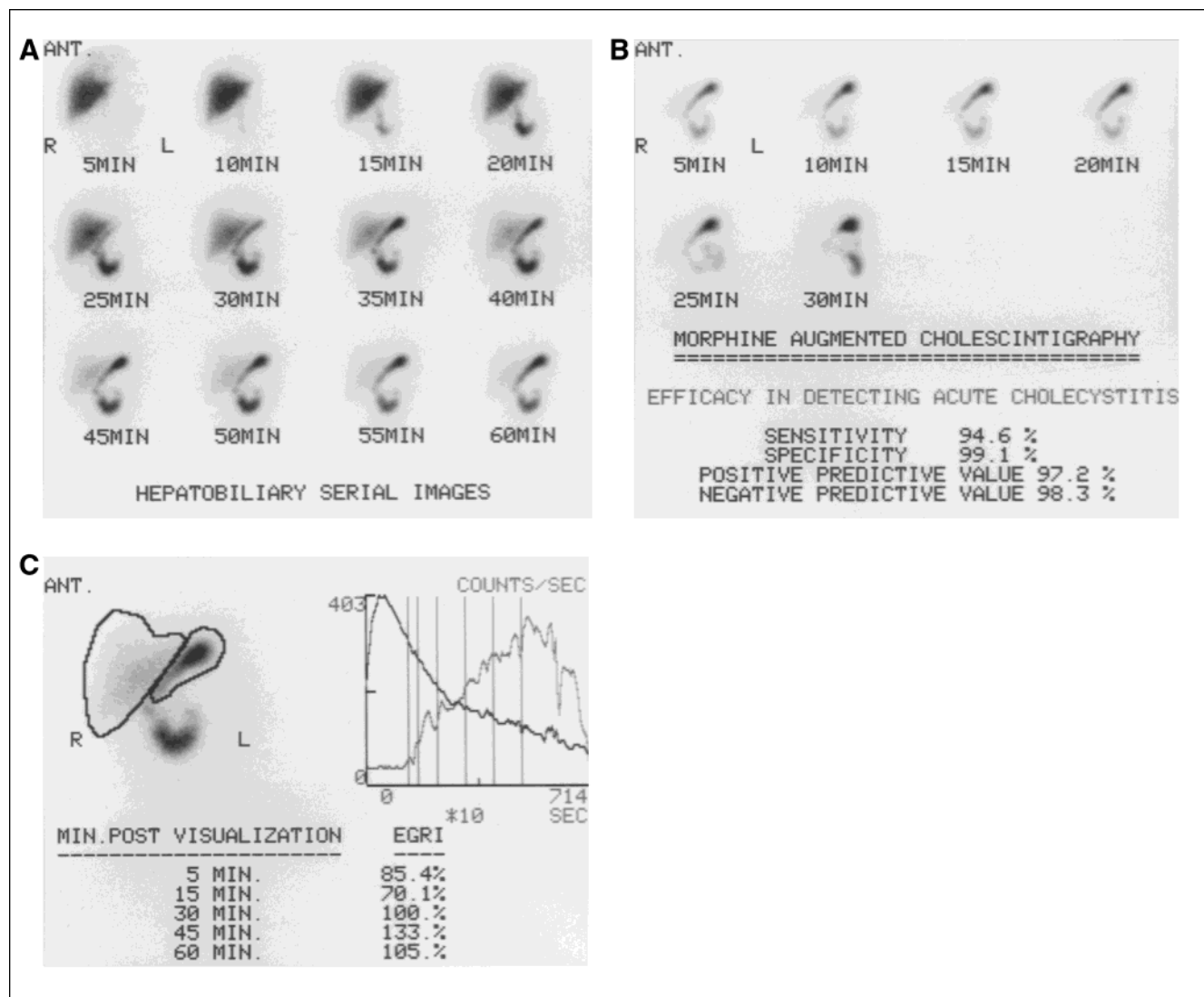
Enterogastric reflux also has been observed in up to 74% of patients receiving morphine sulfate (Fig. 4), whose GBs were not visualized by 60 min, despite the presence of small-bowel activity. Morphine sulfate may contribute to enterogastric reflux by its secondary gastrointestinal effects. Although it is a frequent finding during morphine sulfate studies, it is not a specific finding. These patients probably have underlying chronic, if not acute, biliary tract disease (1).

Considering the frequency of enterogastric reflux occurrences, as stated in the literature and as shown in this study (Fig. 5 is an example), a simple, reliable and quick technique to evaluate enterogastric reflux is desirable. We proposed a slight variation of the method by Tolin et al. (6). The rationale of the proposed technique is that we may be able to identify a

defective pylorus and the supine position was used for the examination since the pylorus is at its most efficient state in this position. It is the most comfortable position and readily accepted by most of our patients. It is the position we would normally use for all OP-CCK hepatobiliary imaging studies. For the same reason, we used OP-CCK to stimulate the GB rather than a fatty meal. This allowed us to perform the test in the fasting state when the pylorus should be more efficient.

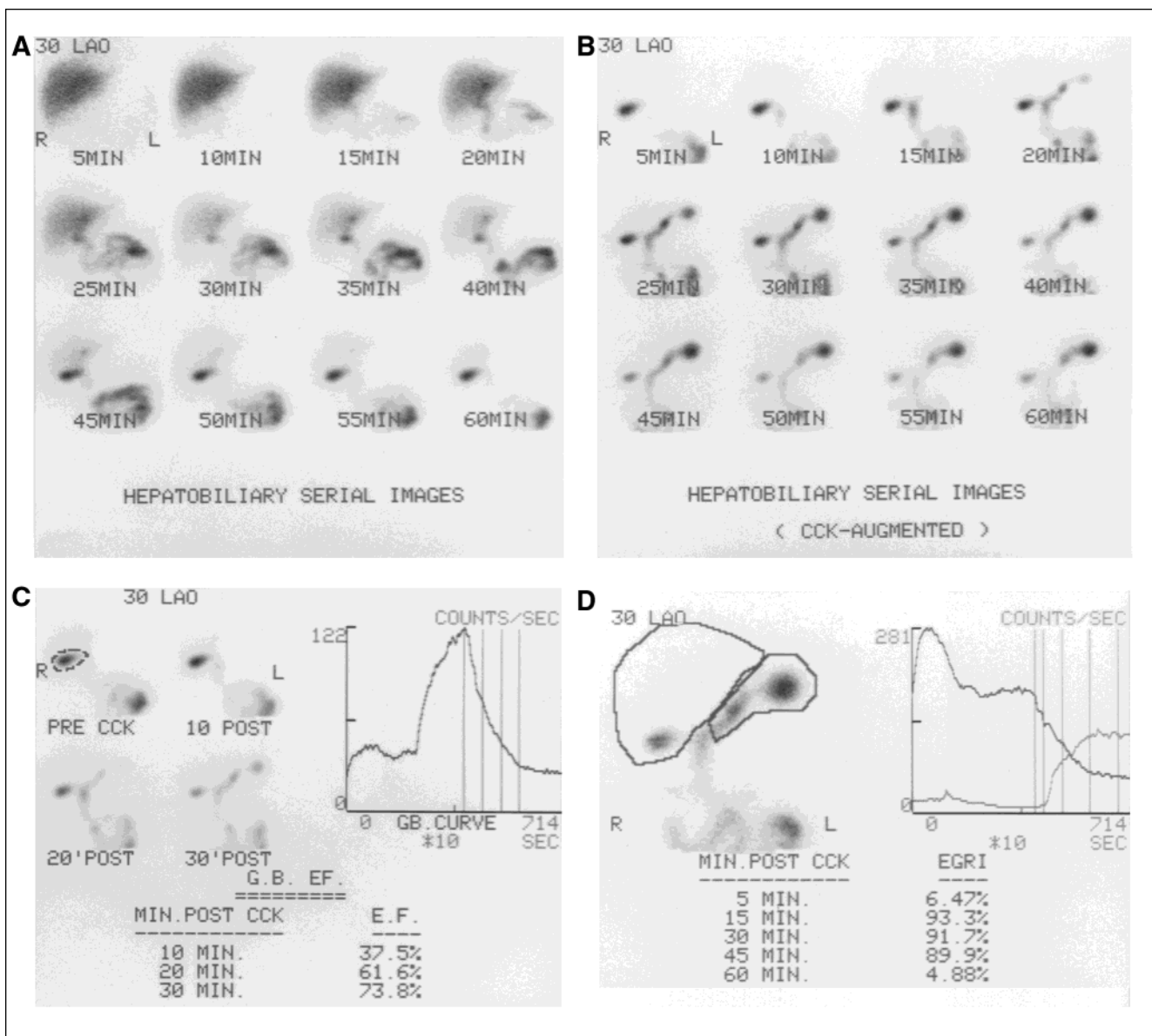
The advantage of this method is that it uses a single isotope versus previous studies using a dual-isotope technique, which is used to delineate or outline the stomach. The LAO view prevents overlap of the GB and duodenum, as well as allowing better visualization of the stomach. The additional 2 min of computer time (in-house program) needed to calculate the EGRI, on available data, was minimal and well worth the effort.

Finally, the dynamic continuous data acquisition allowed us



**FIGURE 4.** Morphine sulfate augmented study: (A) hepatobiliary images before morphine sulfate administration; (B) images obtained after morphine sulfate administration (0.04 mg/kg; efficacy in detecting acute cholecystitis is from reference 14); and (C) EGRI quantitation showing an abnormally high degree of reflux. This patient was subsequently diagnosed with gastritis.





**FIGURE 5.** Typical example of a patient with gastritis. (A) Pre-OP-CCK images; (B) post-OP-CCK images; and (C) normal GBEF quantitation indicate a normal quantitative hepatobiliary scintigraphic study. (D) EGRI quantitation, showing an abnormally high degree of gastric reflux. This patient was subsequently diagnosed with gastritis by gastrointestinal endoscopy.

to check the entire study in cine mode. This allowed us to evaluate overlap of the left lobe of the liver or proximal small bowel with the gastric ROI. The intermittent nature of reflux (Fig. 6), as well as the detection of patient motion, can be monitored with cine-mode display of continuous data.

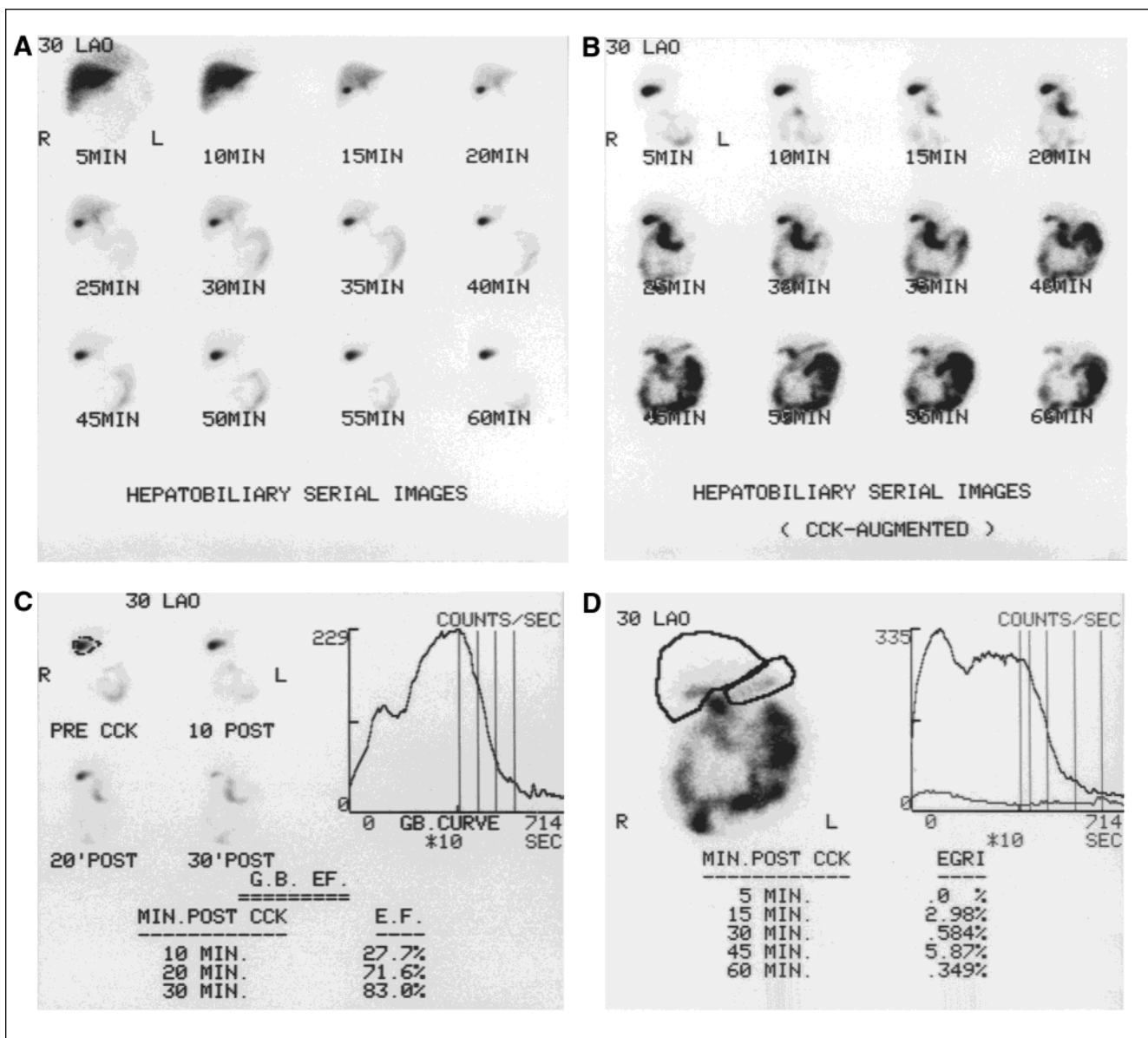
#### Study Limitations

The accuracy of the technique to quantitate EGRI has been questioned (12) because it may not only reflect reflux after GB emptying but also from the retrograde intestinal flow of activity already in the small bowel (Fig. 7). The precise origin of the reflux may not be that important for the purposes of quantitation (the origin can be determined by examining the entire database in cine mode) It is the actual contact between the duodenal

contents and the gastric and/or esophageal mucosa that it is of great importance. This is a recognized factor in determining the severity of mucosal damage (4).

Errors in defining the area of interest (gastric ROI) and its overlap with the proximal small bowel are of concern. These variables can be addressed by making the patient as comfortable as possible, reviewing the data in cine mode, and making the appropriate corrections.

Another potential shortcoming is in detecting activity from areas more distant from the detector head (i.e., posterior stomach, fundus). This variable can be addressed by using the LAO view so the stomach runs more parallel to the collimator, rather than having the fundus and antrum at different distances from the detector and, therefore, at variable attenuation settings.



**FIGURE 6.** Intermittent EGR. (A) Pre-OP-CCK images and (B) post-OP-CCK images. Notice that EGR is evident only at the 45- and 50-min images. (C) Normal GBEF quantitation following the infusion of 0.02  $\mu\text{g}/\text{kg}$  OPCCK; a GBEF >35% is normal (15). (D) EGRI within normal limits (normal =  $8.2\% \pm 6$  at 15 min; asymptomatic postsurgical =  $24.6\% \pm 4.7$  at 30 min; and postsurgical with alkaline reflux =  $86.3\% \pm 7.1$  at 30 min) (6).

The fact that the scintigraphic method does not measure the true quantity of reflux, but rather an index, should not be a concern. Although some reflux is normal, the larger the quantity of reflux and the more persistent it is, the more likely that it is related to the patient's symptoms (13). We are still able to evaluate and assess the outcome of subsequent therapy (2) using this technique.

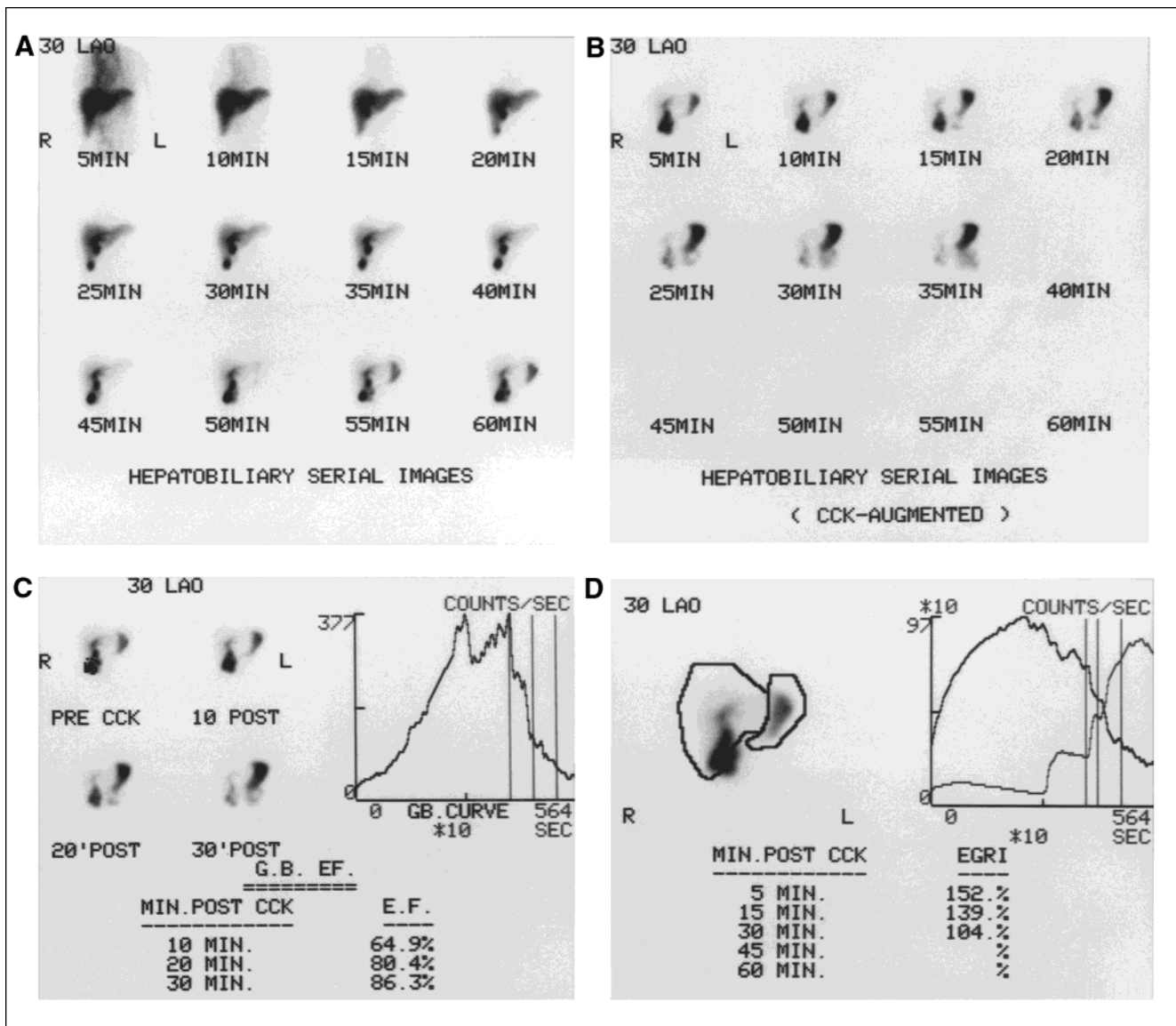
#### CONCLUSION

The purpose of this study was to investigate the incidence of and the clinical value in the quantitation of enterogastric reflux. Approximately 80% of our patients demonstrated enterogastric reflux. Those normal responders to OP-CCK had a higher EGRI than abnormal responders, with  $P = 0.001$ .

This simple addition to the standard OP-CCK hepatobiliary imaging procedure may detect abnormal percent of enterogastric reflux as the cause of a patient's symptoms in the presence of a normal GBEF result and/or other risk factors for gastritis, alkaline reflux, gastric ulcer, gastro esophageal reflux disease or underlying chronic biliary tract disease. A larger prospective study would provide a better understanding and diagnostic value of this technique.

#### ACKNOWLEDGMENTS

The authors thank Joseph T. Rakowski, MS, Nancy F. Buderer, MS, and Jeffrey M. Boorstein, MD, PhD, for their help preparing this manuscript.



**FIGURE 7.** Retrograde EGR. This study was performed only to 95 min. (A) Pre-OP-CCK images. OP-CCK was administered at 50 min. The GB begins to contract 5 min post-OP-CCK with increasing intestinal activity. Stomach activity also begins to appear as a high degree of gastric reflux. A decrease in bowel activity also is noticed (clearly evident in cine mode), indicating the origin of the additional reflux. (B) Post-OP-CCK images. (C) Normal GBEF quantitation. (D) EGRI quantitation showing a > 100% reflux.

## REFERENCES

- Oates E, Achong DM. Incidence and significance of enterogastric reflux during morphine-augmented cholescintigraphy. *Clin Nucl Med.* 1992;17:926-928.
- Colletti PM, Barakos JA, Siegel ME, et al. Enterogastric reflux in suspected acute cholecystitis. *Clin Nucl Med.* 1987;12:533-535.
- Meyer JH. Reflections on reflux gastritis [Editorial]. *Gastroenterology.* 1979;77:1143-1145.
- Borsato N, Bonavina L, Zanco P, et al. Proposal of a modified scintigraphic method to evaluate duodenogastroesophageal reflux. *J Nucl Med.* 1991;32:436-440.
- Dufresne F, Carrier L, Gagnon M, et al. Scintigraphic study of duodenogastric reflux in cases of primary gastropathy, chronic ulcer of the duodenal bulb, and Moynihan's disease. *J Nucl Med.* 1988;29:17-22.
- Tolin RD, Malmud LS, Stelzer F, et al. Enterogastric reflux in normal subjects and patients with Bilroth II gastroenterostomy: measurement of enterogastric reflux. *Gastroenterology.* 1979;77:1027-1033.
- Ziessman HA, Fahey FH, Hixson DJ. Calculation of a gallbladder ejection fraction: advantage of continuous sincalide infusion over the three-minute infusion method. *J Nucl Med.* 1992;33:537-541.
- Klingsmith WC III. Hepatobiliary imaging: normal appearance and normal variations. In: Gottschalk A, Hoffer PB, Potchen EJ, eds. *Diagnostic Nuclear Medicine*, vol 2. 2nd ed. Baltimore, MD: Williams and Wilkins; 1988:580-581.
- Sawaf NW, Orzel JA, Weiland FL. Gastroesophageal reflux demonstrated by hepatobiliary imaging in scleroderma. *J Nucl Med.* 1987;28:387-389.
- Slavin JD, Skarzynski JJ, Spencer RP. High incidence of gastric reflux during hepatobiliary imaging in pancreatitis. *Clin Nucl Med.* 1985;10:5-6.
- Drane WE, Hanner JS. Complete duodenogastric reflux: a scintigraphic sign of significant duodenal pathology. *J Nucl Med.* 1989;30:1568-1570.
- Drane WE, Karvelis K, Johnson DA, Silverman ED. Scintigraphic evaluation of duodenogastric reflux. Problems, pitfalls, and technical review. *Clin Nucl Med.* 1987;12:377-384.
- Thrall JH, Ziessman HA. *Nuclear Medicine: The Requisites*. St. Louis, MO: Mosby-Year Book, Inc.; 1995:203-204.
- Fink-Bennett D, Balon H, Robbins T, Tsai D. Morphine-augmented cholescintigraphy: its efficacy in detecting acute cholecystitis. *J Nucl Med.* 1991;32:1231-1233.