

Technical Aspects of Sentinel Node Lymphoscintigraphy for Breast Cancer

Lisa K. Dunnwald, David A. Mankoff, David R. Byrd, Benjamin O. Anderson, Roger E. Moe, Raymond S. Yeung and Janet F. Eary

Division of Nuclear Medicine and Department of Surgery, University of Washington, Seattle, Washington

Objective: A significant morbidity risk is associated with axillary nodal dissections for breast cancer. Many treatment decisions are based on axillary nodal status. Lymphatic mapping and sentinel node biopsy have been investigated to determine if the histology of the sentinel node reflects the remaining lymph node basin. We describe the technical aspects of sentinel node lymphoscintigraphy for breast cancer.

Methods: Ninety-three patients had lymphoscintigraphy for breast cancer. Patients with palpable lesions had 4 concentric injections around the site and lesions requiring localization had injections made through tubing connected to the localizing wire introducer needle. Immediate static images were acquired and the sentinel node was marked for surgery. Marks were reverified using a handheld gamma probe.

Results: Lymph nodes were visualized by lymphoscintigraphy in 87% of cases. Time to visualization of lymph nodes ranged from 1–120 min with a mean of 28 min. An average of 1.5 nodes were visualized. The overall success rate for identifying the sentinel node at time of surgery was 85%.

Conclusion: We conclude that lymphoscintigraphy for breast cancer is a detailed procedure that requires coordination with radiology and surgery teams to ensure proper identification of sentinel lymph nodes.

Key Words: lymphoscintigraphy; breast cancer; sentinel lymph node

J Nucl Med Technol 1999; 27:106–111

The assessment of axillary nodes is important in staging and treating breast cancer. Complete axillary nodal dissection carries a significant morbidity risk to the patient. Lymphatic mapping has been investigated to determine if pathologic analysis of the sentinel node predicts nodal involvement in the axilla (1).

Cabanas (2) was the first to describe this technique in 1977 in patients with penile carcinoma. Morton et al. (3) applied the concept in early-stage melanoma patients and identified the sentinel node with a high degree of accuracy using the blue dye

method. Sentinel node biopsy investigations now have been extended to the breast cancer patient population to determine feasibility and accuracy. Several different approaches have been used for identifying the sentinel node in breast lymph mapping procedures. Giuliano et al. (4) performed 174 mapping procedures by injecting vital blue dye into the breast mass and surrounding breast parenchyma at the time of surgery. Sentinel lymph nodes were identified in 114 of 174 cases (65.5%) and accurately predicted axillary nodal status in 109 of 114 (95.6%) cases. Krag and colleagues (5) used a radioisotope and a gamma probe to localize the sentinel node within the axillary specimen after it had been excised. Albertini (6) used a combination of the 2 techniques with a high degree of success in 57 of 62 patients (92%). A lymph node detected by the gamma camera was marked and confirmed with a handheld gamma-detecting probe. The probe then was used during surgery to guide the isolation and removal of the sentinel lymph node followed by a complete axillary dissection. The Veronesi (7) study design varied in that lymphoscintigraphy was performed the day before surgery with subdermal injections of ^{99m}Tc -HSA close to the tumor site. The sentinel lymph node was identified in 98% (160/163) of the cases.

The methodology used at the University of Washington is similar to that described by Albertini et al. (6). Patients had preoperative and intraoperative lymphatic mapping using a combination of lymphazurin blue dye and filtered ^{99m}Tc -sulfur colloid. A handheld gamma probe was used to assist in sentinel lymph node detection during lymphoscintigraphy and surgery.

Breast lymphoscintigraphy is a technically demanding procedure requiring close coordination between technologists, nuclear medicine physicians, radiologists and surgeons. We describe the technical aspects of sentinel lymph node lymphoscintigraphy for breast cancer and provide an example of an integrated approach to sentinel lymph node mapping.

MATERIALS AND METHODS

Patients

Ninety-three patients (ages 26–88 y; mean 55.9 y) with known invasive breast carcinoma had sentinel node lymphatic mapping. Sixty-eight of these patients were studied on a University of Washington Human Subjects Committee-ap-

For correspondence or reprints contact: Lisa Dunnwald, BS, CNMT, Div. of Nuclear Medicine, University of Washington, Box 356113, 1959 NE Pacific St., Seattle, Washington 98195.

proved research protocol. After informed consent was obtained, the patients had sentinel lymph node biopsy followed by a standard axillary dissection. Of this group, 30 patients had no prior intervention and, in most, diagnosis had been made by core needle biopsy only. The primary tumor size in patients with no prior intervention was as follows: (a) 12 T1 lesions (tumor 2 cm or less in greatest dimension); (b) 17 T2 lesions (tumor greater than 2 cm but less than or equal to 5 cm); and (c) one T3 lesion (tumor greater than 5 cm). Twenty-four patients had prior surgery or excisional biopsy. Twelve patients had locally advanced breast cancer and were treated with neo-adjuvant (presurgical) chemotherapy. Two patients had both prior surgery and chemotherapy. Fifty-five lesions or biopsy cavities were palpable, 13 required localization by ultrasound (10 patients) or mammography (3 patients).

Twenty-five patients were studied clinically after an institutional decision to perform sentinel lymph node-only sampling in patients with T1 lesions and no prior interventions (1). If the sentinel lymph node removed proved to be positive for metastatic disease, the patient went on to have a complete axillary dissection. In this group of 25 patients, 8 lesions were palpable and 17 required localization (9 by ultrasound and 8 by mammography).

Nuclear Medicine Procedures

Anesthesia. All patients had a lymphoscintigram performed 1–3 h before surgery. Before tracer injection for palpable lesions, a local anesthesia was given to anesthetize the skin first, followed by the deeper tissue. Four injections were made concentrically around the lesion site using a combination of 4 mL 1% lidocaine with 2 mL 8.4% sodium bicarbonate.

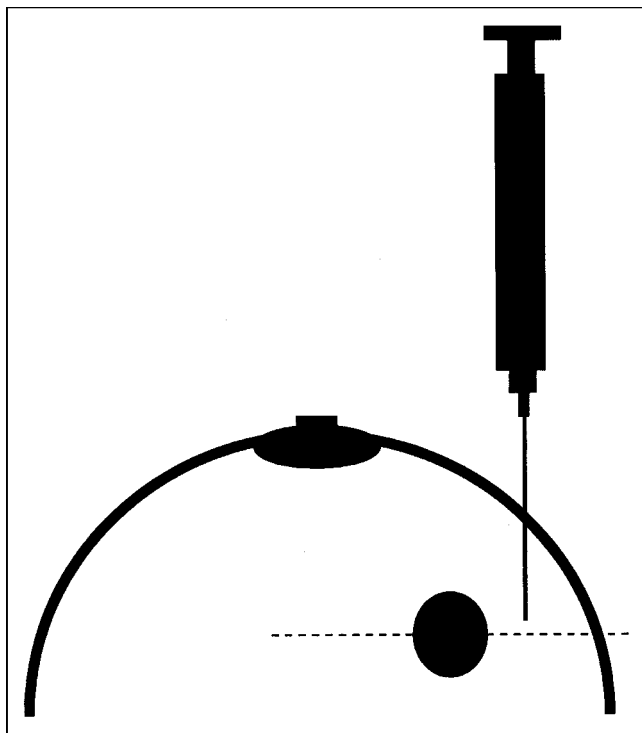


FIGURE 1. Diagram illustrating injection technique in breast cancer patients with palpable tumor masses or palpable previous biopsy cavities.

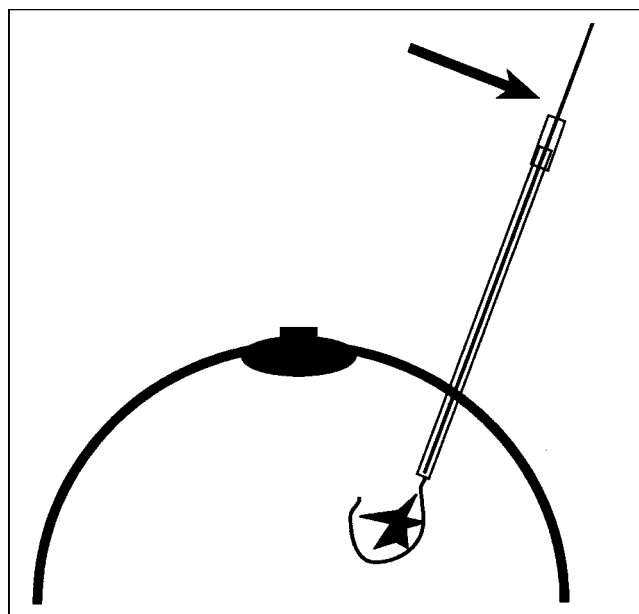


FIGURE 2. Illustration of localization wire placement in breast tumors that are not palpable. Sterile tubing is attached directly to the localizing wire introducer needle hub, as indicated by the arrow, and radioactive tracer and blue dye injections are made through the tubing.

Patients whose primary tumors were not palpable had wire localization by mammography or ultrasound. All patients requiring primary tumor localization received local anesthesia before localization by the radiologist performing the procedure.

Tracer Preparation and Injection. Filtered ^{99m}Tc -sulfur colloid was used for the procedure. The sulfur colloid kit was prepared by the local radiopharmacy according to the manufacturer's specifications (AN-Sulfur Colloid, CIS-US, Inc., Bedford, MA). A dose of 25 mCi (925 MBq) ^{99m}Tc -sulfur colloid in 2 mL was placed in a vial for delivery to our laboratory. The tracer was filtered in our laboratory by venting the vial with a needle and drawing the dose through a 0.2- μm filter, yielding approximately 4–10 mCi (148–370 MBq) filtered ^{99m}Tc -sulfur colloid. The administered dose was 1.0 mCi (37 MBq) filtered ^{99m}Tc -sulfur colloid combined with 2 mL sodium bicarbonate and normal saline to achieve a 6-mL total volume. In patients whose injection sites were not going to be re-excised (i.e., prior lumpectomy) the dose was reduced to 0.5 mCi (18.5 MBq). For palpable lesions, 4 injections of 1.5 mL each were made at the midplane of the lesion or biopsy cavity using a $25 \times 1.5\text{-G}$ needle (Fig. 1). For nonpalpable lesions that were localized in ultrasound or mammography, sterile tubing flushed with saline was connected directly to the localization wire introducer needle. A single 6-mL injection was made through the tubing (Figs. 2, 3) and followed with a 4- to 6-mL saline flush. The tubing and needle were left in place for surgeons to use for blue dye injection.

Image Acquisition and Lymph Node Marking. Images were acquired with a single-head GE 300 AC (General Electric, Milwaukee, WI) small field-of-view or GE XCT (General Electric, Milwaukee, WI) large field-of-view camera. Image acquisition began immediately postinjection. Static images were acquired in a 256×256 -matrix for 1–5 min. Image time

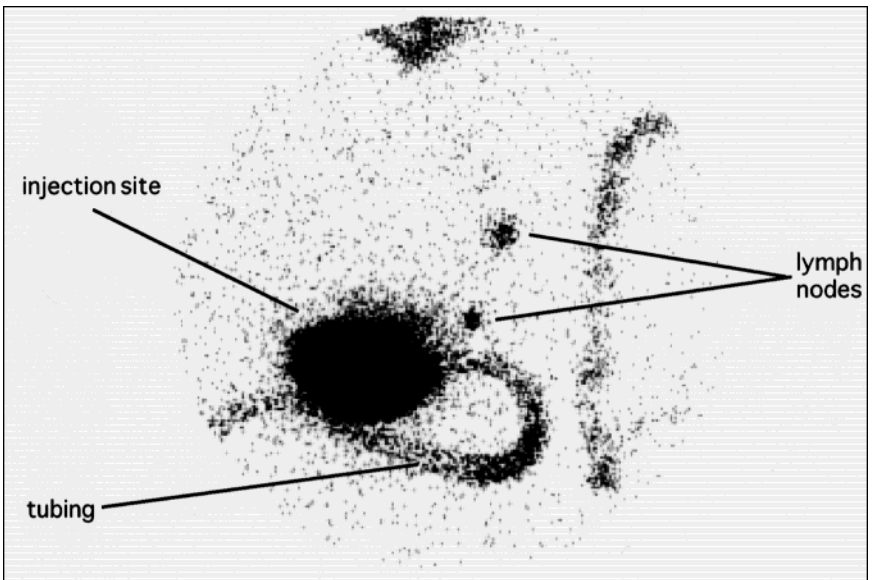


FIGURE 3. Breast lymphoscintigraphy in a patient with a nonpalpable lesion requiring ultrasound localization. Note that although a single injection site was used, there was diffuse spread of tracer over the area.

was variable, depending on how quickly the sentinel lymph node was visualized. The patient was positioned supine at a 45° tilt toward the contralateral breast to move the breast away from the axilla. The images acquired included: (a) anterior oblique axilla and/or lateral with arm above the head (both are helpful in moving the axillary lymph nodes away from the injection site) (Figs. 4, 5); and (b) anterior chest to observe any drainage to the internal mammary nodes (Fig. 6). Two sets of images were acquired, one outlining the body using a ^{99m}Tc marker and another without the body outline to ensure the nodes were not being obscured by the markings. If no lymph nodes were observed immediately, delayed images were acquired after 45 min to 1 h and repeated at 30- to 45-min intervals until a lymph node visualized. Imaging was continued up to a maximum of 2.5 h. This is a modification of the original protocol in which images were acquired in 15-min intervals. Between images, if there was not a localizing wire in place, the patient was encouraged to walk around and exercise the arm of the lesion side in an attempt to increase lymphatic flow.

Once a lymph node was detected by gamma-camera imaging, a mark was placed on the patient's skin over the visualized lymph node as a point of reference for surgical resection. The patient was placed in the proper surgical position and lymph node localization was performed in an oblique position using the gamma-camera persistence mode with a ^{99m}Tc marker. A separate image was acquired after triangulation at 45° to estimate the depth of the lymph node (Fig. 7). A handheld gamma probe was used as reverification of the skin mark identifying the sentinel lymph node location. In the event a sentinel lymph node was not visualized on lymphoscintigraphy, an attempt was still made to localize the lymph node with the handheld probe and blue dye localization at surgery. The definitive identification of a sentinel lymph node was made at the time of surgery.

Surgery

In patients with palpable lesions, a perilesional injection of 5 mL lymphazurin blue dye was made at the time of surgical incision followed by a massage of the injection site. For

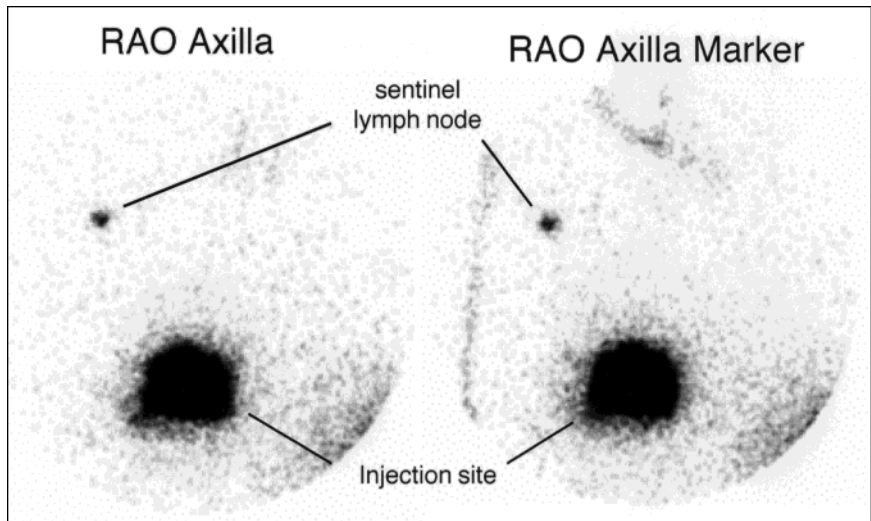


FIGURE 4. Lymphoscintigram of a patient with cancer of the right breast. On the left, immediate anterior oblique image with the arm in the swimmer's position revealed one sentinel lymph node in the axilla. On the right, reference image acquired using a ^{99m}Tc marker to outline the body.

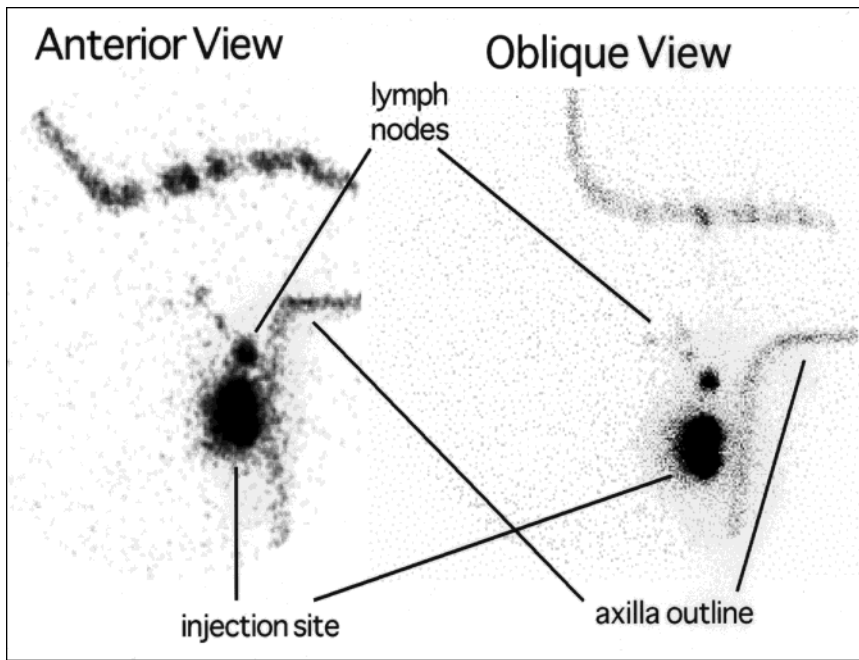


FIGURE 5. Anterior and oblique views of a breast lymphatic mapping study in a patient with lymph nodes visualized close to the injection site.

nonpalpable lesions, the blue dye was injected through the localization wire tubing placed in mammography or ultrasound, as described earlier. The standard surgical position, as suggested by Giuliano (*personal communication*, 1998), was the swimmer's position with the patient's arm across their brow. The surgeon explored the axilla, using 2 methods to identify the sentinel lymph node. Initially, the surgeon visually searched for blue lymphatic channels or vessels leading to a lymph node stained blue. In addition, the handheld gamma probe was used to detect foci of increased radioactivity counts within the axillary bed. On removal of the sentinel lymph node, ex vivo counts were recorded and the lymph bed was re-examined for residual radioactive counts. A case was considered successful when the sentinel lymph node identified was: (a) blue and/or (b) the ratio of radioactive counts in the lymph node excised versus the final surgical bed background was 3:1 or greater or the ratio of ex vivo radioactive counts in the sentinel lymph node versus

any nonsentinel lymph node removed was 10:1 or greater (6). The sentinel lymph node removed was labeled and tagged separately for detailed pathological analysis.

All patients studied on protocol had completion of axillary nodal dissection after sentinel lymph node biopsy. In the 25 patients having sentinel lymph node biopsy only (T1 lesions and no prior interventions), if the sentinel lymph node could not be properly identified, a standard axillary nodal dissection was performed. In this same group, if the sentinel lymph node was successfully identified and it was positive for metastatic disease, the patient went on to have a complete axillary dissection at a later time.

RESULTS

Sentinel lymph nodes were visualized by lymphoscintigraphy in 87% (81/93) of all cases. The mean time to lymph node

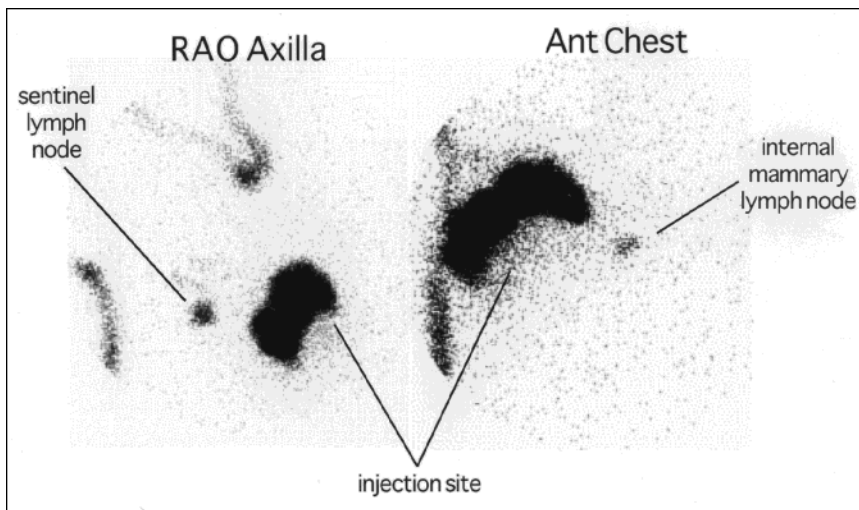


FIGURE 6. Images of a breast cancer patient with lymph node visualization in the right axilla and the internal mammary lymph node chain.

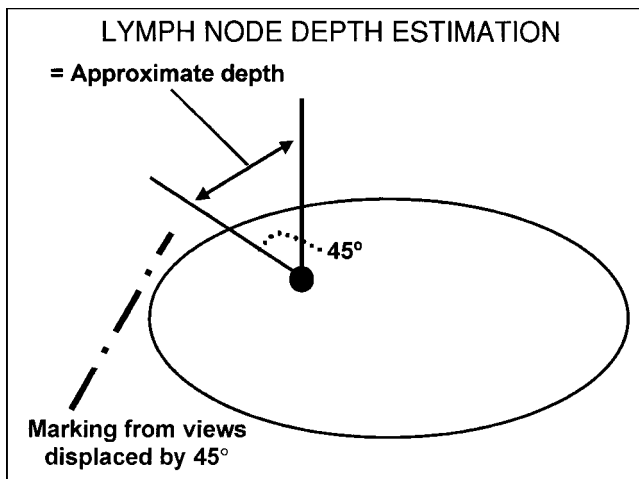


FIGURE 7. Diagram illustrating technique used in lymphoscintigraphy to estimate the depth of a lymph node. The patient is imaged and the lymph node location is marked on the patient's skin at 0° and 45°. The distance between the 2 marks is measured, approximating the depth of the lymph node.

visualization was 28 min with a range of 1–120 min; an average of 1.5 lymph nodes were visualized (range of 1–4 nodes). In the cases in which the surgeon could not identify a sentinel lymph node by the established criteria, 9 of 14 patients (64%) had a lymph node identified and marked by lymphoscintigraphy.

The overall rate for successful sentinel lymph node identification at surgery was 85% (79/93). Similar results were obtained when the data were divided into specific categories of patients: 87% (48/55) in patients with no prior intervention; 81% (20/25) in patients with prior surgery or excisional biopsy; and 86% (11/13) in patients with prior chemotherapy.

In the 68 patients studied on protocol that had a sentinel lymph node successfully identified, 24 patients (44%) had lymph nodes histologically positive for the presence of metastatic breast cancer. The sentinel lymph node was the only positive lymph node in 7 patients. Four of 24 patients had a negative sentinel lymph node and 1 or more positive nonsentinel lymph nodes in the axillary dissection specimen (false-negative). These false-negatives occurred in patients with prior chemotherapy (3 patients) and prior surgery (1 patient). There were no false-negatives in patients with no prior interventions regardless of primary tumor size (1).

In the 25 patients with sentinel node biopsy only, the success rate for identifying the sentinel lymph node at surgery was 96% (24/25). Five patients had lymph nodes that failed to visualize on lymphoscintigraphy but the surgeon was able to localize a sentinel lymph node in surgery. Of the successful cases, 6 patients (25%) had a positive sentinel lymph node(s). Five of these 6 patients went on to have a standard axillary dissection, with 4 patients having the sentinel lymph node as the only lymph node containing metastatic disease. The 1 patient who did not have a standard dissection had a total of 8 lymph nodes removed during the first surgery. Five of these lymph nodes were sentinel lymph nodes, all of which were positive for metastatic breast cancer and 3 were nonsentinel lymph nodes with no evidence of malignancy.

Lymphoscintigraphy has been a diagnostic tool offered by nuclear medicine departments for many years. It has been used to define lymphatic drainage patterns to regional lymph node basins. With the introduction of sentinel lymph node intraoperative lymphatic mapping for melanoma, the role of lymphoscintigraphy has expanded. In patients with melanoma, the procedure has identified unexpected drainage sites that surgeons would not have otherwise included in their dissection (8–11). It also has helped the surgeon perform a minimally invasive procedure, reducing the morbidity risk involved with a complete axillary dissection (12). Several studies have documented lymphoscintigraphy as one of the key components to a successful sentinel node lymphatic mapping procedure for breast cancer (13–17).

There are several aspects to consider before performing this procedure. Tracer particle size is important. An ideal tracer is one that will flow quickly through the lymph channels and into a sentinel lymph node, but also will have a long residence time within the lymph node and not migrate out afferent vessels and on to second- or third-tiered nodes. Filtered ^{99m}Tc -sulfur colloid fits these criteria. Others have advised nonfiltered ^{99m}Tc -sulfur colloid because larger particle size will stay in the sentinel lymph node longer if the lymphoscintigram is performed the day before the surgery or if the surgery is delayed (5). The migration of tracer through the lymph channels is slower with nonfiltered ^{99m}Tc -sulfur colloid. Using filtered ^{99m}Tc -sulfur colloid, we are visualizing an average of 1.5 sentinel lymph nodes on lymphoscintigraphy (mean time visualization = 28 min) and the surgeons are sampling 1.6 sentinel lymph nodes on average.

If a primary tumor requires localization, the injection technique becomes more challenging. We initially injected the tracer through a catheter placed alongside the localizing needle. This procedure was suboptimal with pressure buildup in the catheter creating backflush of the injected tracer. Attaching tubing directly to the localizing introducer needle has solved this problem.

Imaging parameters have varied in lymphoscintigraphy with some institutions performing dynamic studies (18,19). We have not found dynamic images to be helpful. Lymph drainage in the breast generally is slower than in melanoma primary tumor sites. To address the modification of our protocol for imaging time intervals, we found that static images at 15-min intervals tended to tire the patient quickly. Adjustment to an approximate 45-min delay after the immediate image and repeat static images at 30- to 45-min time intervals has not affected our ability to visualize a sentinel lymph node.

Technical details are also critical in surgery. Surgeons at our institution report 2 key points to successfully localizing the sentinel lymph node in surgery. Initial axillary dissections were performed with the patient's arm out to the side at a 90° angle. After personal communication with Giuliano, the surgical position was changed to the swimmer's position. It has been easier to find the sentinel lymph node with the arm in this position. Massaging the injection site also has been helpful in

increasing the flow of blue dye through the lymphatic channels, allowing the surgeon to quickly localize the sentinel lymph node stained blue.

The question of reporting lymph drainage to the internal mammary nodes has not been answered clearly. Drainage to the internal mammary nodes is documented with an anterior thorax view. Our surgeons currently do not remove these lymph nodes. The additional information provided by this image may be useful to the radiation oncologist who may choose to include this area in the radiation field in postsurgical radiation therapy.

We have presented sentinel node lymphatic mapping for breast cancer in a diverse patient population (1). Our initial experience indicates that sentinel lymph node biopsy can be performed with a high degree of accuracy. However, there is a learning curve involved with this procedure and our experience in successfully identifying the sentinel lymph node reflects this. The first 25 patients studied on protocol had a success rate in sentinel lymph node localization of 80%. The most recently implemented clinical procedure for breast lymphatic mapping at our institution is sentinel lymph node biopsy without complete axillary dissection in patients with T1 lesions and no prior surgery. The success rate in identifying the sentinel lymph nodes in this group of 25 patients studied thus far has been 96% (24/25). Technical skills improve as the nuclear medicine, surgery and radiology teams gain more experience in performing this procedure. The success rate in identifying and excising the sentinel lymph node increases as well.

CONCLUSION

Lymphoscintigraphy plays an important role in sentinel lymph node lymphatic mapping for breast cancer. It is a technically detailed procedure in which nuclear medicine physicians and technologists must closely coordinate with radiology and surgery teams to ensure proper identification of sentinel lymph nodes.

ACKNOWLEDGMENTS

The authors thank the nuclear medicine staff including physicians Hubert Vesselle, Michael Graham, Joseph Rajendran and staff technologists Shelley Hartnett, Melissa Baker, Pam Pham, Manjit Basran, Betty Smoot-Duncan, Erik Miller,

Colin Alden and Ray Thomas for their technical expertise and dedication to high-quality imaging and patient care.

REFERENCES

1. Eary JF, Mankoff DA, Dunnwald LK, et al. Sentinel node mapping for breast cancer: analysis in a diverse patient group. *Radiology*. 1999;in press.
2. Cabanas RM. An approach for the treatment of penile carcinoma. *Cancer*. 1977; 39:456-466.
3. Morton DL, Wen DR, Wong JH, et al. Technical details of intraoperative lymphatic mapping for early stage melanoma. *Arch Surg*. 1992; 127:392-399.
4. Giuliano AE, Kirgan DM, Guenther JM, et al. Lymphatic mapping and sentinel lymphadenectomy for breast cancer. *Ann Surg*. 1994; 220:391-401.
5. Krag DN, Weaver DL, Alex JC, et al. Surgical resection and radiolocalization of the sentinel lymph node in breast cancer using a gamma probe. *Surg Oncol*. 1993; 2:335-340.
6. Albertini JJ, Lyman GH, Cox C, et al. Lymphatic mapping and sentinel node biopsy in the patient with breast cancer. *JAMA*. 1996; 276:1818-1822.
7. Veronesi U, Paganelli B, Galimberti V, et al. Sentinel-node biopsy to avoid axillary dissection in breast cancer with clinically negative lymph-nodes. *Lancet*. 1997; 349:1864-1867.
8. Norman J Jr, Cruse W, Ruas E, et al. The expanding role of lymphoscintigraphy in the management of cutaneous melanoma. *Am Surgeon*. 1989; 55:689-694.
9. Norman J, Cruse CW, Espinosa C, et al. Redefinition of cutaneous lymphatic drainage with the use of lymphoscintigraphy for malignant melanoma. *Am J Surg*. 1991; 162:432-437.
10. Uren RF, Howman-Giles RB, Shaw HM, et al. Lymphoscintigraphy in high-risk melanoma of the trunk: predicting draining node groups, defining lymphatic channels and locating the sentinel node. *J Nucl Med*. 1993; 34:1435-1440.
11. Norman J, Wells K, Kearney R, et al. Identification of lymphatic drainage in patients with cutaneous melanoma. *Semin Surg Oncol*. 1993; 9:224-227.
12. Godellas CV, Berman CG, Lyman G, et al. The identification and mapping of melanoma regional nodal metastases: minimally invasive surgery for the diagnosis of nodal metastases. *Am Surg*. 1995; 61:97-101.
13. Pijpers R, Meijer S, Hoekstra OS, et al. Impact of lymphoscintigraphy on sentinel node identification with technetium-99m-colloidal albumin in breast cancer. *J Nucl Med*. 1997; 38:366-368.
14. Roumen RM, Valkenburg JG, Geuskens LM. Lymphoscintigraphy and feasibility of sentinel node biopsy in 83 patients with primary breast cancer. *Eur J Surg Oncol*. 1997; 23:495-502.
15. Paganelli G. Sentinel node biopsy: role of nuclear medicine in conservative surgery of breast cancer [Editorial]. *Eur J Nucl Med*. 1998; 25:99-100.
16. Borgstein PJ, Pijpers R, Comans EF, et al. Sentinel lymph node biopsy in breast cancer: guidelines and pitfalls of lymphoscintigraphy and gamma probe detection. *J Am Coll Surg*. 1998; 186:275-283.
17. O'Hea BJ, Hill AD, El-Shirbiny AM, et al. Sentinel lymph node biopsy in breast cancer: initial experience at Memorial Sloan-Kettering Cancer Center. *J Am Coll Surg*. 1998; 186:423-427.
18. Pijpers R, Collet GJ, Meijer S, et al. The impact of dynamic lymphoscintigraphy and gamma probe guidance on sentinel node biopsy in melanoma. *Eur J Nucl Med*. 1995; 22:1238-1241.
19. Taylor A Jr, Murray D, Herda S, et al. Dynamic lymphoscintigraphy to identify the sentinel and satellite nodes. *Clin Nucl Med*. 1996; 21:755-758.