

Cancer Imaging with Radiolabeled Antibodies: New Advances with Technetium-99m-Labeled Monoclonal Antibody Fab' Fragments, Especially CEA-Scan[®] and Prospects for Therapy

David M. Goldenberg, Malik Juweid, Robert M. Dunn and Robert M. Sharkey

Garden State Cancer Center, Center for Molecular Medicine and Immunology, Belleville, New Jersey

The use of radiolabeled anticancer antibodies to detect cancer sites by external scintigraphy has had a relatively long history. With the advent of monoclonal antibodies (MAbs), which precluded the need for purifying the antibodies by laborious purification steps, there was a surge of interest and efforts to develop these reagents for both imaging and therapy applications (1). Today, many thousands of patients have received different forms and doses of MAbs for various purposes, and four MAb-based products have been licensed for manufacture and sale in the U.S. (2,3). This article describes the most recent MAb product to be approved in the U.S. for colorectal cancer imaging, including discussions of using this agent and its therapeutic counterpart in several cancer types.

Key Words: immunoscintigraphy; radioimmunodetection; cancer; lymphoma; CEA

J Nucl Med Technol 1997; 25:18-23

Why is a ^{99m}Tc-labeled Fab' fragment of an antibody a desired imaging agent? The first radiolabeled antibodies used for cancer imaging consisted of whole IgGs labeled with ¹³¹I, both with purified polyclonal antibodies and even after the introduction of MAbs (1,4). Subsequently, whole IgG antibodies were labeled with ¹²³I, ¹¹¹In and ^{99m}Tc (5). It became apparent that the short half-lives of ¹²³I (13 hr) and ^{99m}Tc (6 hr) required a faster targeting agent, such as a fragmented form of the antibody. Indium-111 had a severe disadvantage of binding to normal liver tissue and to a lesser extent to spleen and bone marrow. The monovalent Fab' fragment is devoid of the immunogenic Fc portion and is of only 50,000 molecular size (Fig. 1). This allows tumor targeting within minutes to hours and clearing from the blood pool and other tissues within 24 hr. Good tumor-to-background ratios can be achieved within 24 hr, and often within 2-5 hr. This makes tumor imaging feasible on the same day that the reagent is injected intravenously and

allows sufficient counts of ^{99m}Tc to be concentrated early so that SPECT can be used to enhance image contrast and improve lesion resolution. It was also found that a dose of 1 mg of Fab' could target tumors as well as the same dose of the bivalent F(ab)₂ form, and that the 1 mg dose of either fragment was as optimal as a dose that is 10 times higher (6). Thus, 1 mg of a specific anticarcinoembryonic antigen (CEA) MAb Fab' fragment became the antibody form of choice for radiolabeling with ^{99m}Tc.

Why use ^{99m}Tc as the radiolabel? This isotope is used in over 70% of all nuclear medicine procedures, is readily available through a generator at low cost and has an excellent photon energy for conventional gamma cameras. These features are not matched by any of the other radionuclides available commercially. However, the use of ^{99m}Tc in antibody immunoscintigraphy, or radioimmunodetection (RAID), requires simple and stable labeling methods. Additionally, there has been a long development of labeling methods, both with chelates and as direct conjugation procedures (7). The product licensed as the anti-CEA Fab' involves a one-step, direct, instant labeling method of high stability and requiring no postlabeling purification (7,8).

Finally, why use CEA as the antibody target for cancer imaging? CEA was described by Gold and Freedman (9) in 1965 as a glycoprotein antigen elaborated by colorectal cancer and has been used routinely since the mid-1970s as a serum

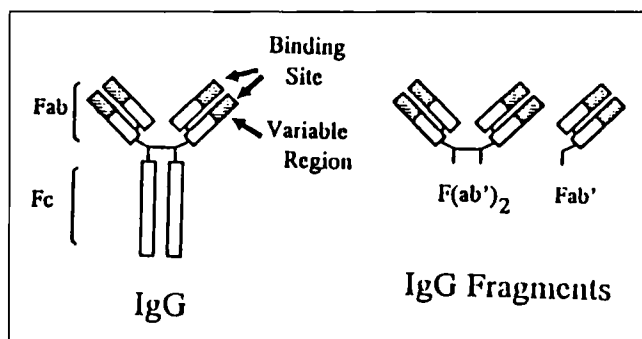


FIGURE 1. MAb IgG, F(ab)₂ and Fab' molecules.

For correspondence or reprints contact: David M. Goldenberg, ScD, MD, Garden State Cancer Center at the Center for Molecular Medicine and Immunology, 520 Belleville Ave., Belleville, NJ 07109.

marker for monitoring disease status in patients who have diverse epithelial tumors, such as gastrointestinal carcinomas (esophageal, gastric, colonic, rectal, pancreatic and biliary), mammary, lung, medullary thyroid, uterine (cervical and endometrial), ovarian and bladder carcinomas (10,11). It is not specific for these cancers, since it can be elevated in the blood of patients with some benign and inflammatory conditions of the same organs (12), but is definitely increased significantly in malignant as compared to normal or benign tissues (13,14). Anti-CEA antibodies do not have access to increased interstitial levels of CEA under normal conditions, such as when the basement membrane of the intestinal mucosa is intact. The normal mucosa does contain and shed CEA from its surface. It is only when this basement membrane is compromised by an invading carcinoma that CEA is shed into the blood and when circulating CEA antibodies can target to the neoplasm. The presence of CEA in the blood was thought originally to be a reason to preclude the binding of CEA antibodies to tumor sites, because the antigen in the blood would complex to the injected antibody and thus preclude tumor targeting (15). Our clinical studies of CEA radioimmunodetection proved this prediction to be false, and even when some complexes were formed in the blood of the patients injected with whole anti-CEA IgG antibody labeled with ^{131}I , tumor targeting and imaging was successful (4,16,17). These findings verified the usefulness of CEA antibodies for this purpose and provided direct clinical evidence for the prospects of targeting cancers with radiolabeled antibodies either for imaging or therapy.

CEA-Scan[®] (Arcitumomab) in Colorectal Cancer

CEA-Scan[®] (Immunomedics Inc., Morris Plains, NJ) is the antibody imaging agent that consists of a specific anti-CEA MAb Fab' labeled directly with $^{99\text{m}}\text{Tc}$ and was recently licensed by the FDA for detecting recurrent or metastatic colorectal carcinoma in the abdominopelvic region (8,18). Two prospective, pivotal clinical studies served as the basis for approval of this product, involving 210 presurgical patients with proven colorectal carcinoma. Although the patient population studied consisted of those with proven or suspected recurrence or spread, a small number of patients with primary colorectal cancer were also successfully imaged (3).

One milligram of CEA-Scan[®] labeled with 15–25 mCi $^{99\text{m}}\text{Tc}$ was injected intravenously; external scintigraphy was performed at 2–5 and 18–24 hr later. Imaging with standard diagnostic modalities (SDM), such as CT, roentgenograms, MRI, ultrasonography, etc., was also performed, and the findings were confirmed by surgery and histology. The sensitivity (true-positive rate) of CEA-Scan[®] was statistically superior to that of SDM (mostly CT) in the extrahepatic abdomen (55% versus 32%, $p = 0.007$) and pelvis (69% versus 48%, $p = 0.005$) and complementary to SDM in the liver (Table 1). The smallest lesion depicted by CEA-Scan[®] was in the order of 0.5 cm, but hot or rimmed lesions could be seen in the majority of tumors that were 2 cm or less, due to the penetration of the tumor by the smaller antibody fragment; much larger tumors sometimes required some time before “filling in” of activity was observed (Fig. 2). Of 122 patients with known disease, the

TABLE 1
Comparison of Sensitivity of CEA-Scan[®] and SDM (Mostly CT) by Body Site*

	Abdomen (n = 69)	Liver (n = 81)	Pelvis (n = 81)
CEA-Scan TM			
No. patients	38	51	56
%	55.1	63.0	69.1
95% C.I.	42.6–67.1	51.5–73.4	57.9–78.9
SDM			
No. patients	22	52	39
%	31.9	64.2	48.1
95% C.I.	21.2–44.2	52.8–74.6	36.9–59.5
p^{\dagger}	0.007	ns [‡]	0.005

*From Moffat et al. (3).
[†]p values determined by McNemar's test.
[‡]ns = not significant.

positive predictive value was significantly higher when both modalities were positive, as compared to when SDM were positive and CEA-Scan[®] was negative (98% versus 68%, $p < 0.0001$), potentially obviating the use of biopsy for histological confirmation of a suspected lesion when both tests are positive. When CEA-Scan[®] was added to SDM, imaging accuracy was significantly enhanced (93% versus 83% for SDM used alone, $p = 0.0005$). In 88 patients with suspected recurrence that was not disclosed by SDM (occult disease), imaging accuracy was also enhanced by CEA-Scan[®] when combined with SDM (61% versus 33% for SDM alone, $p = 0.0004$; three patients who were initially false-negative by CT were reevaluated after CEA-Scan[®] and corrected to be true-positive). When evaluating different organ regions, CT and CEA-Scan[®] were found to

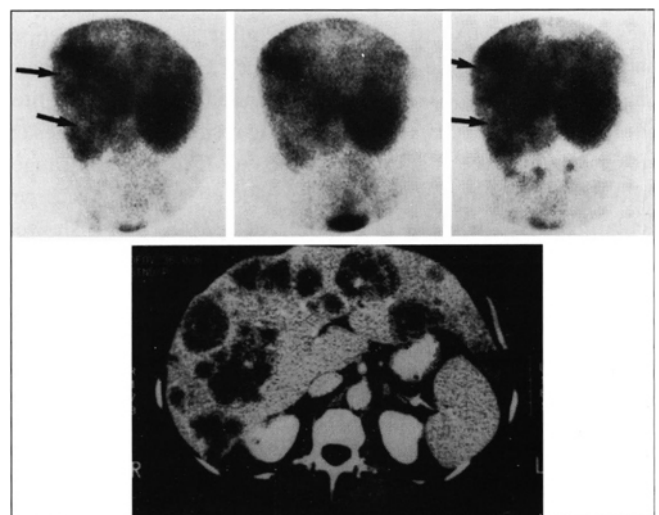


FIGURE 2. (Top) Planar anterior abdomen views obtained at 2 (left), 4 (middle) and 24 hr (right) postinfusion of 30 mCi $^{99\text{m}}\text{Tc}$ -CEA-Scan[®] in a patient with metastatic colon carcinoma. Note that nearly all liver lesions are initially cold at 2 and 4 hr after infusion, but that some (arrows) show a substantial filling in 24 hr after the infusion. (Bottom) A CT scan of the abdomen showing the metastatic liver lesions.

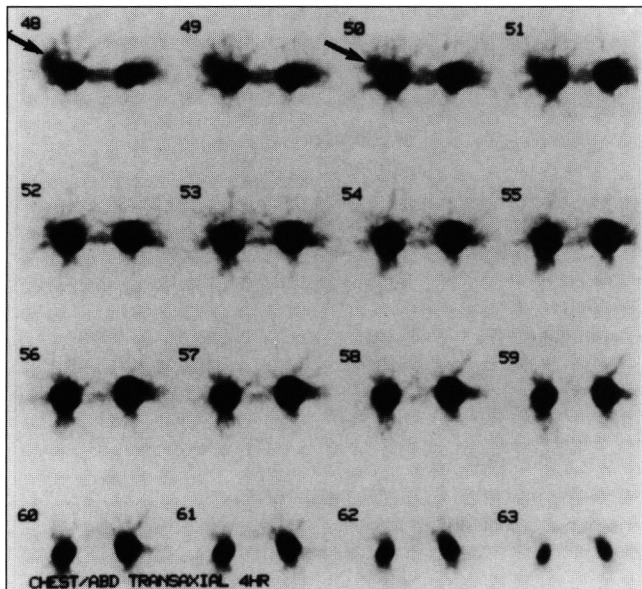


FIGURE 3. SPECT scan obtained 4 hr postinjection of 30 mCi ^{99m}Tc -CEA-Scan[®] in a patient with occult colon cancer (negative CT). Transverse slices clearly showed a liver lesion in the posterior segment of the right liver lobe (arrow) despite the intense uptake of the right kidney. Liver metastasis was confirmed by surgery.

be equivalent and complementary in the liver, but in the extrahepatic abdomen and pelvis, CEA-Scan[®] was significantly better than CT (Table 1).

SPECT imaging was found to be important for identifying tumors, especially small ones near major organs of high radioactivity, such as the kidneys (Fig. 3), which are known to metabolize small antibody fragments and peptides. Nonspecific intestinal activity could be seen in some of the later images (after 7 hr) and could be identified by showing a change in location when comparing early and late scans. Only two patients in the series developed an immune antimouse antibody response (HAMA) to CEA-Scan[®] after a single injection; none of 22 assessable patients developed HAMA after receiving two injections (3). In terms of the role of plasma CEA titer in influencing the CEA-Scan[®] imaging results, blood values up to 250 ng/ml (where 2.5 ng/ml is the cutoff for normal range) did not show complexation of the injected antibody with circulating CEA, while a blood titer of >2,000 ng/ml showed about 50% complexation yet did not interfere with tumor imaging (Fig. 4). This is probably due to the use of one arm for antigen binding in an antibody Fab' fragment, as well as the relatively modest affinity of the CEA antibody used in CEA-Scan[®] (about $10^8 M/l^{-1}$).

The conclusions from these studies are that CEA-Scan[®] is a same-day imaging method that adds clinically significant information in the assessment of the presence, location and extent of disease in colorectal cancer patients with recurrent or metastatic cancer, and only rarely induces a HAMA response (3).

Since concordant findings of CEA-Scan[®] and SDM (mostly CT) resulted in the most reliable outcome predictions, as confirmed by surgery, the relative role of these two imaging modalities in the presurgical evaluation of patients being considered for resection of locally recurrent or metastatic colorec-

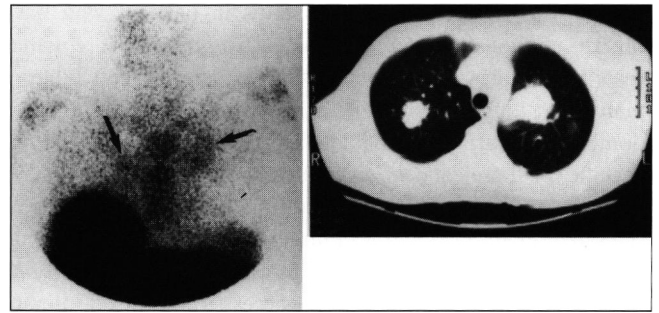


FIGURE 4. Planar anterior chest view (left) obtained 24 hr postinjection of 30 mCi ^{99m}Tc -CEA-Scan[®] in the same patient as in Figure 2. The scan demonstrates clear evidence of lung metastases seen by CT (right) in both upper lobes of the lungs, despite high CEA level in the patient (2592 ng/ml) and 47% antibody complexation with the circulating antigen.

tal cancer was evaluated in another study. In a blinded analysis of 209 patients with known or suspected colorectal cancer (one less patient than those included in the study of imaging performance already discussed), the accuracy of CEA-Scan[®], alone and combined with CT, was compared to that of CT for predicting abdominopelvic tumor resectability by correlating the results with surgical and histopathological findings. CEA-Scan[®] alone or combined with CT was found to be significantly more accurate for predicting surgical outcome than use of CT by itself (19). When both tests were concordant for resectability, then 100% were truly resectable. When the two tests were discordant, CEA-Scan[®] was correct substantially more often than CT (Table 2).

These results were true for the entire abdominopelvic cavity or for the liver. This analysis thus led to the conclusion that CEA-Scan[®] was more accurate than CT for assessing resectability in all patients undergoing evaluation for potentially curative abdominal resection of colorectal cancer, and in a subset of patients with suspected or proven liver metastases. The additional use of CEA-Scan[®] with CT potentially more than doubles the number of patients who could avoid unnecessary abdominopelvic surgery and could increase those who are potentially resectable for cure by 40%. Given that surgical resection is the only method currently available to cure recurrent or metastatic colorectal carcinoma (3,19), these are profound results which demonstrate the clinical utility of determining the location and extent of colorectal cancer preoperatively.

CEA-Scan[®] (Arcitumomab) in Other Cancer Types

Several carcinomas other than colorectal have been found to express CEA in increased quantities and virtually all of these tumor types have been shown to be targeted by radiolabeled anti-CEA antibodies (4,16,20-24). These include esophageal, gastric, pancreatic, biliary, mammary, lung, medullary thyroid, ovarian, uterine (endometrial and cervical) and urinary bladder carcinomas (Table 3). Of these, our own efforts focused on lung, mammary, medullary thyroid, pancreatic and ovarian carcinomas. Various carcinomas of the lung express CEA and, thus, can be targeted by anti-CEA antibodies (22). CEA-Scan[®]'s potential value in lung carcinoma patients, as well as in

TABLE 2
Prediction of Surgical Outcome when CT and CEA-Scan® are Concordant and Discordant

	Concordance			Discordance		
	No. patients	No. correct	Percent correct	No. patients	CT correct	CEA-Scan® correct
Resectable	45	30	67	37	11 (30%)	26 (70%)
Nonresectable	14	14	100	18	3 (17%)	15 (83%)
Negative	45	29	64	16	11 (69%)	5 (45%)
Total	104	73	70	71	25 (35%)	46 (65%)

*Adapted from Hughes et al. (19).

patients with other cancer types, may well be to determine the extent of disease, for presurgical staging, by means of a single body survey followed by selected SPECT imaging. This now requires multiple imaging tests to identify tumor sites in the viscera, brain, bone and bone marrow. In breast cancer, there is preliminary evidence that CEA-Scan® can disclose tumors missed by mammography (23) and can help differentiate between benign, abnormal hyperplasia with atypia and carcinoma, thus, having a higher specificity than mammography (24). If substantiated by additional trials, this could decrease the number of unnecessary biopsies being performed at present in 75% of women having a pathological finding on routine mammography. The use of CEA-Scan® in the management of patients with medullary thyroid carcinoma has been extremely encouraging, since it can result in the identification of occult disease suggested only by elevated serum calcitonin and/or CEA (25). Although pancreatic and ovarian carcinomas usually are advanced when initially diagnosed, CEA-Scan® has the potential of better assessing the extent of disease in patients being considered for debulking or aggressive surgery. In ovarian carcinoma, this imaging method may be important to define those patients who are eligible for anti-CEA radioimmunotherapy, as discussed below. An example of identifying a medullary thyroid carcinoma with CEA-Scan® is shown in Figure 5. CEA imaging appears to have use in the diagnostic evaluation of perhaps more than 70% of patients with solid cancers, including the most frequently occurring and most lethal tumors.

TABLE 3
Cancers Potentially Detectable by CEA-Scan®

- Certain head and neck squamous-cell carcinomas
- Esophageal carcinoma
- Gastric carcinoma
- Colorectal carcinoma
- Pancreatic carcinoma
- Biliary carcinoma
- Medullary thyroid carcinoma
- Lung carcinomas
- Mammary carcinoma
- Ovarian (mucinous and mixed) carcinoma
- Uterine (endometrial and cervical) carcinomas
- Urinary bladder carcinoma

Cancer Imaging with Other Antibodies

Many antibodies against diverse human tumor-associated markers have been developed and studied clinically as targeting or therapeutic agents in recent years (1,5). Any of these that demonstrate a sufficient gradient between tumor and normal tissues can, in principle, be used as cancer imaging agents, and antibody Fab' fragments labeled with ^{99m}Tc, as in CEA-Scan®, are undergoing clinical evaluation. LymphoScan™ consists of a B-cell-specific (CD22) MAb for detecting and staging non-Hodgkin's lymphomas and has shown promising results in initial clinical trials comparing this agent to ⁶⁷Ga or other imaging agents or modalities (26-29). An example of lymphoma imaging with LymphoScan™ is shown in Figure 6. Alpha-fetoprotein (AFP) is an oncofetal antigen that is shed into the blood, similar to CEA, which is produced in elevated amounts by testicular and ovarian germ-cell and hepatocellular carcinomas. Anti-AFP antibodies have been shown to target and image these neoplasms (30,31). AFP-Scan™ (Immuno-medics Inc., Morris Plains, NJ), which is also a Fab' labeled directly with ^{99m}Tc, is under clinical study to determine its role in the management of patients with these tumor types.

Prospects for CEA Radioimmunotherapy

The successful targeting of CEA-expressing cancers with anti-CEA antibodies has stimulated interest in treating these

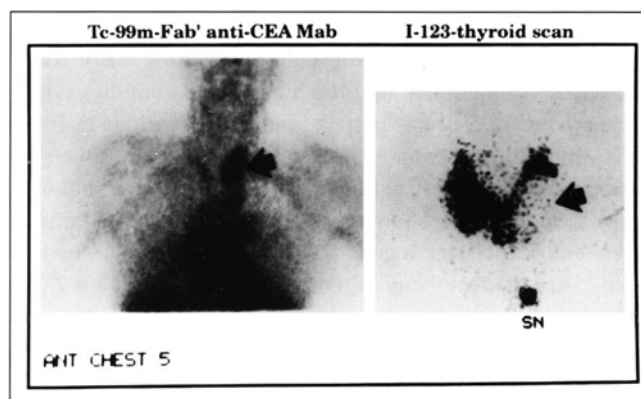


FIGURE 5. Targeting of primary medullary thyroid cancer in the left lobe of the thyroid 5 hr postinfusion of ^{99m}Tc-CEA-Scan® (left). Thyroid scan (right) performed with ¹²³I showed a cold defect corresponding to the area of increased uptake on the antibody scan.

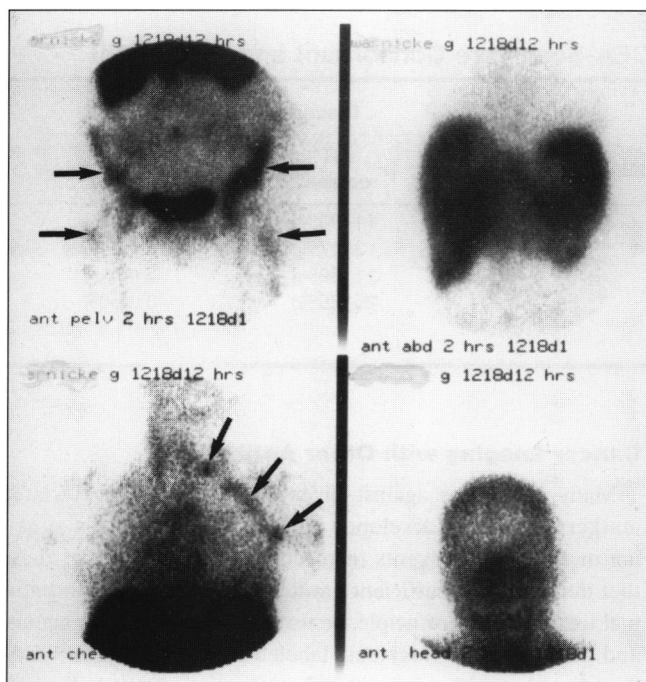


FIGURE 6. Technetium-99m LymphoScan™ images performed after intravenous infusion of 30 mCi (2.0 mg). As early as 2 hr, the scan shows a left chest wall lymphoma, left superclavicular, and left axillary lymph node metastases, in addition to bony involvement of the pelvic bones and both proximal femurs. Bony involvement was verified by a bone scan obtained within 5 wk.

cancers with the appropriate therapeutic radionuclides conjugated to the antibodies, thus instituting a systemic isotopic therapy or radioimmunotherapy (RAIT). The first animal studies involving a CEA-producing human colonic carcinoma grafted to hamsters and receiving purified anti-CEA IgG labeled with ^{131}I showed high tumor growth-inhibition after a single injection of a tolerable dose (32). Subsequent experimental and clinical studies have shown the influence of using the $\text{F}(\text{ab}'_2)$ form, other labels, combining RAIT with external irradiation and dose-enhancement under bone marrow protection or transplantation (32–34). Of particular importance is the finding that CEA RAIT in a metastatic human tumor xenograft model has profound anticancer effects in minimal, micro-metastatic disease (35). Many of these experimental findings are being confirmed in early clinical trials of CEA RAIT, especially the paradigm that the highest radiation doses delivered are inversely proportional to tumor size, with up to 10,000 cGy achieved in tumors of 1 cm or less (36). Dose-escalation studies in patients with colorectal, medullary thyroid and ovarian carcinomas are showing evidence of anticancer effects, even before optimal regimens and repeated dose schedules with humanized antibody forms have been performed (37–40). Initial studies with humanized forms of CEA antibodies have shown very similar tumor targeting and pharmacokinetic properties, suggesting that these less immunogenic agents should allow much higher radiation doses to be delivered to CEA-expressing cancers by means of repeated, high doses under bone marrow protection. Clinical studies are in progress to test this thesis.

Various lymphomas and leukemias have been particularly responsive to RAIT, even at relatively low radiation doses due to the radiosensitivity of hematological malignancies (41,42). Different antibodies labeled with either ^{131}I or ^{90}Y have shown high response rates when used in patients who have failed conventional treatments, and some of these responses have been durable for up to 2 yr (41,43–45). These findings strengthen our conviction that RAIT at sufficiently high doses can become successful for treating many solid, relatively radioresistant neoplasms, if concomitant toxicities to the bone marrow and possibly other organs can be mitigated or prevented. Examples include autologous bone marrow or stem cell transplantation for controlling myelotoxicity, and possibly the administration of cationic amino acids to reduce renal reabsorption of small fragments and peptides for potentially reducing renal toxicity (46). The era of cancer therapy with radiolabeled antibodies should follow rapidly on the foundations laid by the radiolabeled antibodies used as tumor targeting and imaging agents, once repeated administrations and higher tumor doses and therapeutic indices are achieved.

ACKNOWLEDGMENTS

We thank our colleagues at St. Joseph's Hospital and Medical Center in Paterson, NJ (especially Drs. A. Rubin and T. Herskovic), at the Garden State Cancer Center (Drs. T.M. Behr and J. Siegel) and at Immunomedics, Inc. (Drs. C.M. Pinsky, L. Hammershaimb, H.J. Hansen, G. Griffiths and S. Leung) for their collaboration. Our research is supported in part by USPHS grants CA 39841, CA 66906 and CA 67026 from the NIH, and grant FDR 001190 from the FDA.

REFERENCES

1. Goldenberg DM. Monoclonal antibodies in cancer detection and therapy. *Am J Med* 1993;94:297–312.
2. Goldenberg DM. Monoclonal antibody products: new advances. *J Biotechnol Healthcare* 1996;2:112–422.
3. Moffat FL Jr, Pinsky CM, Hammershaimb L, et al. Clinical utility of external immunoscintigraphy with the IMMU-4 technetium-99m Fab' antibody fragment in patients undergoing surgery for carcinoma of the colon and rectum: results of a pivotal, phase III trial. *J Clin Oncol* 1996;14:2295–2305.
4. Goldenberg DM, DeLand F, Kim E, et al. Use of radiolabeled antibodies to carcinoembryonic antigen for the detection and localization of diverse cancers by external photoscanning. *N Engl J Med* 1978;298:1384–1386.
5. Goldenberg DM, ed. *Cancer imaging with radiolabeled antibodies*. Boston: Kluwer Academic Publishers; 1990.
6. Goldenberg TJ, Wlodkowski TM, Sharkey RM, et al. Colorectal cancer imaging with iodine-123-labeled CEA monoclonal antibody fragments. *J Nucl Med* 1993;34:61–70.
7. Griffiths GL, Goldenberg DM, Jones AL, Hansen HJ. Radiolabeling of monoclonal antibodies and fragments with technetium and rhenium. *Bioconj Chem* 1992;3:91–99.
8. Hansen HJ, Jones AL, Sharkey RM, et al. Preclinical evaluation of an instant $^{99\text{m}}\text{Tc}$ -labeling kit for antibody imaging. *Cancer Res* 1990;50:794s–798s.
9. Gold P, Freedman SO. Specific carcinoembryonic antigens of the human digestive system. *J Exper Med* 1965;122:467–481.
10. Hansen HJ, Snyder JJ, Miller E, et al. Carcinoembryonic antigen (CEA) assay. A laboratory adjunct in the diagnosis and management of cancer. *Human Pathol* 1974;5:139–147.
11. Van Nagell JR Jr, Donaldson ES, Wood EG, Goldenberg DM. The clinical

- significance of carcinoembryonic antigen in the plasma and tumors of patients with gynecologic malignancies. *Cancer* 1978;42:1527-1532.
12. Moore TL, Kantrowitz PA, Zamcheck N. Carcinoembryonic antigen (CEA) in inflammatory bowel disease. *JAMA* 1972;222:944-947.
 13. Goldenberg DM, Sharkey RM, Primus FJ. Carcinoembryonic antigen in histopathology: immunoperoxidase staining of conventional tissue sections. *J Natl Cancer Inst* 1976;57:11-22.
 14. Sharkey RM, Hagihara PF, Goldenberg DM. Localization by immunoperoxidase and estimation by radioimmunoassay of carcinoembryonic antigen in colonic polyps. *Br J Cancer* 1977;35:179-189.
 15. Mach JP, Carrell S, Merenda C, et al. In vivo localization of anti-CEA antibody in colon carcinoma: can the results obtained in the nude mice model be extrapolated to the patient situation? *Eur J Cancer* 1978;1:113-120.
 16. Goldenberg DM, Kim EE, DeLand FH, Bennett S, Primus FJ. Radioimmuno-detection of cancer with radioactive antibodies to carcinoembryonic antigen. *Cancer Res* 1980;40:2984-2992.
 17. Primus FJ, Goldenberg DM. Immunological considerations on the use of goat antibodies to carcinoembryonic antigen for the radioimmuno-detection of cancer. *Cancer Res* 1980;40:2979-2983.
 18. Goldenberg DM, Goldenberg H, Sharkey RM, et al. In vivo antibody imaging for the detection of human tumors. In: Goldenberg DM, ed. *Cancer imaging with radiolabeled antibodies*. Boston: Kluwer Academic Publishers; 1990:273-292.
 19. Hughes K, Pinsky CM, Petrelli NJ, et al. Use of carcinoembryonic antigen radioimmuno-detection and computed tomography for predicting the resectability of recurrent colorectal cancer. *Ann Surg*; in press.
 20. Van Nagell JR Jr, Kim E, Casper S, et al. Radioimmuno-detection of primary and metastatic ovarian cancer using radiolabeled antibodies to carcinoembryonic antigen. *Cancer Res* 1980;40:502-506.
 21. Goldenberg DM. Imaging and therapy of gastrointestinal cancers with radiolabeled antibodies. *Am J Gastroenterol* 1991;86:1392-1403.
 22. Kramer EL, Noz ME, Liebes L, et al. Radioimmuno-detection of non-small cell lung cancer using technetium-99m-anticarcinoembryonic antigen IMM-4 Fab' fragment: preliminary results. *Cancer* 1994;73(suppl):890-895.
 23. Gulec SA, Serafini AN, Moffat FL, et al. Radioimmuno-scintigraphy of breast carcinoma using technetium-99m-labeled Fab' fragment of anticarcinoembryonic antigen monoclonal antibody IMM-4 (CEA-Scan™). *Diagn Oncol* 1994;95:4:209-213.
 24. Rosner D, Abdel-Nabi H, Panaro V, Erb D, Wild L, Hreshchysyn M. Immunoscintigraphy (IS) may reduce the number of surgical biopsies in women with benign breast disease (BBD) and indeterminate mammograms [Abstract]. *Proc Am Soc Clin Oncol* 1996;15:102.
 25. Juweid M, Sharkey RM, Behr T, et al. Improved detection of medullary thyroid cancer with radiolabeled monoclonal antibodies to carcinoembryonic antigen. *J Clin Oncol* 1996;14:1209-1217.
 26. Stein R, Shih LB, Sharkey RM, Hansen HJ, Goldenberg DM. Imm-RAID™-LL2[Tc-99m] and Imm-RAIT™-LL2[I-131]. *Drugs of the Future* 1994;18:997-1004.
 27. Baum RP, Niesen A, Hertel A, et al. Initial clinical results with technetium-99m-labeled LL2 monoclonal antibody fragment in the for radioimmuno-detection of B-cell lymphomas. *Cancer* 1994;73(suppl):896-899.
 28. Blend MJ, Hyun H, Kozloff M, et al. Improved staging of B-cell non-Hodgkin's lymphoma patients with ^{99m}Tc-labeled LL2 monoclonal antibody fragment. *Cancer Res* 1995;55:5764s-5770s.
 29. Becker WS, Behr TM, Cumme F, et al. Gallium-67-citrate versus ^{99m}Tc-labeled LL2-Fab' (anti-CD22) fragments in the staging of B-cell non-Hodgkin's lymphoma. *Cancer Res* 1995;55:5771s-5773s.
 30. Goldenberg DM, Kim E, DeLand FH, et al. Clinical studies on the radio-immuno-detection of tumors containing alpha-fetoprotein. *Cancer* 1980;45:2500-2505.
 31. Goldenberg DM, Goldenberg H, Higginbotham-Ford E. Imaging of primary and metastatic liver cancer with iodine-131 monoclonal and polyclonal antibodies against alphafetoprotein. *J Clin Oncol* 1987;5:1827-1835.
 32. Goldenberg DM, Gaffar SA, Bennett SJ, Beach JL. Experimental radioimmuno-therapy of a xenografted human colonic tumor (GW-39) producing carcinoembryonic antigen. *Cancer Res* 1981;41:4354-4360.
 33. Goldenberg DM, ed. *Cancer therapy with radiolabeled antibodies*. Boca Raton, FL: CRC Press; 1995.
 34. Wilder RB, DeNardo GL, DeNardo SJ. Radioimmuno-therapy: recent results and future directions. *J Clin Oncol* 1996;14:1383-1400.
 35. Sharkey RM, Weadock KS, Natale A, et al. Successful radioimmuno-therapy for lung metastasis of human colonic cancer in nude mice. *J Natl Cancer Inst* 1991;83:627-632.
 36. Siegel JA, Pawlyk DA, Lee RE, et al. Tumor, red marrow and organ dosimetry for ¹³¹I-labeled anti-carcinoembryonic antigen monoclonal antibody. *Cancer Res* 1990;50:1039s-1042s.
 37. Juweid M, Sharkey RM, Behr T, et al. Radioimmuno-therapy of medullary thyroid cancer with iodine-131-labeled anti-CEA antibodies. *J Nucl Med* 1996;37:905-911.
 38. Juweid ME, Sharkey RM, Behr T, et al. Radioimmuno-therapy of patients with small-volume tumors using iodine-131-labeled anti-CEA monoclonal antibody NP-4 F(ab')₂. *J Nucl Med* 1996;37:1504-1510.
 39. Behr TM, Sharkey RM, Juweid MI, et al. Factors influencing the pharmacokinetics, dosimetry and diagnostic accuracy of radioimmuno-detection and radioimmuno-therapy of CEA-expressing tumors. *Cancer Res* 1996;56:1805-1816.
 40. Juweid M, Sharkey RM, Alavi A, et al. Regression of advanced refractory ovarian cancer treated with ¹³¹I-labeled anti-CEA monoclonal antibody. *J Nucl Med* 1997; in press.
 41. Knox SJ. Radioimmuno-therapy of the non-Hodgkin's lymphomas. *Semin Radiat Oncol* 1995;329:459-465.
 42. Goldenberg DM, Horowitz JA, Sharkey RM, et al. Targeting, dosimetry and radioimmuno-therapy of B-cell lymphomas with iodine-131-labeled LL2 monoclonal antibody. *J Clin Oncol* 1991;9:548-564.
 43. Press OW, Eary JF, Appelbaum FR, et al. Radiolabeled-antibody therapy of B-cell lymphoma with autologous bone marrow support. *N Engl J Med* 1993;329:1219-1224.
 44. Kaminski MS, Zasadny KR, Francis IR, et al. Radioimmuno-therapy of B-cell lymphoma with [¹³¹I]anti-B1 (anti-CD20) antibody. *N Engl J Med* 1993;329:459-465.
 45. DeNardo GL, DeNardo SJ. Treatment of B-lymphocyte malignancies with ¹³¹I-Lym-1 and ⁶⁷Cu-21T-BAT-Lym-1 and opportunities for improvement. In: Goldenberg DM, ed. *Cancer therapy with radiolabeled antibodies*. Boca Raton, FL: CRC Press; 1995:217-227.
 46. Behr TM, Becker WS, Sharkey RM, et al. Reduction of renal uptake of monoclonal antibody fragments by amino acid infusion. *J Nucl Med* 1996;37:29-33.