

Full Bladder Effect: A Technical Pitfall in a Renal Transplant Patient

Maria Machado, Mordechai Lorberboym, and Abdelhamid H. Elgazzar

Department of Radiology, Division of Nuclear Medicine, The Mount Sinai School of Medicine, New York, New York

We present three sequential renal studies in a renal transplant patient, illustrating how technical factors can adversely affect the interpretation of renal imaging studies.

Methods: The studies were performed in two dynamic modes after intravenous injection of ^{99m}Tc DTPA. Time-activity curves of the transplanted kidney were later generated. The patient had a Foley catheter during the first study, no catheter in the second study and reinsertion of a catheter in the third study.

Results: The first study revealed good perfusion and function of the transplanted kidney. Three days later, the follow-up renal study revealed stable blood flow, but delayed parenchymal excretion with a photon-deficient area seen adjacent to the transplanted kidney. This was retrospectively interpreted as a full urinary bladder at the time of imaging. A repeat renal study, after insertion of a catheter, showed a normally perfused and functioning renal transplant.

Conclusion: A full urinary bladder on a renal study may simulate the development of acute tubular necrosis, particularly in patients with a transplanted kidney and/or urine outflow obstruction. The bladder should always be empty prior to dynamic renal studies, as a full bladder can cause significant confusion in scan interpretation.

Key Words: renal transplant; technical pitfall; technetium- ^{99m}Tc -DTPA; renal imaging; full bladder effect

J Nucl Med Technol 1996; 24:321-324

MATERIALS AND METHODS

A 50-year old man, with a history of noninsulin-dependent diabetes mellitus, hypertension, coronary artery disease and hemodialysis for end-stage renal disease for nine years, was referred for baseline renal imaging four days after cadaveric renal transplantation. At the time of imaging the patient was clinically stable with a creatinine level of 3.8 mg/dl which had dropped from a preoperative level of 5.9 mg/dl.

After good hydration of the patient, the study was performed following intravenous injection of 10.5 mCi ^{99m}Tc -DTPA. The first dynamic mode was 2-sec frames for 60 sec.

The second dynamic mode was 30-sec frames for 29 min. A time-activity curve for the transplanted kidney was later generated. The patient had a Foley catheter during the study.

RESULTS

The study revealed good perfusion (Fig. 1A) and function (Fig. 1B) of the transplanted kidney with good excretory function as confirmed by the time-activity curve (Fig. 1C). Three days after the baseline study, the patient complained of lower abdominal discomfort and distention despite an interval improvement in creatinine level (2.7 mg/dl). A follow-up renal study after the injection of 15 mCi ^{99m}Tc -DTPA and good hydration was obtained using the same format. The study revealed stable flow (Fig. 2A) with delayed parenchymal excretion (Fig. 2B, C). A photon-deficient area infero-medial to the transplanted kidney (arrowheads) was also noted which showed some activity later on a 4-hr delayed image (arrow). These findings were felt to be related to a full urinary bladder. When questioned, it was found that the patient was unable to void before the study despite good prestudy hydration. It was also found that a Foley catheter was removed two days before the study.

Communication with the referring physician revealed that the patient had recent difficulty urinating and his complaint of fullness started after removing the catheter. It was decided to repeat the renal study for further evaluation of kidney function after insertion of a Foley catheter. No adjustment in medications was done in the interval.

A repeat ^{99m}Tc -DTPA renal study obtained three days after a Foley catheter was inserted using 14 mCi of the radiotracer and the same format. The study showed a normally perfused and functioning renal transplant (Fig. 3A-C) with no significant changes compared to the baseline study (Fig. 1).

DISCUSSION

The changes of abnormally delayed parenchymal excretion seen on the second study (Fig. 2) were confirmed by a repeat study to be secondary to a full urinary bladder causing back

For correspondence or reprints contact: Abdelhamid H. Elgazzar, MD, The Mount Sinai Medical Center, Box 1141, One Gustave L. Levy Place, New York, NY 10029-6574.

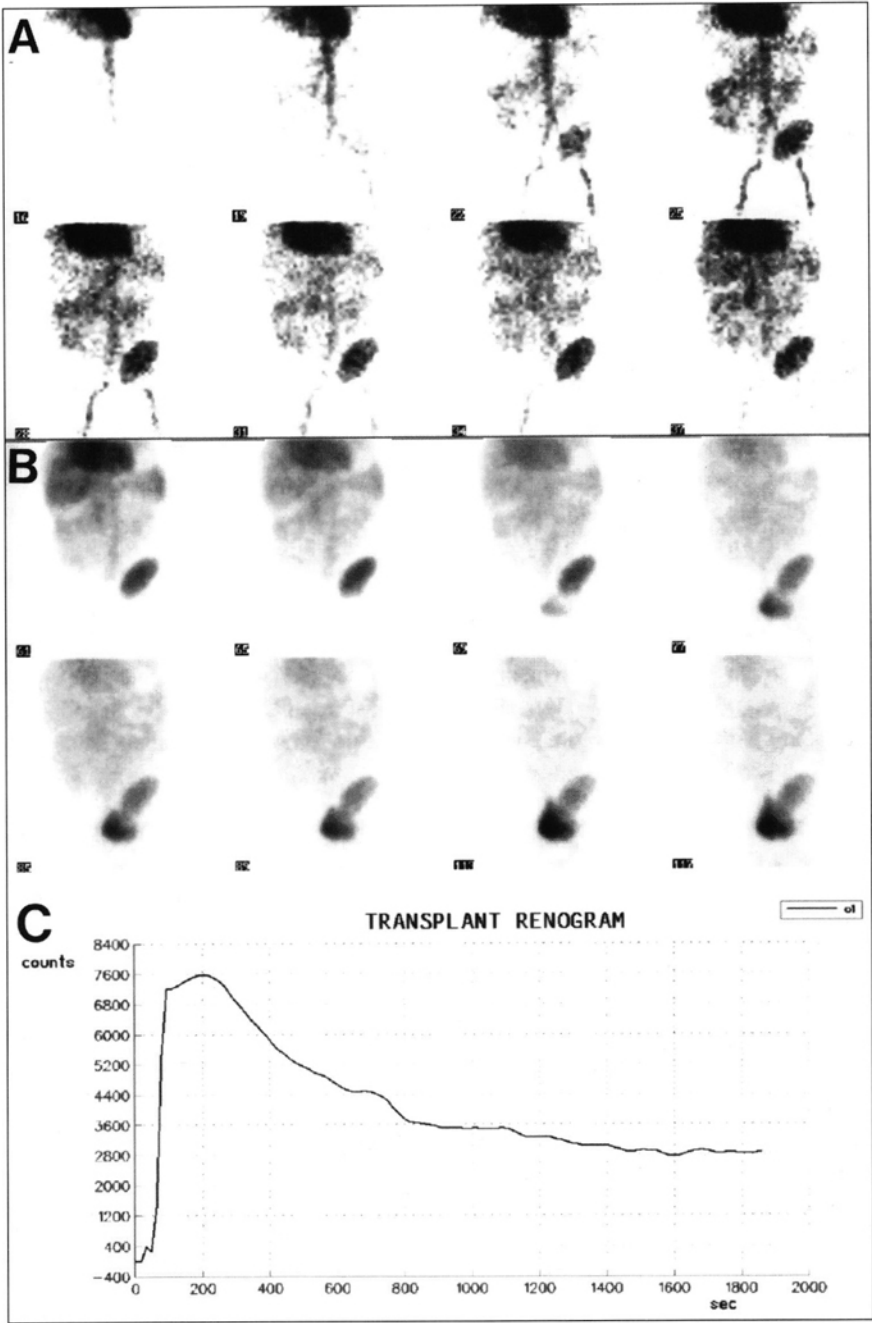


FIGURE 1. The initial study showing (A) good perfusion and (B) function of the transplanted kidney with good excretory function as confirmed by the (C) time-activity curve.

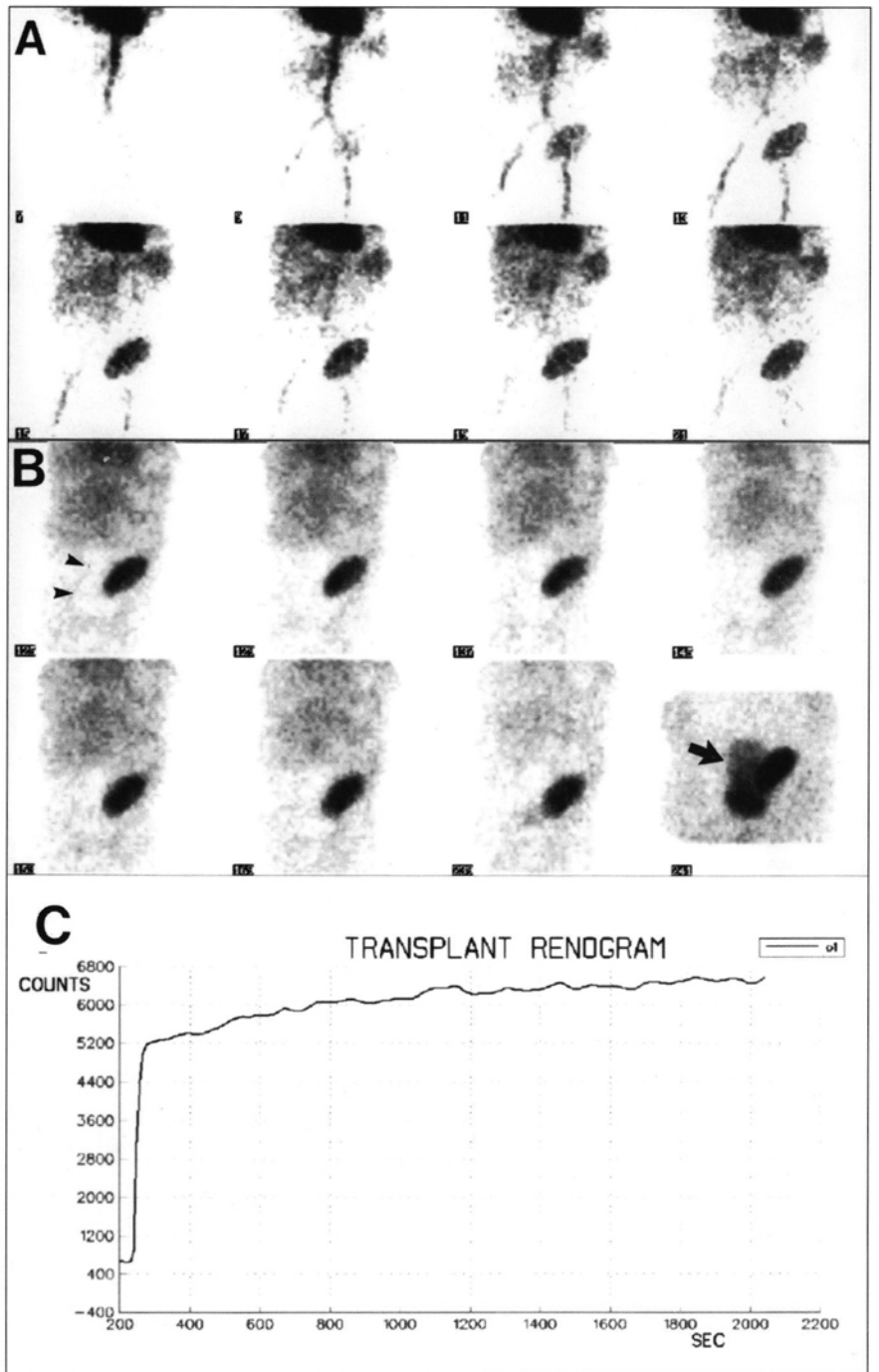


FIGURE 2. A follow-up renal study reveals (A) stable flow with (B, C) delayed parenchymal excretion. A photon-deficient area infero-medial to the transplanted kidney (arrowheads) shows activity later on a 4-hr delayed image (arrow).

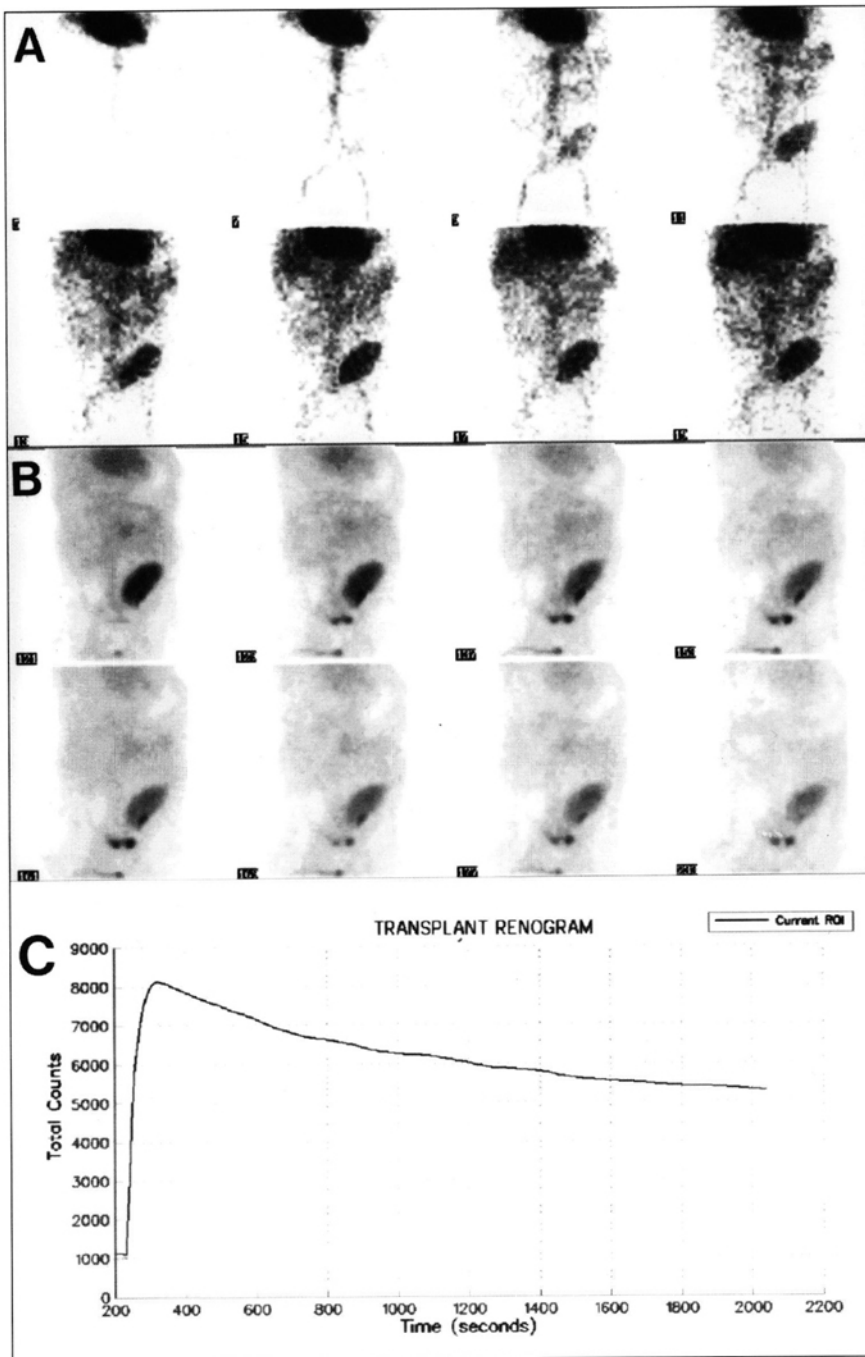


FIGURE 3. (A-C) A repeat ^{99m}Tc -DTPA renal study, after a Foley catheter was inserted, demonstrates a normally perfused and functioning renal transplant with no significant changes compared with the baseline study.

pressure and impeding the urine output and parenchymal excretion that can falsely simulate acute tubular necrosis and/or significant urine outflow obstruction. Furthermore, the photon-deficient area of the full bladder, that may assume various shapes, could be confused with an abnormal fluid collection.

CONCLUSION

Care should be taken to assure the patient has an empty bladder before renal studies to avoid frequent and, at times,

significant false changes (1,2) leading to incorrect interpretation.

REFERENCES

1. Jones DA, Lupton EW, George NJ. Effect of bladder filling on upper tract urodynamics in man. *Br J Urol* 1990;65:492-496.
2. George NR, O'Reilly PH, Barnard RJ, et al. Practical management of patients with dilated upper tract and chronic retention of urine. *Br J Urol* 1984;56:9-12.