

## Effective SPECT of the Cervical Spine

Jennifer L. Prekeges, Brian Eisenberg and Karin Price-Eng

Department of Radiology, Virginia Mason Medical Center, and Seattle Nuclear Medicine/Ultrasound Associates, Seattle, Washington

**Objective:** SPECT of the thoracic and lumbar spine has become a common bone imaging procedure in nuclear medicine, however, SPECT of the cervical spine is used to a much lesser degree. This is due in part to the normal lordotic curvature of the cervical spine. We present a technique for cervical spine SPECT that corrects the normal curvature and produces adequate tomographic images.

**Methods:** Two SPECT studies of the cervical spine of a normal volunteer were acquired. One study had the volunteer lying flat on the tomographic table (HOR), while the other had her head on the angled headrest of the tomographic table (ANG). The neck support of the headrest has an angulation of 50° relative to the horizontal axis of the table. Both studies were processed using the same Butterworth filter. The HOR study was reoriented to a sagittal angle perpendicular to the axis of the table, while the ANG study was obliquely reoriented perpendicular to the angle of the cervical spine.

**Results:** All vertebral bodies or posterior elements are seen to the same degree on contiguous slices in coronal images of the ANG study. In the HOR study, different portions of the vertebral bodies and/or posterior elements are evident on contiguous slices.

**Conclusions:** The ANG technique produces coronal SPECT images of the cervical spine that are considerably more useful than those of the HOR technique. The use of neck angulation to straighten out the cervical curve, combined with reorientation of SPECT images to the axis of the cervical spine, allows SPECT imaging to be effectively accomplished.

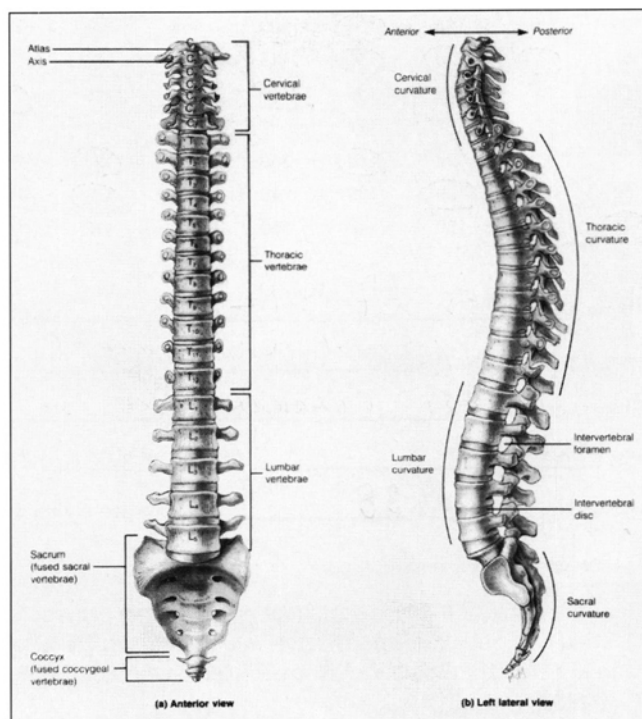
**Key Words:** SPECT; bone imaging technique; cervical spine

*J Nucl Med Technol* 1996; 24:100-103

The efficacy of bone imaging of the thoracic and lumbar spine has been improved by the use of SPECT. This increase in efficacy has not been extended to the cervical spine. A recent search of the literature produced only a single abstract that mentioned SPECT of the cervical spine (1). This lack of use of

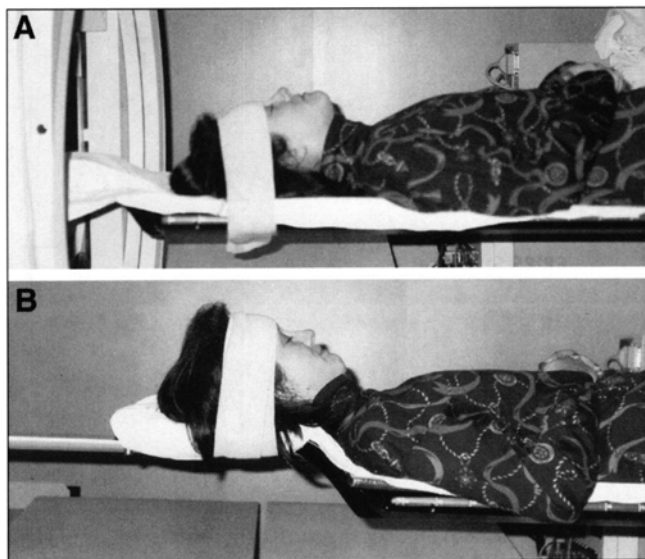
cervical SPECT is associated with the anatomy of the cervical spine (2).

Figure 1 shows two views of the spine. The anterior view shows that the cervical vertebrae are smaller and closer together than the thoracic and lumbar vertebrae. The lateral view demonstrates the natural lordotic curve of the cervical spine. In SPECT imaging, this lordotic curve puts different cervical vertebrae into different coronal planes. The purpose of this paper is to demonstrate that SPECT of the cervical spine can be improved by straightening out the cervical spine.



**FIGURE 1.** Anterior and lateral views of the spine demonstrate the smaller size and closer proximity of the cervical vertebrae relative to the thoracic and lumbar vertebrae. These views also show the natural lordotic curve of the cervical spine. (Reprinted by permission of West Publishing Company from: Stalheim-Smith A, Fitch GK. *Understanding Human Anatomy and Physiology*. 1993:180.)

For correspondence or reprints contact: Jennifer Prekeges, CNMT, Nuclear Medicine, H5-NU, Virginia Mason Medical Center, P.O. Box 900, Seattle, WA 98111.



**FIGURE 2.** (A) the HOR and (B) ANG studies demonstrating the position of the neck in both cases.

### MATERIALS AND METHODS

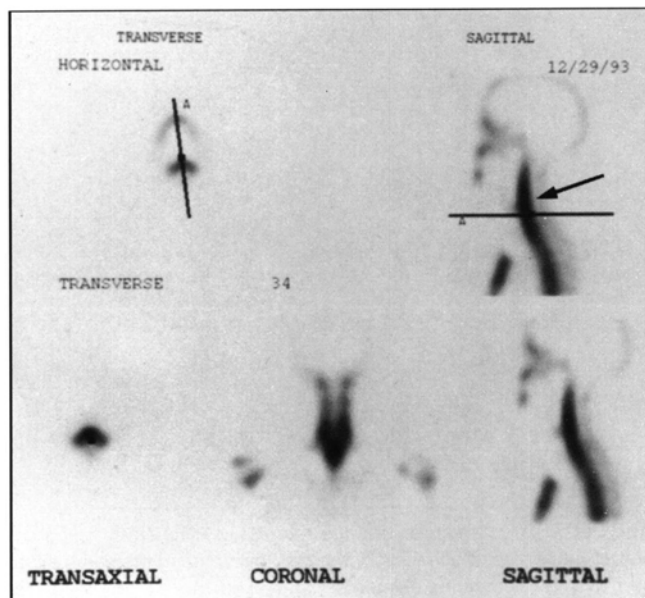
We acquired and analyzed two SPECT studies of the cervical spine of a normal volunteer four hr after intravenous administration of  $^{99m}\text{Tc}$ -MDP. Both studies were acquired with a dual-head gamma camera (Dual Detector Genesys, ADAC Laboratories, Milpitas, CA) for 128 total stops at 22 secs per stop. The acquisition matrix size was  $64 \times 64 \times 16$ . The positioning was different for the two studies (Fig. 2). In the horizontal (HOR) study, the volunteer was positioned supine on the imaging table with no head or neck support. In the angle (ANG) study, the volunteer placed her head on the raised headrest of the imaging table. The raised headrest produces a neck angulation of about  $50^\circ$  relative to the horizontal plane of the tomographic table.

Both studies were reconstructed using a Butterworth filter with an order of 6 and a cut off of 0.5. They were reoriented differently. The HOR study used a transverse angle of  $0^\circ$ , perpendicular to the plane of the imaging table and, therefore, to the longitudinal axis of the patient (Fig. 3). In the ANG study, the transverse angle was defined to be perpendicular to the longitudinal axis of the cervical spine (Fig. 4).

### RESULTS

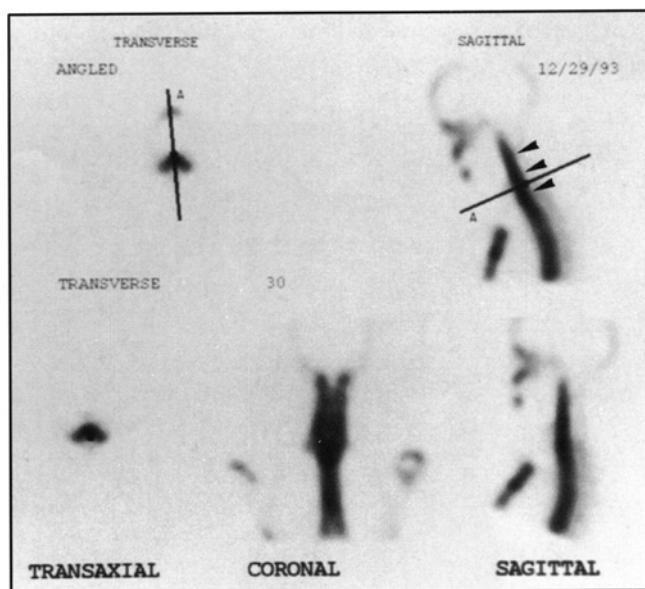
Coronal slices from the ANG and HOR studies are shown in Figures 5 and 6. As a consequence of eliminating the lordotic curvature and reorienting perpendicularly to the now-straight cervical spine, the ANG coronal slices (Fig. 5) show similar parts of the cervical vertebrae on contiguous coronal slices. All the vertebral bodies are seen in the same set of coronal slices (frames 27–28 in Fig. 5), while the all posterior elements are found together in a different set of coronal slices (frames 29–30 of Fig. 5).

In contrast, on the HOR study (Fig. 6) a single coronal slice may contain the vertebral bodies of some vertebrae and the

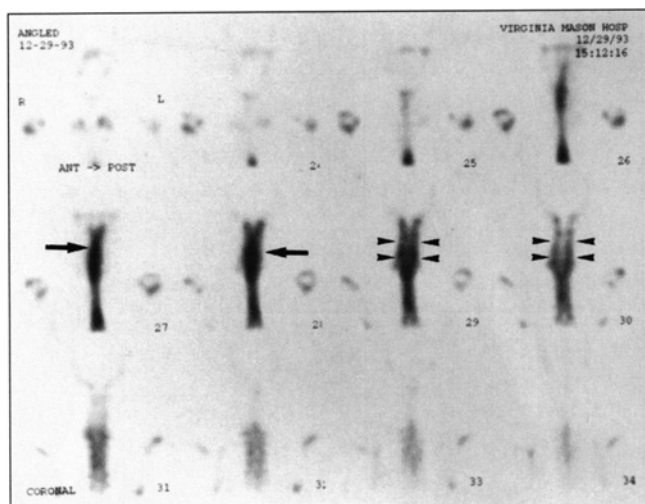


**FIGURE 3.** Reorientation of the HOR study, showing the normal lordotic curve on the sagittal view in the upper right (arrowhead). This view also shows the transverse angle used for reorientation.

posterior elements of other vertebrae. In Figure 6, frame 32 shows the C6 and C7 vertebral bodies (open arrow) and the posterior elements of the superior cervical vertebrae (closed arrow). The vertebral bodies of C3–C5 were already seen in frames 30 and 31 (arrowheads). The reader of the HOR images must compare intensities between slices rather than visualizing the same parts of all seven vertebrae in one slice. The ANG study in Figure 5 gives a view of the cervical spine that is easier to interpret and allows for a more valid comparison of cervical vertebrae.



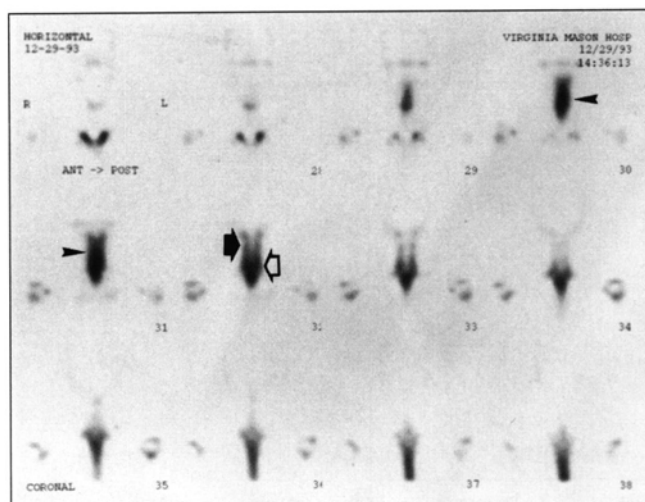
**FIGURE 4.** Reorientation of the ANG study, showing the straightening of the cervical curve (arrowheads) in upper right image. In this study the transverse angle is placed perpendicularly to the longitudinal axis of the cervical spine.



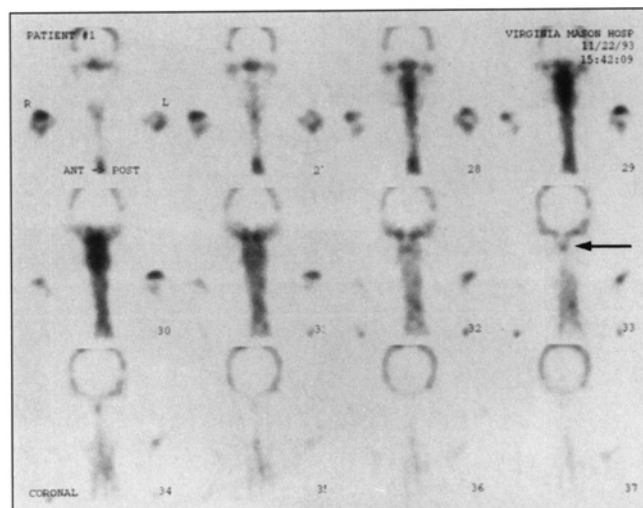
**FIGURE 5.** Coronal slices of the reoriented ANG study reveal the vertebral bodies of all levels of the cervical spine in the same slices (arrows) and posterior elements together in more posterior slices (arrowheads).

## DISCUSSION

SPECT imaging provides a three-dimensional scintigraphic image which can be viewed as a series of two-dimensional slices in each of three orthogonal planes. The main purpose for SPECT of the spine is to determine whether an area of increased activity is in the vertebral body or in the posterior elements. Various authors have used oblique reorientation of the lumbar spine to better delineate and localize abnormalities of primary bony pathology (3,4). To be considered diagnostic, such an area should be seen in at least two orthogonal planes. As noted in the introduction, the coronal slices become problematic when the spine curves significantly, because similar parts of the vertebrae are seen in different slices. The reference showing cervical spine SPECT images (1) makes this point, in that it shows only sagittal and transverse slices and no coronal slices.



**FIGURE 6.** Coronal slices of the reoriented HOR study reveal vertebral bodies of some vertebrae and posterior elements of other vertebrae in the same slice (see text for detailed description).



**FIGURE 7.** Coronal slices from Patient 1 show homogenous activity in the vertebral bodies and posterior elements without focal bony abnormality. Note the midline C2 activity (arrow).

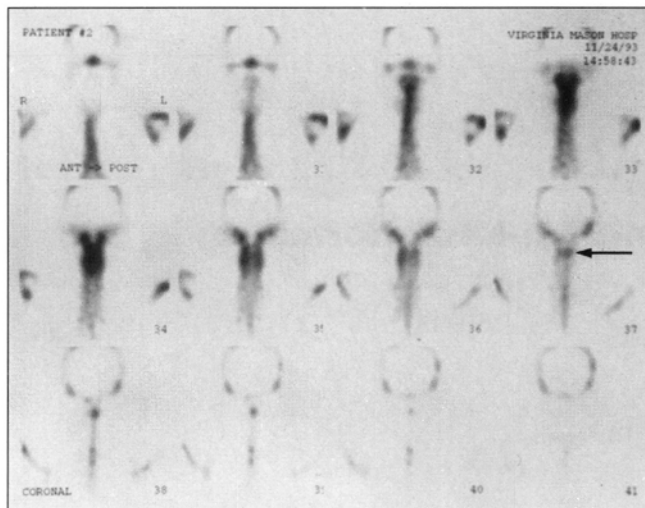
We believe our technique of straightening the cervical spine alleviates this difficulty and makes SPECT of the cervical spine more effective. The key to our technique is to raise the head as much as possible to straighten the neck. It is not necessary to use a table with an angled headrest; almost any form of head elevation (e.g., a stack of pillowcases) will work. A foam cushion is not recommended, as it would compress over the time of the scan and return the neck to a curved position. This technique is easily adaptable to any SPECT imaging protocol.

Even with elimination of the curvature of the cervical spine, SPECT images of the cervical spine never will be as "pretty" as those of the thoracic and lumbar spine. To the experienced reader of SPECT bone images, Figure 6 still does not show the individual vertebrae as distinct, separate entities due to their small size. But the technique described in this paper provides an improvement over other methods of positioning the cervical spine for SPECT imaging. Two patient studies (Figs. 7 and 8) illustrate the effectiveness of this technique.

Both Patient 1 and Patient 2 presented with a history of neck trauma and neck pain. Both studies were acquired using the ANG technique described in this paper. Coronal slices on Patient 1 (Fig. 7) demonstrate normal cervical spine activity. Normal includes the increased prominence of the C2 spinous process, seen in frames 32–34 (arrow). The spinous process of C2 is larger and points more directly posterior than the spinous processes of the other cervical vertebrae (2). It is also seen prominently in Patient 2 (Fig. 8), but here the increased activity was considered asymmetrically abnormal on the left side by the interpreting physician (frame 37, arrow). This abnormality was noticeable on sagittal slices, but the ability to see it on a second set of slices confirmed its presence in the posterior element of C2.

## CONCLUSION

We believe that useful SPECT imaging of the cervical spine can be accomplished by using neck angulation to straighten the



**FIGURE 8.** Coronal slices from Patient 2 reveal asymmetric (left-sided) activity at the level of C2 (arrow), suggesting stress-related injury correlating with the patient's history.

natural cervical lordotic curve and by reorienting perpendicularly to the now-straight longitudinal axis of the cervical spine.

## ACKNOWLEDGMENT

This paper was presented at the Society of Nuclear Medicine Annual Meeting in Orlando, Florida on June 12, 1994.

## REFERENCES

1. Yui N, Togawa T, Kinoshita F, et al. Usefulness of bone SPECT of the cervical spine: with special reference to separate visualization of the trachea and thyroid cartilage. *Ann Nucl Med* 1993;7:223-230.
2. Stalheim-Smith A, Fitch GK. *Understanding human anatomy and physiology*. St. Paul, MN: West Publishing Co.; 1993:180-181.
3. Gates GF. SPECT imaging of the lumbosacral spine and pelvis. *Clin Nucl Med* 1988;13:907-914.
4. Nicholson RL, Mangal-Lan B, Wilkins K. Reverse oblique reconstruction for SPECT of the spine. *Clin Nucl Med* 1991;16:478-481.