
Impact of Abbreviated Protocol on Hepatobiliary Scan Interpretation

Cynthia A. Campbell, Conrad E. Nagle, and Donald A. Meier

Department of Nuclear Medicine, William Beaumont Hospital—Troy, Troy, Michigan

A retrospective study of the biliary scans of 50 patients compared the original scan interpretations using 7 anterior images in the first hour to the interpretations using a new protocol with only 2 anterior images in the first hour. Two physicians independently reviewed the studies for each patient using the new protocol. The physicians were also shown all delayed images after 60 min. Interpretation was rendered, blind to the original interpretation and history. In 49/50 interpretations (98%) by at least one physician, the reviewer agreed with the original interpretations. In 1/50 scan descriptions (2%), the reviewer agreed with the initial description but the original interpretation was in error. For 5/50 studies (10%) reviewed by one physician, there was disagreement in the interpretation of delayed biliary-to-bowel transit. This pilot study suggests that reducing the number of images in the first hour does not significantly affect hepatobiliary scan interpretation. This protocol may be less burdensome for patients and allow more patients to be imaged by each technologist.

J Nucl Med Technol 1993; 21:206–210

Hepatobiliary imaging is a familiar and useful tool in the diagnosis of certain biliary tract abnormalities. It is important to image at 5 min postinjection in order to assess hepatic parenchymal function. A normal hepatobiliary image demonstrates visualization of the gallbladder, common bile duct, and intestinal tract by 60 min after injection.

The purpose of this study was to determine if limiting the number of images taken during a hepatobiliary study would alter the physician's interpretation. Our original protocol was for the patient to have nothing by mouth (NPO) for at least 4 hr. The patient was then injected intravenously with 5 mCi of technetium-99m (^{99m}Tc) disofenin, or mebrofenin, if the patient's bilirubin was elevated. Static images were acquired at 5, 10, 20, 30, 40, 50, and 60 min postinjection. The

first image was acquired for one million counts, and succeeding images were acquired for the same amount of time as the first image. Acquisition of images after 60 min was at the physician's discretion.

Figure 1A shows the results of a normal scan using the original protocol. Use of this protocol leads to a very thorough diagnostic evaluation, but it is often difficult for an ill patient to remain still under a gamma camera for that length of time. Also, use of this technique means that both the technologist and the gamma camera are unavailable for more than an hour.

Figure 1B demonstrates the new protocol using the same study as in Figure 1A. The patient was again NPO for at least 4 hr and injected intravenously with 5 mCi of ^{99m}Tc -disofenin or mebrofenin. All images during the first hour were eliminated except for the 5-min (1000k count) image and the 60-min image. The physician was still provided with all images taken after 60 min, such as delays and those taken after the administration of morphine or cholecystokinin. The technologist was free between the 5-min and 60-min images to perform other studies. Meanwhile, the patient could be made more comfortable in another room.

Figures 2–4 compare results of the old and new protocols on studies of acute cholecystitis, chronic cholecystitis, and delayed biliary-to-bowel transit.

MATERIALS AND METHODS

The 50 cases for this retrospective study were randomly chosen from studies performed during the summer and fall of 1991 at our 200-bed community hospital. All images except the 5-min and 60-min images were eliminated by covering the film with opaque paper. All images after 60 min were included for physician viewing. Each study was numbered, and for physician convenience, the gallbladder ejection fraction was written on the outside of the scan when available. Two physicians who had sometimes been the original interpreters were given a checklist that contained a summarized list of possible biliary scan interpretations, along with the

For reprints contact: Cynthia A. Campbell, CNMT, Dept. of Nuclear Medicine, William Beaumont Hospital—Troy, 44201 Dequindre, Troy, MI 48098.

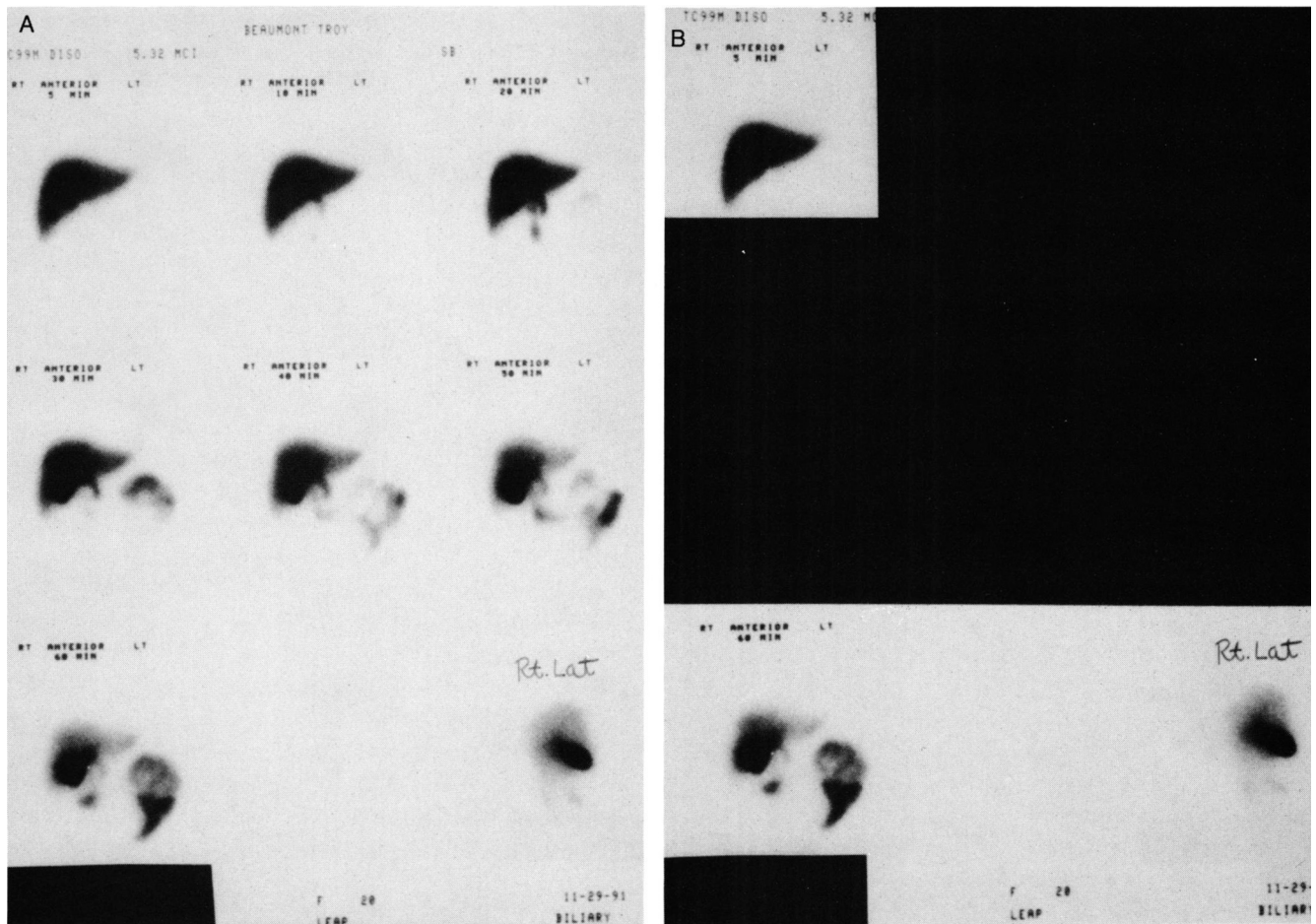


FIG. 1. Normal scan. (A) Original protocol of seven anterior images in first hr and right lateral image at 65 min. Liver, biliary tract, gallbladder, and intestine are all seen at 20 min. (B) New protocol using the same study as (A) with only a 5-min and 60-min anterior image and a 65-min right lateral image. Liver, biliary tract, gallbladder, and intestine are all seen at 60 min.

numbered scans (Table 1). The original physician interpretation was then compared to the interpretations made using the new protocol.

RESULTS

The results of this study are shown in Table 2. Physicians 1 and 2 both agreed with the original reports 100% of the time for acute cholecystitis, chronic cholecystitis—both when gallbladder visualization was delayed and when the gallbladder ejection fraction was reduced, and for common bile duct obstruction. Physician 2 also agreed with the original interpretation 100% of the time for normal scans and for those with delayed biliary-to-bowel transit, while Physician 1 was in such agreement 87% of the time when viewing a normal study but only 33% of the time for scans showing delayed biliary-to-bowel transit. One original report was found to be in error and this was reviewed as a quality assurance case.

DISCUSSION

Assessment of delayed biliary-to-bowel transit was one category where there was disagreement between physicians. This was not attributed to using the new protocol; rather, it

was a problem of selecting a criterion for determining delayed biliary-to-bowel transit. Also, the 66% disagreement for the delayed biliary-to-bowel transit category might be somewhat deceptive because of the low number of studies in that category. After participating in a quality assurance discussion to establish a criterion for delayed biliary-to-bowel transit, the two physicians concluded that the bowel is considered delayed if it has not visualized at 60 min, but is considered significantly delayed if it has not visualized at 75 min. If a patient is referred to us for a study because a biliary leak is suspected, we use the old protocol instead of the new protocol.

CONCLUSION

Hepatobiliary image interpretation for acute and chronic cholecystitis and normal patients is not significantly affected when using the new protocol of fewer images during the first hour. Since the patients are under the camera a shorter amount of time, their discomfort is reduced. Also, department productivity may increase since a technologist and gamma camera are now available for other studies.

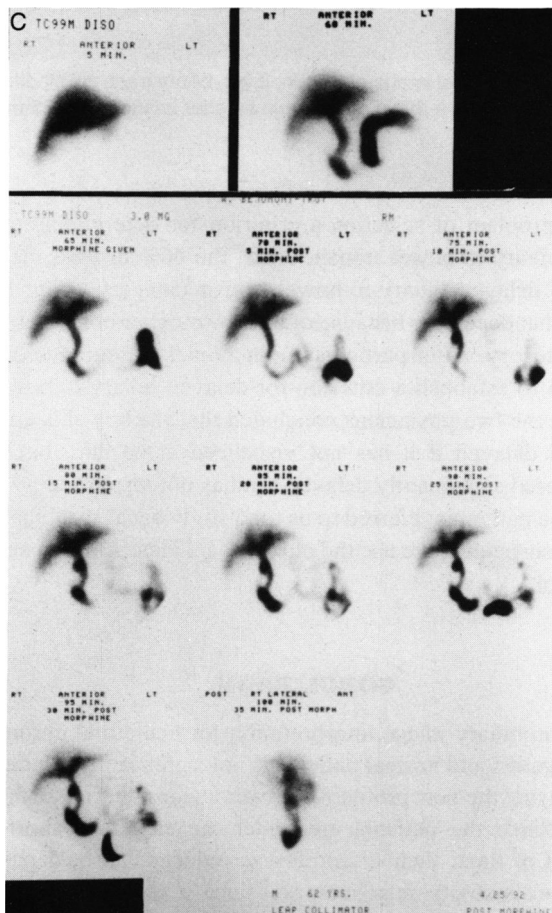
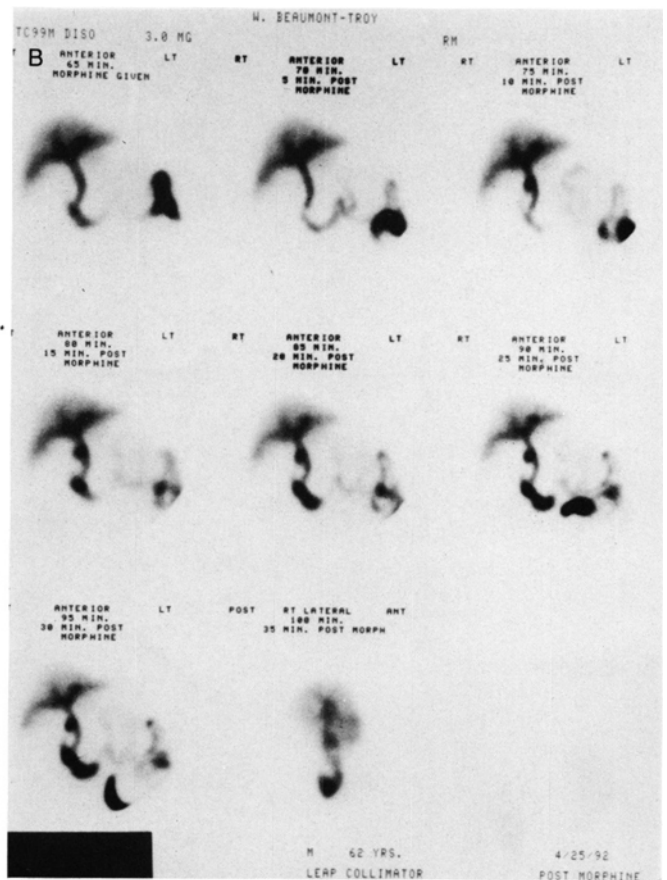
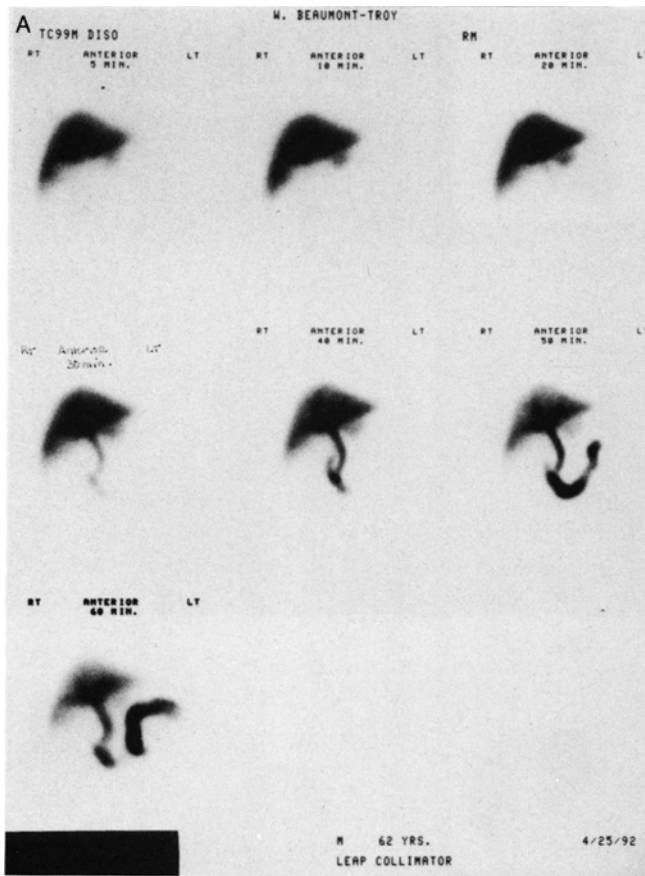


FIG. 2. Acute cholecystitis. (A) Original protocol of seven anterior images in first hour. Liver, biliary tract, and intestine are seen by 30 min. Gallbladder is not visualized at 60 min. (B) Images taken sequentially for 30 min after administration of morphine sulfate do not visualize gallbladder. This favors diagnosis of acute cholecystitis. (C) New protocol using same study as (A) and (B) with 5-min and 60-min anterior image and all images after administration of morphine sulfate. Liver, biliary tract, and intestine are seen at 60 min. Gallbladder is not visualized at 60 min or by 30 min after administration of morphine sulfate.

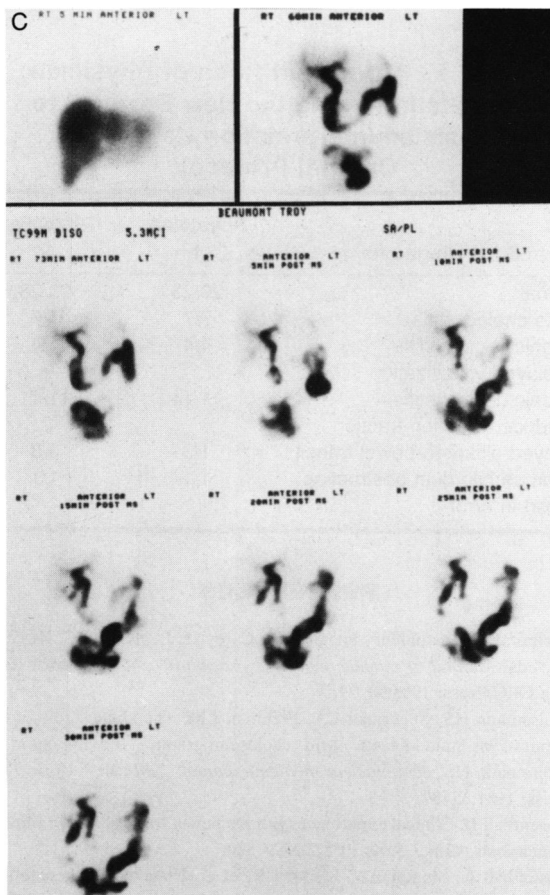
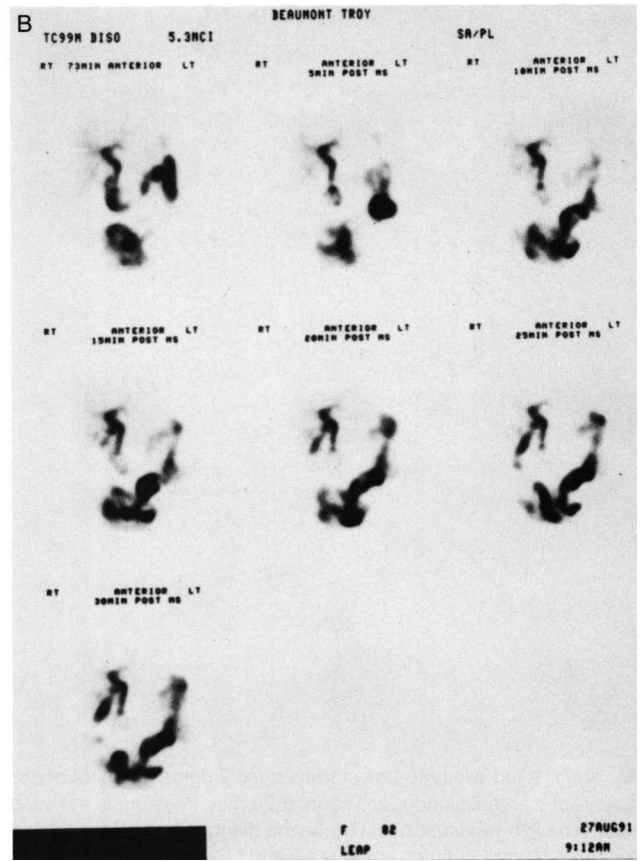
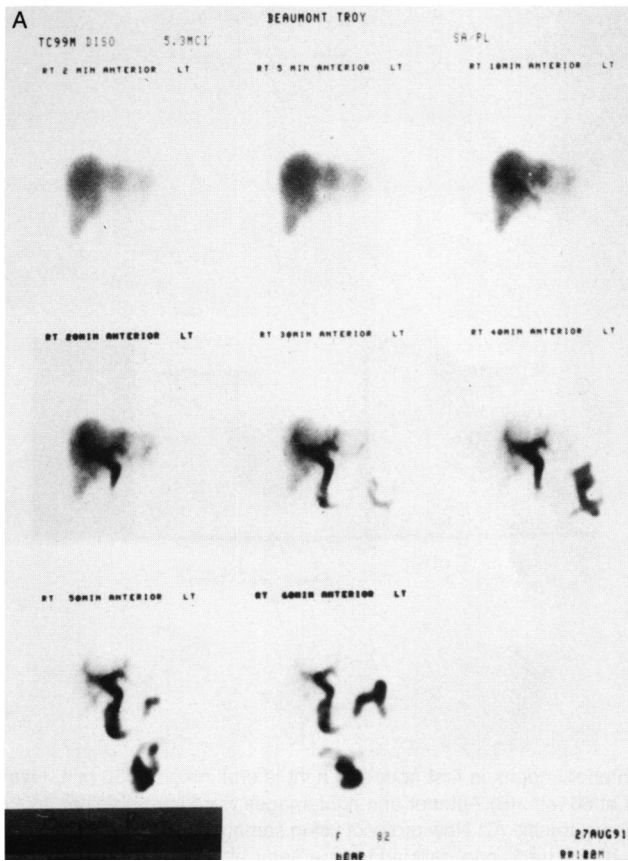


FIG. 3. Chronic cholecystitis. (A) Original protocol of seven anterior images in first hour and additional image at 2 min. Liver, biliary tract, gallbladder, and intestine are seen at 30 min. Gallbladder is not visualized at 60 min. (B) Images taken after administration of morphine sulfate show gallbladder at 15 min, better image at 20 min, and clearest image at 30 min. This favors diagnosis of chronic cholecystitis. (C) New protocol using the same study as (A) and (B) with 5-min and 60-min anterior image and all images after administration of morphine sulfate. Liver, biliary tract, and intestine are seen at 60 min. Gallbladder is not visualized at 60 min. Gallbladder is clearly seen at 20 min after administration of morphine sulfate.

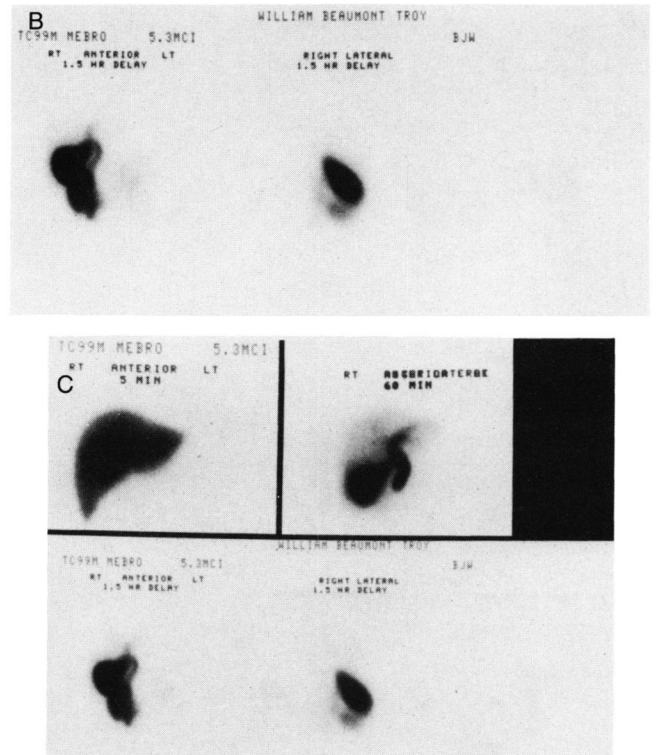
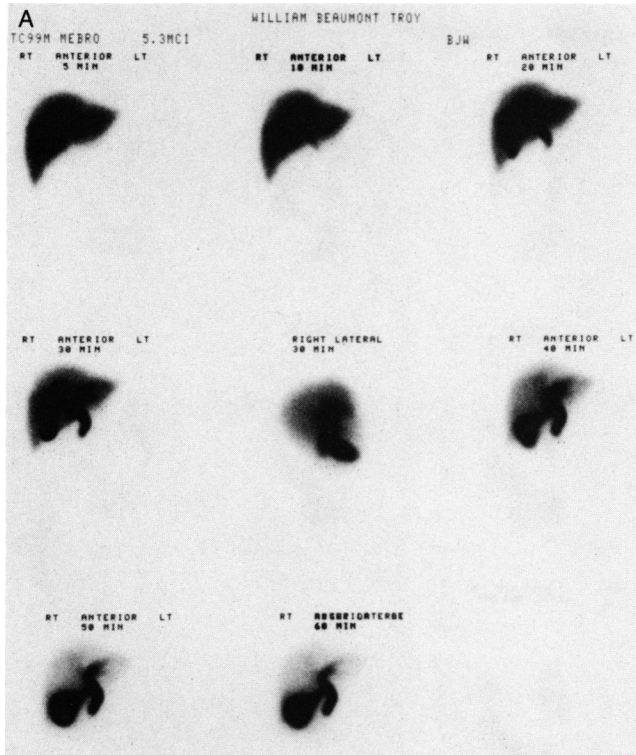


FIG. 4. Delayed biliary-to-bowel transit. (A) Original protocol of seven anterior images in first hour and right lateral image at 30 min. Liver, biliary tract, and gallbladder are seen at 20 min. Intestine is not visualized at 60 min. (B) Anterior and right images were later obtained at 1.5 hr. Intestine is now visualized. This favors diagnosis of delayed biliary-to-bowel transit. (C) New protocol using same study as (A) and (B) with 5-min and 60-min anterior image and the 1.5-hr delayed images. Liver, biliary tract, and gallbladder are seen at 60 min. Intestine is not visualized at 60 min. Intestine is seen on images taken at 1.5 hr.

TABLE 1. Physician Checklist for Interpretation of Scans

Diagnosis	Scan Number							
	1	2	3	4	5	6	7	8
Normal								
Normal except for enterogastric reflux								
Nonvisualized gallbladder compatible with acute cholecystitis								
Delayed visualized gallbladder compatible with chronic cholecystitis								
Reduced ejection fraction compatible with chronic cholecystitis								
Delayed biliary-to-bowel transit								
Common bile duct obstruction								
Other								

ACKNOWLEDGMENTS

The authors wish to thank the members of the Photo Production Department at William Beaumont Hospital in Royal Oak, Michigan for their invaluable help. We are grateful to Mr. Thomas Campbell for his technical assistance in preparing this manuscript.

TABLE 2. Agreement Ratio of Physician Interpretation Using the New Protocol to Physician Interpretation Using the Original Protocol

Scan Diagnosis	Physician 1	Physician 2
Normal	20/23	23/23
Acute cholecystitis	7/7	7/7
Chronic cholecystitis—delayed visualization	4/4	4/4
Chronic cholecystitis—reduced ejection fraction	11/11	11/11
Delayed biliary-to-bowel transit	1/3	3/3
Common bile duct obstruction	1/1	1/1
Report in error		

REFERENCES

- Freitas JE. Hepatobiliary imaging. In: Carey JE Jr., Kline RC, Keyes JW Jr., eds. *Manual of nuclear medicine procedures*. 4th ed. Boca Raton, FL: CRC Press; 1983:58-59.
- Weissmann HS, Sugarman LA, Freeman LM. The clinical role of technetium-99m iminodiacetic acid cholescintigraphy. In: Freeman LM, Weissmann HS, eds. *Nuclear medicine annual: 1981*. New York: Raven Press; 1981:35-89.
- Rosenthal L. Clinical experience with the newer hepatobiliary radiopharmaceuticals. *Can J Surg* 1978;21:297-300.
- Rosenthal L, Shaffer EA, Lisbona R, et al. Diagnosis of hepatobiliary disease by ^{99m}Tc HIDA cholescintigraphy. *Radiology* 1978;126:467-474.