

A Simple Technique for Evaluating Cerebral Blood Flow with Regions of Interest

Bonnie J. Baggenstoss and Mary E. Maxwell

St. Paul-Ramsey Hospital and Medical Center, St. Paul, Minnesota

A technique for evaluating the blood flow through the middle cerebral arteries is described. Our method uses a scintillation camera with videotape and strip-chart accessories and does not necessitate a computer. It produces strip-chart tracings that aid in the visual interpretations of cerebral bloodflow studies.

Dynamic cerebral bloodflow imaging has become a useful tool in the diagnosis of occlusive vascular disease (OVD). We undertook a study of 50 cases to determine a reliable method of presenting the data from cerebral bloodflow studies. Both visual and strip-chart analyses were used to evaluate differences in the perfusion of the middle cerebral arteries.

Method

The studies were performed on a Searle Pho/Gamma HP scintillation camera with a high-sensitivity collimator and data-store playback assembly. A Picker strip-chart recorder was modified for use with the Searle camera.

Each patient was placed in an anterior position in front of the camera for a cerebral bloodflow (CBF) study. A 15-mCi bolus of ^{99m}Tc -pertechnetate was injected intravenously with the tourniquet on. The tourniquet was then released, and the dynamic study recorded on videotape for 60 sec. After the initial activity appeared on the persistence scope, simultaneous 70-mm scintiphotos were taken every 2 sec for 20 sec.

The flow study was then played back from the videotape. A plastic template was placed on the persistence scope, and rectangular-shaped areas of approximately equal size were drawn. Each area included middle cerebral artery distribution while avoiding sagittal sinus or pharyngeal activity. The

medial margins of the rectangular areas were approximately equidistant from the midline anterior cerebral artery.

Regions of interest were then displayed on the scope and were superimposed with the hand-drawn areas (Fig. 1). To insure that the areas in each region were equal, we removed the collimator and centered a 100–300- μCi ^{99m}Tc -pertechnetate source 4 ft beneath the camera head. Counts from each region were compared, allowing no more than a 2% variance (i.e., if Area 1=10K, then Area 2=10K \pm 200). If the variance was more than 2%, then the size of Area 2 was altered until it was within the limit. The strip-chart recorder was calibrated, the chart speed adjusted to 6 in./min, and a time constant of 0.3 sec selected. The study was played back from the videotape and recorded onto the strip chart. The two curves were then superimposed on one tracing.

Our initial criteria for interpreting the tracings were influenced by the work of O'Reilly, et al (1), who found that by using a computer analysis of dynamic cerebral blood flow "the only reproducible parameter specifically related to cerebral vascular disease was the comparison of the slopes of the ascending curve." Our experience has shown that the time of appearance of the ascending slope of the curve is also significant. Thus tracings were analyzed by using both the slope *and* time of occurrence of the ascending portion of the curves and were then classified into one of three categories:

1. Equal flow bilaterally: The ascending portions

For reprints contact: Bonnie J. Baggenstoss, Div. of Nuclear Medicine, St. Paul-Ramsey Hospital and Medical Center, St. Paul, Minn. 55101.

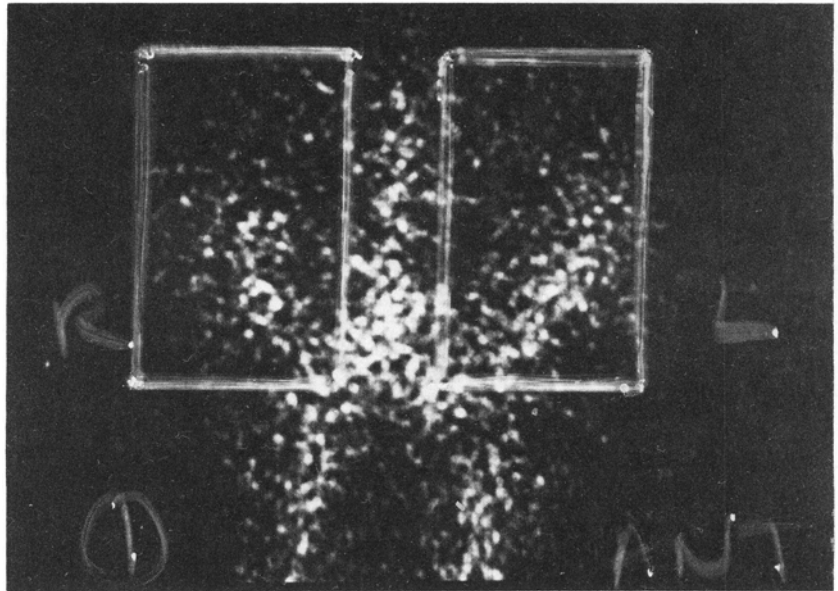


FIG. 1. Rectangles depict regions of interest as they are marked on template overlying persistence scope.

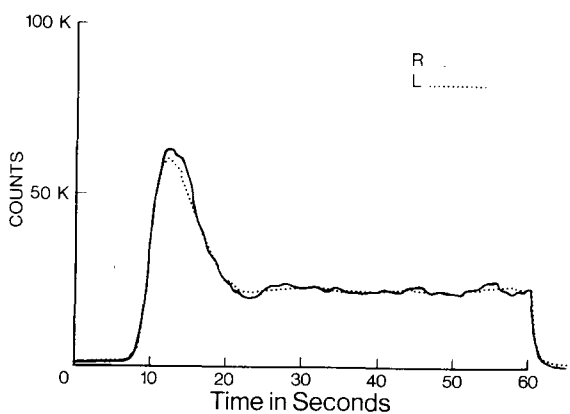


FIG. 2. Normal tracing shows ascending lines superimpose exactly.

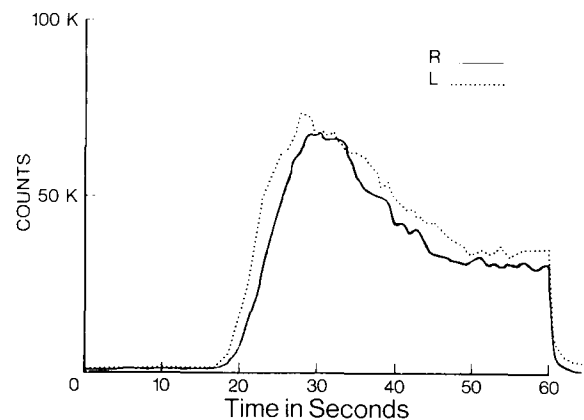


FIG. 3. Abnormal tracing indicative of decreased perfusion in right middle cerebral artery. Note lag and decreased slope of right ascending line.

of the curves were superimposed exactly and had the same slopes (Fig. 2).

2. Abnormal flow: The ascending curve of one side was either delayed or had a less steep slope than the other curve or both (most common). We assumed that the side with the least slope or latest appearance of the ascending curve would be the side with decreased flow (Fig. 3).
3. Questionable flow: Curves that crossed or were similar, but not identical (Fig. 4).

Interpretations of the 70-mm scintiphotos were made by four radiologists who had varying experience with CBF studies. The radiologists were numbered according to the degree of experience—the most qualified called Radiologist I, the next

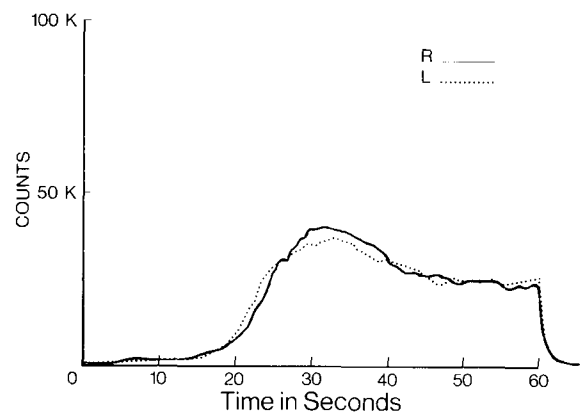


FIG. 4. Questionable tracing shows crossed ascending lines.

Table 1. Radiologists' Experience with CBF Studies

	Frequency of reading CBF studies	Board certification in nuclear medicine
Radiologist I	Routinely	Yes
Radiologist II	Occasionally	Yes
Radiologist III	Rarely	No
Radiologist IV	Rarely	No

Table 2. Reliability of Interpretation in 32 Cases of Occlusive Vascular Disease

Method	Predicted No. positives	Percent detection accuracy
Strip chart	25	78
Radiologist I	24	75
Radiologist II	11	34
Radiologist III	10	31
Radiologist IV	10	31

Table 3. True Positives and False Positives

Method	No. positive interpretations	Confirmed positive for OVD	True positive (%)	False positive (%)
Strip chart	34	27	80	20
Radiologist I	30	24	80	20
Radiologist II	20	11	55	45
Radiologist III	14	9	64	36
Radiologist IV	16	10	62	38

Table 4. True Negatives and False Negatives

Method	No. normal interpretations	Confirmed positive for OVD	True negatives (%)	False negatives (%)
Strip chart	16	5	69	31
Radiologist I	20	8	60	40
Radiologist II	30	21	30	70
Radiologist III	36	23	36	64
Radiologist IV	33	22	33	67

Radiologist II, etc. (Table 1). Readings were made in each of the studies without knowledge of the patient's history.

Each patient's chart was then reviewed to obtain angiographic, x-ray, and EEG findings, and the final clinical diagnosis. Infrequently, a postmortem diagnosis was obtained.

Results

Sixty-four percent of our studies (32 of 50) had a final diagnosis of occlusive vascular disease. We felt

that this high percentage occurred for two reasons: (A) the neurology patient population in our hospital had a high incidence of OVD and (B) CBF studies were not done routinely but were obtained only when clinically indicated.

The breakdown of these 32 cases of OVD detected by the strip-chart method and the interpretations by the four radiologists are included in Table 2.

The positive strip-chart and physician interpretations were correlated with the final clinical diagnoses to determine which positive interpretations were representative of OVD (Table 3).

Negative strip-chart and physician interpretations were correlated with final clinical diagnoses to determine which negative interpretations corresponded to final diagnosis negative for OVD (Table 4).

Discussion

Our strip-chart technique correlates well with clinically proven OVD as shown by a 78% detection accuracy. This method slightly surpasses the 75% accuracy of the experienced nuclear radiologist. The radiologists unfamiliar with CBF studies had a much lower percentage of detection in their interpretations.

Most of the patients in this series had acute or subacute OVD. The 78% detection by the strip-chart method corresponds favorably with previous results as published by Fish, et al (2).

Normally, decreased perfusion is found on the side of the vascular accident. It is interesting that in our study 5 of the 25 positive strip-chart tracings and 6 of the 24 positive studies called by the experienced nuclear radiologist showed increased perfusion in the middle cerebral artery on the side of the vascular accident. Moses, et al (3) reported similar increased activity on the side of OVD in 2 of 17 patients.

The false-positive interpretations were determined strictly by correlation with occlusive vascular disease. However, abnormal CBF studies may also be due to numerous other pathologic conditions such as arteriovenous malformations, tumors, and postictal states (4-6). Therefore, some of the interpretations called false positive for OVD actually represent other real pathology.

The false-negative interpretations are primarily due to equipment and technical limitations. Low resolution CBF studies poorly demonstrate OVD involving posterior fossa, brain stem, and anterior cerebral artery vasculature. Our technique is designed only to evaluate *major* discrepancies between middle cerebral artery flow. Resolution also

limits detection involving very small vessels. Often small occluded vessels cannot be adequately detected with cerebral angiography, and occasionally larger vessel occlusions are not demonstrated because the clot may have lysed by the time the study is performed.

The data presented in this paper demonstrate that the slope and the time of appearance of the ascending portion of the tracing correlate with middle cerebral artery flow. The ascending curves of normal tracings superimpose exactly, whereas decreased slope and/or delayed occurrence of the ascending curve are indications of decreased perfusion in that particular middle cerebral artery. Our study does not differentiate whether decreased slope or delay of the ascending portion of the curves is more significant in determining the side of decreased flow.

Summary

The technique presented for strip-chart recording of middle cerebral artery flow is simple and easily reproduced by a nuclear medicine technologist. It does require a data-store videotape system and a strip-chart recorder. Thus the strip-chart recording provides not only a clear method of presenting CBF data to the clinician but also gives

a graphic representation to an otherwise subjective interpretation.

Acknowledgment

The authors would like to express their appreciation to Robert R. McClelland for his support and assistance.

References

1. O'Reilly RJ, Cooper REM, Ronai PM: Automatic computer analysis of digital dynamic radionuclide studies of the cerebral circulation. *J Nucl Med* 13: 658-666, 1972
2. Fish MB, Barnes B, Pollycove M: Cranial scintiphographic blood flow defects in arteriographically proven cerebrovascular disease. *J Nucl Med* 14: 558-563, 1973
3. Moses DC, Natarajan TK, Previosi TJ, et al: Quantitative cerebral circulation studies with sodium pertechnetate. *J Nucl Med* 14: 142-147, 1973
4. Holmquest DL, Launey WS: Abnormal scintiangiographic findings associated with seizure activity. *Radiology* 111: 147-150, 1974
5. Sheldon JJ, Smoak WM, Gargano FP, et al: Dynamic scintigraphy in intracranial meningiomas. *Radiology* 109: 109-115, 1973
6. Schall GL, Quinn JL: Diagnosis of central nervous system disease. In *Nuclear Medicine*, 2nd ed, Blahd WH, ed, New York, McGraw-Hill, 1971, p 257