

Technetium-99m DTPA Uptake in an Extra-Skeletal Myxoid Chondrosarcoma: Case Report

Edwin J. Fortenbery and Eric H. Norby

Fitzsimons Army Medical Center, Aurora, Colorado; Walter Reed Army Medical Center, Washington, D.C.; and Uniformed Services University of the Health Sciences, Bethesda, Maryland

Extra-skeletal myxoid chondrosarcoma (ESMC) is quite rare and was first described by Stout in 1953 (1,2). We describe a case of ESMC in which an abnormal accumulation of technetium-99m (^{99m}Tc) DTPA was detected in the area of the ESMC prior to eventual diagnosis. Recognition of ^{99m}Tc -DTPA uptake in ESMC may be of value in early diagnosis, and ^{99m}Tc -DTPA activity outside the urogenital tract can be an early sign of a hypervascular tumor and should not be dismissed.

CASE REPORT

A 55-yr-old man initially had a technetium-99m (^{99m}Tc) DTPA renal scan as part of an assessment for hypertension. This study demonstrated an abnormal soft tissue accumulation of tracer in the region of the left buttock.

During a 2-wk period, a plain X-ray, CT scan, MRI scan, bone scan, gallium scan, and arteriogram were obtained revealing a soft tissue mass in the left gluteal region extending into the left thigh (Figs. 1 and 2). A three-phase ^{99m}Tc -MDP bone scan showed a hypervascular tumor with increased soft tissue activity in the left buttock extending to the iliac crest (Fig. 3), but did not appear to involve bone.

The earlier renal scan was reviewed (Fig. 4), and the area of increased soft tissue activity in the left buttock corresponded to the abnormalities seen in the other studies.

On a frozen section, the diagnosis of chondrosarcoma was made and the patient subsequently underwent internal hemipelvectomy. The final pathologic diagnosis was myxoid chondrosarcoma, completely excised.

DISCUSSION

Chondrosarcomas arising in soft tissues are distinctly uncommon. A recent review of the literature by Louvet et al. (2) disclosed only 34 cases localized within muscle. Of those, the mean age of onset was 44 yr, and the sex ratio was nearly

equal. In none of these cases was uptake by ^{99m}Tc -DTPA described.

Other types of pathology associated with localization of ^{99m}Tc -DTPA include breast cancer (3); inflammatory bowel disease (4); a variety of soft tissue tumors, including uterine leiomyoma (5), leiomyosarcoma (6), abdominal soft tissue sarcoma (7), and hypervascular tumors (renal cell carcinoma, plasmacytoma, and angiomyolipoma) (8). The presumed mechanism of ^{99m}Tc -DTPA activity in most of these examples was increased permeability in neoplastic vessels.

The mechanism of DTPA uptake in ESMC is likely non-specific and may be explained by the blood supply and drainage characteristics typical of many tumors. These include increased permeability of neoplastic vessels and decreased or absent lymphatic drainage of the interstitial DTPA (5,7). Leiomyomas have a profusion of arterioles with few draining

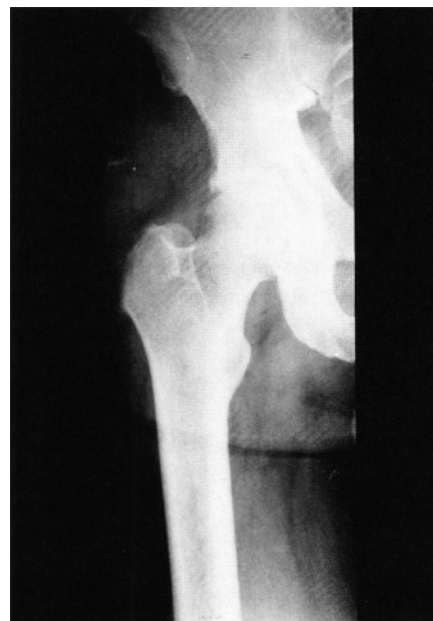

FIG. 1. Plain film radiograph revealing a soft tissue mass with microcalcification.

For reprints contact: Edwin J. Fortenbery, MD, Nuclear Medicine Service, Fitzsimons Army Medical Center, Aurora, CO 80045-5001.

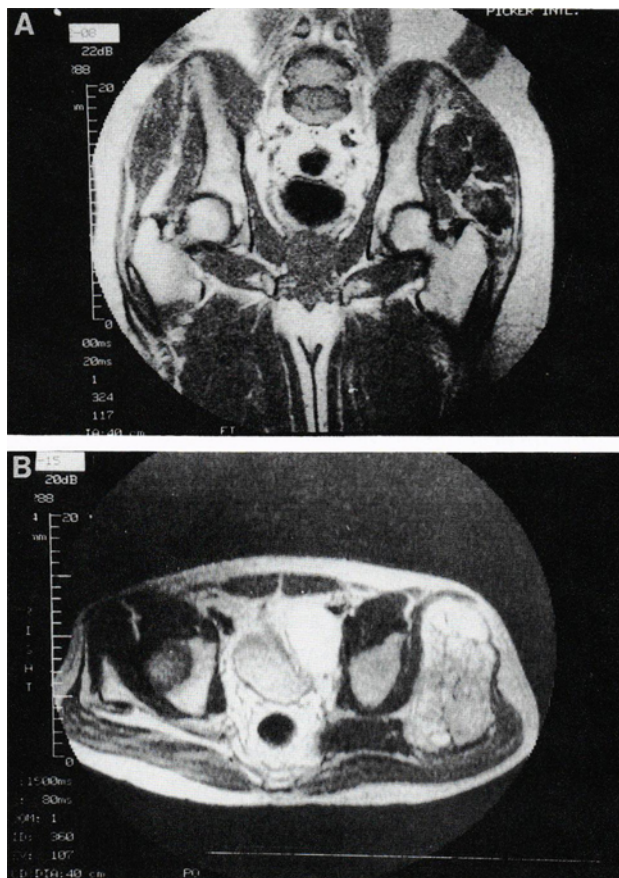


FIG. 2. (A) A coronal cut from the MRI scan shows a multilobulated mass in the gluteal region, extending close to both iliac bone and proximal femur. (B) An axial cut from a T1 weighted MRI scan also shows the extensive left gluteal mass.

veins (6). These characteristics could result in the scintigraphic appearance we describe. In neoplastic tissue, DTPA could diffuse into the tissues but would be cleared very slowly. As the background activity decreased, the lesion would appear as an area of increased radioactivity. Although cellular uptake of DTPA by this tumor cannot be excluded, it cannot be supported by known pharmacokinetics. This mechanism of passive diffusion is most likely responsible for the increased activity in our case of ESMC. An angiogram confirmed the hypervascular nature of the tumor.

This case report emphasizes the need for careful follow-up of unexpected extrarenal ^{99m}Tc-DTPA activity. Incidental soft tissue activity found during ^{99m}Tc-DTPA scanning should raise the suspicion of a mesenchymal tumor, and ESMC should be added to the gamut of extrarenal ^{99m}Tc-DTPA activity.

DISCLAIMER

The opinions and assertions contained herein are the private views of the authors and are not to be construed as reflecting the views of the Army or the Department of Defense.

REFERENCES

1. Stout AP, Verner EW. Chondrosarcoma of extraskelatal soft tissues. *Cancer* 1953;6:581-590.
2. Louvet C, deGramont A, Krulik M, et al. Extraskelatal mesenchymal chondrosarcoma: case report and review of the literature. *Clin Oncol* 1985;3:858-863.
3. Cuschieri A, Hutchinson F, Neill GDS, Wisbey ML, Wood RAB, Preece

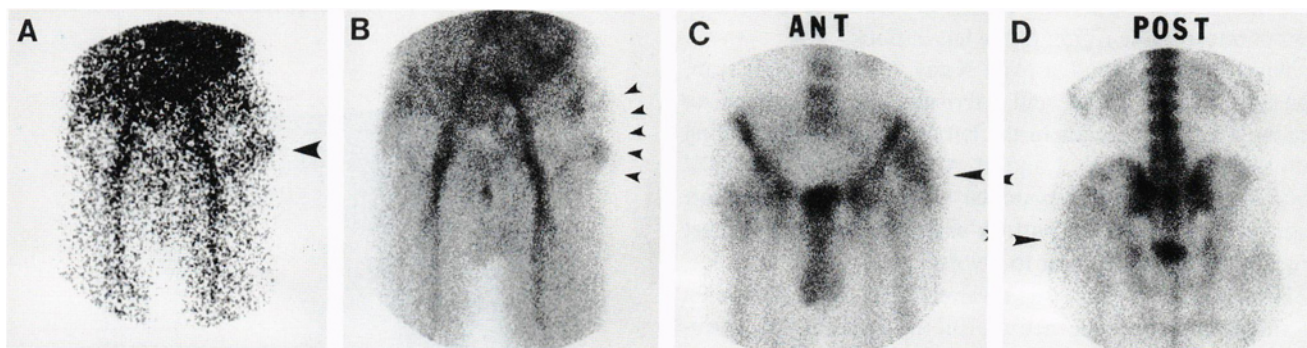


FIG. 3. (A, B) Anterior Tc-99m MDP flow and blood pool images show increased activity in the region of the tumor. (C, D) Bone phase images demonstrate increased soft tissue activity in left gluteal region without definite boney involvement.

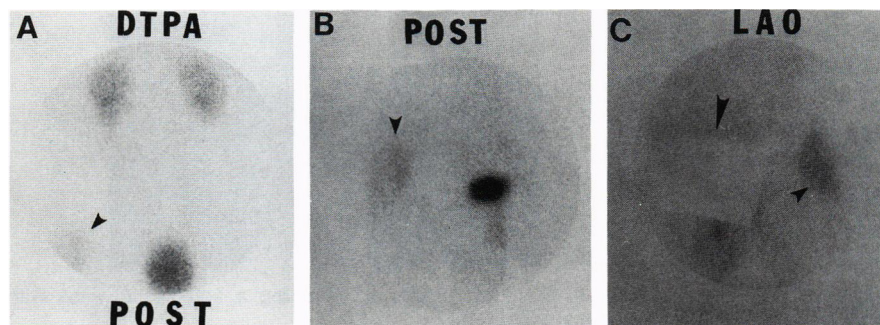


FIG. 4. (A, B) Two posterior Tc-99m DTPA images show increased activity on the left at the level of the bladder. (C) An LAO view from the same study, with the bladder shielded, shows a large area of increased activity. These posterior images correlate with the posterior bone images.

- P. Clark J. Scintiscanning of the breast with Tc-99m-diethylene triamine penta-acetic acid—a prospective blind evaluation. *Br J Surg* 1981;68:147–149.
4. Kadir S, Strauss HW. Evaluation of inflammatory bowel disease with 99mTc-DTPA. *Radiology* 1979;130:443–446.
 5. Lunia S, Lunia C, Philip P, Tiu A, Chodos RB. Accumulation of Tc-99m-DTPA in uterine myoma. *Clin Nucl Med* 1980;5:272–273.
 6. Slavin JD, Mack JM, Spencer RP. Delayed accumulation (Flip Flop) of Tc-99m in a leiomyosarcoma. *Clin Nucl Med* 1988;13:654–656.
 7. Tyler JL, Powers TA. Tc-99m DTPA uptake in soft tissue sarcoma. *Clin Nucl Med* 1982;7:357–358.
 8. Bihl H, Sautter-Bihl ML, Riedasch G. Extrarenal abnormalities in Tc-99m DTPA renal perfusion studies due to hypervascularized tumors. *Clin Nucl Med* 1988;13:590–593.