

Talc Granulomatosis: Case Report

Edward T. Mezc, Margaret M. LaManna, Naipaul Rambaran, John T. Nicewicz, and David M. F. Murphy

Department of Pulmonary Medicine and Department of Nuclear Medicine, Deborah Heart and Lung Center, Browns Mills, New Jersey

The authors present a case of biopsy proven talc granulomatosis in a user who habitually injected cocaine over a period of eight years with symptomatic and variable improvement occurring during corticosteroid therapy.

CASE REPORT

A 27-yr-old white male intravenous cocaine abuser was admitted in October of 1986 with acute myocardial infarction complicated by ventricular aneurysm, cardiopulmonary arrest, and staphylococcal pneumonia. The patient presented two months post-myocardial infarction with dyspnea on exertion, productive blood-tinged sputum, and pleuritic chest pain. The patient has a previous history of asthma and was HIV negative. A nuclear venogram and ventilation perfusion lung scan demonstrated no evidence of deep venous thrombosis. There were multiple bilateral segmental and subsegmental V-Q matched defects in keeping with a low probability for pulmonary embolus (Fig. 1). A pulmonary angiogram showed evidence of diminished microcirculation in the right mid-lung and right lower and left lower lung zones. There were no obvious vascular cut-offs compatible with clot. It was felt these were changes secondary to either micropulmonary emboli or talcosis in spite of the absence of chest radiographic findings. The patient was scheduled to return for open lung biopsy but developed a three-day episode of hemoptysis accompanied by low grade fever, pleuritic chest pain, and increasing dyspnea. The subsequent ventilation perfusion lung scan was in keeping with multiple V-Q matched and mismatched defects (Fig. 2). In view of the prior pulmonary angiogram, it was felt that the patient had micropulmonary emboli and anticoagulation therapy was instituted. The patient was discharged on Cardizem, Digoxin, Procan, Lasix, Theodur, Prednisone, and Coumadin. The patient was admitted one week later for hemoptysis. A ventilation perfusion study demonstrated no significant interval change. It was felt

that this was compatible with micropulmonary emboli or talcosis. While on Prednisone, a gallium study demonstrated no abnormal pulmonary activity. Later, after deterioration of his oxygenation, a repeat lung scan demonstrated no significant interval change. The Prednisone was increased. It was felt that his hemoptysis was secondary to bronchitis. Antibiotic therapy was instituted. The patient developed ventricular ectopy requiring adjustment of his anti-arrhythmic therapy. A lung biopsy was performed on 4/24/87. The section of tissue submitted as left lower lobe demonstrated pulmonary parenchyma with adherent pleura. The pleura was slightly congested but otherwise unremarkable. There were mild emphysematous changes associated with diffuse congestion. The interalveolar septae were not widened. There was an infiltrate of polys and round cells. Noted were focal nodular thickenings of the interalveolar septae. These thickenings contained birefringent material (Fig. 3A-D) together with poorly formed granulomas and multi-nucleated giant cells. The birefringent material was consistent with talc.

DISCUSSION

Pulmonary disease due to exposure to talc (magnesium silicate) is seen in three clinical situations: (1) chronic exposure to atmospheric talc generated by mining and milling of talc; (2) accidental massive inhalation of talc and talcum powder by infants or children; and (3) intravenous injection of medication intended for oral use only. Among the commonly implicated medications are Ritalin (methylphenidate), amphetamine, Tripeleminamine (pyribenzamine), Dilaudid, propoxyphene, and cocaine (1,2).

Talc is an absorbent substance which is chemically inert. When ground into fine particles it is very soft and makes an excellent non-oily lubricant. It is used in the manufacturer of many different types of drug tablets. Any particulate matter that gains entrance to the venous side of the circulation may lodge in the lungs. Drug addicts who accidentally inject talc particles as a filler with the active drug develop foci of foreign-body granulomas within the vasculature of the lungs. The foreign-body giant cells contain doubly refractile particles

For reprints contact: Margaret M. LaManna, MD, Director of Nuclear Medicine, Deborah Heart and Lung Center, Browns Mills, New Jersey 08015.

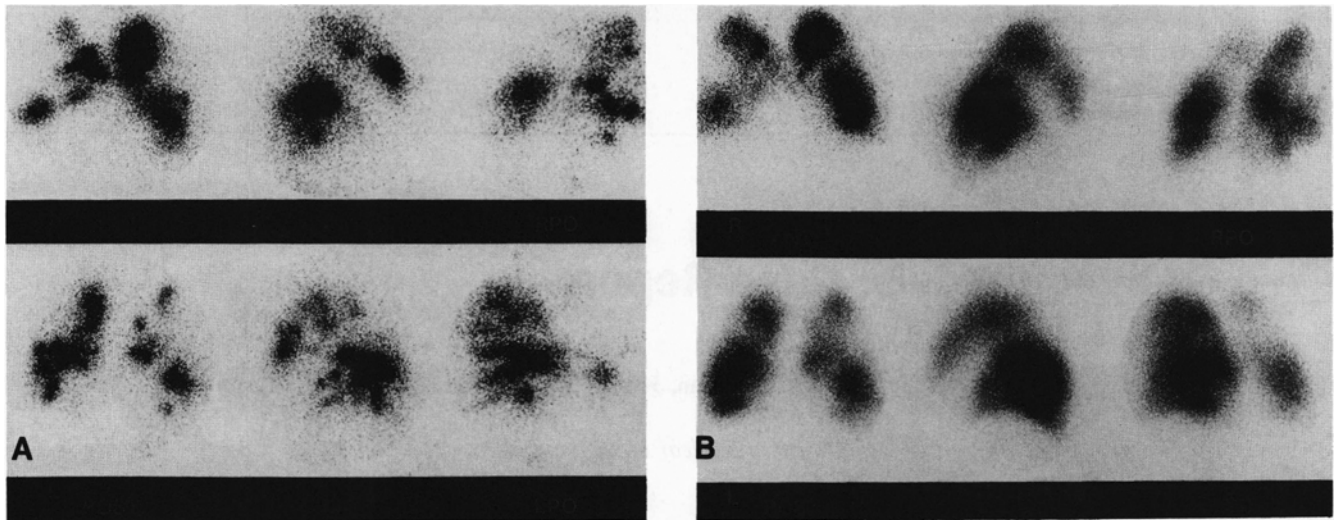


FIG. 1. (A) Following the inhalation of 3 mCi of ^{99m}Tc-DPTA aerosol, images of the lungs obtained in multiple projections demonstrate multiple bilateral segmental and subsegmental ventilation defects. There is hyper-deposition of aerosol particles centrally in keeping with significant obstructive physiology. (B) Following i.v. injection of 3 mCi of ^{99m}Tc-MAA, views of the lungs obtained in the anterior, posterior oblique, and lateral projections demonstrate segmental and subsegmental perfusion defects matching those of the ventilatory study.

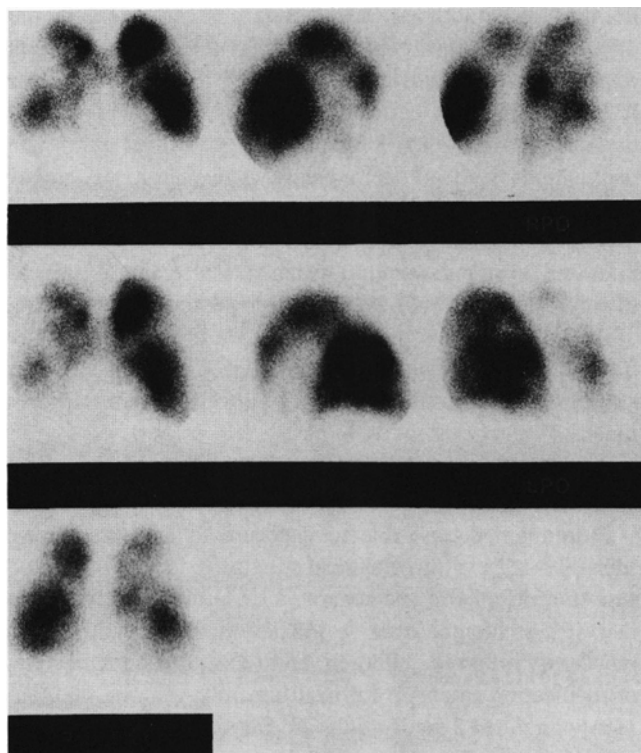

FIG. 2. Technetium-99m-MAA images obtained after an episode of hemoptysis demonstrate multiple segmental and subsegmental perfusion defects, which were both matched and mismatched with the ventilation study.

which may measure up to 40 microns in length. The fibrosis may be intense. The granulomas are all within or adjacent to vessels since the route of entry is by intravenous injection. For this same reason the particles are apt to be larger than those inhaled. In the case of industrial talc pneumoconiosis, the particles are unlikely to be larger than 4–5 microns in

length. It has been reported that inhalational and injection pulmonary talcosis may possibly be differentiated on the basis of particle size with the average particle size in the injection variety being on the order of four times that seen in patients with inhalational talcosis (3,4).

In addicts in whom the talc was intravenously injected, a history of drug use coupled with the presence of progressive dyspnea and cough are the diagnostic criteria. Patients may be asymptomatic or have a variety of symptoms including dyspnea, usually progressive, dry or mildly productive cough, fatigability, anorexia, and occasional hemoptysis (1,2,5,6). Physical findings include evidence of the intravenous administration of drugs and variable pulmonary auscultatory findings. Clinical evaluation may reveal evidence of right heart strain or cor pulmonale. There may be evidence of talc emboli on fundoscopic examination.

The chest x-ray may be entirely normal. When abnormal, the usual picture is that of a nodular pattern (2). Roentgenographic findings include a diffuse haziness caused by fine, punctiform densities which can proceed to reticulonodular densities, conglomerate fibrosis (at the base rather than upper lungs), or diffuse pulmonary fibrosis. Areas of overinflation may be present. Of special interest are the pleural plaques seen on diaphragmatic surfaces: as with asbestosis, these may be calcified. Results of gallium imaging in intravenous pulmonary talcosis have been reported. Findings have been shown to consist of nonspecific, diffuse, and bilateral increased uptake.

Search of the literature reveals little on the findings of ventilation perfusion imaging. The perfusion scan findings may consist of multiple diffuse bilateral parenchymal and intraparenchymal defects, both matched and mismatched when compared with the ventilatory scans. These findings are similar to those expected with other diagnostic possibilities

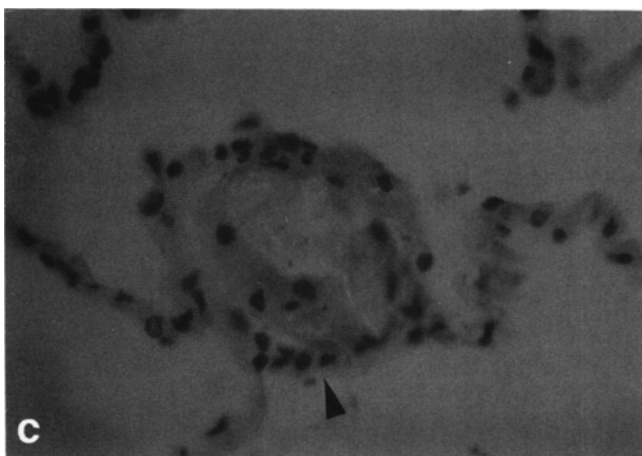
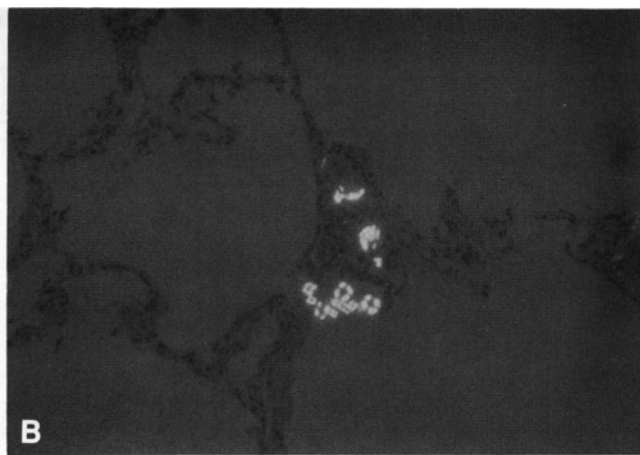
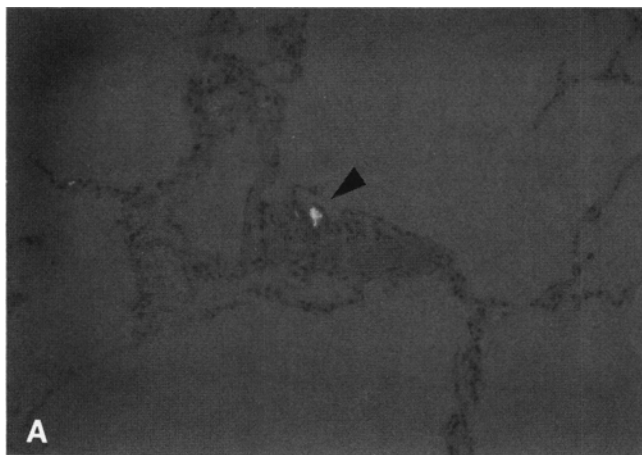


FIG. 3. Left lower lobe biopsy (A and B) demonstrating focal nodular thickening of the interalveolar septae containing birefringent material consistent with talc (arrow) and (C) poorly formed granulomas (arrow) with multi-nucleated giant cells.

mentioned such as multiple pulmonary emboli and vasculitis. This is not surprising when one considers that pathologically, in intravenous talc granulomatosis, foreign-body granuloma formation has been shown to be intra- and peri-vascular in location. The anatomic lesions in the parenchyma and pulmonary microcirculation resemble those of primary pulmonary hypertension plus inflammatory reactions to the foreign material. In talc pneumoconiosis of drug addicts, the major defects in pulmonary function testing are typical restrictive disease with small lung volumes and impaired gas exchange. Pulmonary function testings, as reported by Pare, Fraser, et al., may reveal restrictive or obstructive physiology. A combination of both restrictive and obstructive abnormalities may be seen. With resultant hypoxemia, pulmonary hypertension and right sided heart failure are functional end stages. The most common clinical complication is pulmonary hypertension. The disease may be progressive despite the cessation of intravenous medication injection (6, 7). If pulmonary impairment is progressive, steroids may be tried but are unlikely to help. Treatment of cardiorespiratory failure is similar to that described for other pneumoconioses and for cardiorespiratory insufficiency in general. The only effective treatment is prevention (8-15).

REFERENCES

1. Arnett EN, Battle WE, Russo JV, Roberts WC. Intravenous injection of talc-containing drugs intended for oral use. A cause of pulmonary granulo-

matosis and pulmonary hypertension. *Am J Med* 1976;60:711-718.

2. Pare JAP, Fraser RG, Hogg JC, Howlett JG, Murphy SB. Pulmonary mainline granulomatosis: Talcosis of intravenous methadone abuse. *Medicine* 1979;58:229-239.

3. Scully RE, Mark EJ, McNeely BU. Case records of the Massachusetts General Hospital (case 35-1982). *N Engl J Med* 1982;307:605-614.

4. Abramam JL, Brambilla, C. Particle size for differentiation between inhalation and injection pulmonary talcosis. *Environ Res* 1980;21:94-96.

5. Farber HW, Mathers JAL Jr, Glauser FL. Gallium scans and serum angiotension converting enzyme levels in talc granulomatosis and lymphocytic interstitial pneumonitis. *South Med J* 1980;73:1663-1667.

6. Waller BF, Brownlee WJ, Roberts WC. Structure-Function correlations in cardiovascular and pulmonary diseases (CPC). Self-Induced Pulmonary Granulomatosis. A consequence of intravenous injection of drugs intended for oral use. *Chest* 1980;78:90-94.

7. Brown DG, Aguirre A, Weaver A. Gallium-67 scanning in talc-induced pulmonary granulomatosis. *Chest* 1980;77:561-565.

8. Accidental inhalation of talcum powder (editorial). *Br Med J* 1969;4:5-6.

9. Hopkins GB, Taylor DG. Pulmonary talc granulomatosis: A complication of drug abuse. *Am Rev Resp Dis* 1970;101:101-104.

10. Kleinfeld M, Giel CP, Majeranowski JF, Messite J. Talc pneumoconiosis: A report of six-patients with postmortem findings. *Arch Environ Health* 1963;7:101-115.

11. Kleinfeld M, Messite J, Kooyman O, Shapiro J. Pulmonary ventilatory function in talcosis of lungs. *Dis Chest* 1964;46:592-598.

12. Kleinfeld M, Messite J, Kooyman O, Zaki MH. Mortality among talc miners and millers in New York State. *Arch Environ Health* 1967;14:663-667.

13. Dalen JE, Alpert JS. Natural history of pulmonary embolism. *Prog Cardiovasc Dis* 1975;17:259-270.

14. Robertson CH Jr, Reynolds RC, Wilson JE III. Pulmonary hypertension and foreign body granulomas in intravenous drug abusers documented by cardiac catheterization and lung biopsy. *Am J Med* 1976;61:657-664.