

Evaluation of Pulmonary Embolism—Role of Lung Scanning

Pulmonary embolism (PE) is a major cause of morbidity and mortality in the United States. Approximately 200,000 people die each year either directly or indirectly from PE (1). If PE is not treated, the mortality rate is estimated to be 30%, whereas this rate is 8% in patients that are treated with anticoagulant (1). If a patient is falsely diagnosed of having PE, he is needlessly subjected to the risk of anticoagulation. The complication rate of anticoagulation therapy is estimated to be ~ 15% (2), and heparin is considered to be a major cause of drug related deaths in hospitalized patients (3). Thus, it is important that the diagnosis of PE be made accurately.

The clinical history, physical exam, and laboratory evaluation have limited ability to accurately diagnose or exclude PE. Therefore, medical imaging is the major means by which this diagnosis must be made or excluded. This article will examine the various methods by which PE may be diagnosed and will discuss the proper methods of their interpretation.

CLINICAL EVALUATION

Pulmonary embolism presents with a variety of symptoms and signs. Unfortunately, the findings commonly associated with PE are nonspecific and present in many cardiorespiratory diseases, which are the diseases the clinician must differentiate from PE. The symptoms commonly found in PE include dyspnea and pleuritic chest pain, which may be present in three-fourths of patients presenting with PE (4). Cough occurs in approximately one-half of the patients, and hemoptysis occurs in approximately one-third of the patients with PE (4). Patients with PE often present with predisposing factors such as prolonged immobilization, congestive heart failure, or postoperative state (4).

The sign most commonly associated with PE is tachypnea (4) which occurs in nine-tenths of patients. Rales and an accentuated pulmonic valve closure are found in a little more than half of patients, and cyanosis is found in approximately one-fifth of the patients presenting with PE (4).

LABORATORY EVALUATION

The most common laboratory study used to evaluate patients suspected of PE is the arterial PO₂ value. Szucs et al. (5) have reported arterial PO₂ values of < 80 mm of mercury in a study of 36 patients with PE. Other studies have demonstrated that patients with PE can have normal arterial PO₂ values (4,6). Unfortunately, many cardiorespiratory diseases cause a decreased arterial PO₂, and often the patient's baseline arterial PO₂ value is not known at the time of acute presentation in elderly or otherwise compromised patients.

Serum LDH values have been found to be elevated in ~ 83% of patients with pulmonary embolism (5). Pneumonitis and other pulmonary disorders may be associated with elevated LDH values, and therefore the finding lacks specificity (7). Other hematologic or biochemical studies have not been found specific or sensitive enough to warrant general use (8).

ELECTROCARDIOGRAM

The electrocardiogram may show changes in the presence of PE, but it lacks sensitivity in detecting PE. Szucs et al. (5) found that most patients with PE have either a normal axis or preexisting axis deviation without change. Acute right axis shift was found in only 15% of the patients with PE. Of the findings that are classically associated with PE (S₁Q₃T₃ pattern, right axis shift, or new incomplete right bundle branch block) only 19% of the patients with PE demonstrated these findings (5).

CHEST RADIOGRAPH

Patients with PE frequently have abnormalities on their chest radiograph. Moses et al. (9) found that infiltrate, pleural effusion, and atelectasis were the most common radiographic findings in patients with PE. Elevated hemidiaphragm, cardiomegaly, and congestive failure were found in lesser frequency in patients with PE. McNeil et al. (10) found that the chest radiographic findings with the greatest positive predictive value in young patients presenting with pleuritic chest pain were the presence of pleural effusions, atelectasis, or infiltrate.

To determine if the chest radiograph has sufficient diagnostic ability to detect PE accurately, a prospective study was performed in 152 patients suspected of having PE (11). The radiographs were reviewed by nine independent observers. The average sensitivity of the chest radiograph to detect PE was 33% and the average specificity was 59%.

Chest radiography has an important role to serve in the evaluation of patients with suspected PE. Pneumonia and other etiologies of the patient's symptoms can be evaluated with the radiograph, and the interpretation of ventilation/perfusion scintigraphy requires its use (12).

VENTILATION/PERFUSION IMAGING METHODS

The ventilation/perfusion (V/Q) lung scan is the study most commonly employed to evaluate patients with suspected PE. The study is safe, readily available, relatively inexpensive, and has a low radiation dose to the patient (13).

Pulmonary embolism causes decreased blood flow to the capillary bed in the lung distal to the embolus. Therefore, agents whose distribution reflects relative lung perfusion are injected intravenously. Autoregulation in the lung decreases

For reprints contact: R.A. Blinder, Box 3949, Duke University Medical Center, Durham, NC 27710.

perfusion to areas that are poorly ventilated to prevent desaturation of the peripheral arterial oxygen supply. Perfusion imaging suffers in specificity since areas that are poorly ventilated due to a variety of causes show perfusion deficit. To improve the specificity of perfusion lung scintigraphy, ventilation imaging is routinely performed. Several agents are available for imaging the relative distribution to ventilation in the human lung. These agents have differing advantages and disadvantages, and one or more may be used at any given clinical center.

Xenon-133 (^{133}Xe) has a physical half-life of 5.3 days and emits an 81 keV photon (14). This photon energy is relatively low for optimal imaging, and therefore there is some loss of image quality. The radiation dose is not very high to the patient due to the very short amount of time that the agent is in contact with respiratory mucosa. Xenon-133 ventilation studies are generally performed prior to the perfusion study, which is a relative disadvantage of ^{133}Xe . If the ventilation study could be performed after the perfusion study, the patient could be placed in the optimal position to evaluate the ventilation in the region of the perfusion abnormality. In addition, a patient who has a normal perfusion study does not need a ventilation study; thus, the amount of radiation a patient receives may be decreased if the ventilation study follows the perfusion study.

Another isotope of xenon, ^{127}Xe , emits a photon with an energy of 203 keV. Because the photon energy is higher than that of $^{99\text{m}}\text{Tc}$, the ventilation scan can be performed after the perfusion scan. Xenon-127 is more expensive than ^{133}Xe . Due to the relatively long half-life (36.4 days) and the higher photon energy, more shielding must be used in the ventilation apparatus, and traps that collect the expelled gas must be appropriately shielded and handled.

Krypton-81m ($^{81\text{m}}\text{Kr}$) has a short half-life (13 sec) but is produced on site from a rubidium-81 generator, which has a half-life of 4.6 hr (21). Because of the short half-life, $^{81\text{m}}\text{Kr}$ does not reach equilibrium in poorly ventilated areas of the lung, and therefore these areas appear photon deficient. The energy of the $^{81\text{m}}\text{Kr}$ photon is higher than that of $^{99\text{m}}\text{Tc}$, and the ventilation scan can be performed after the perfusion scan. With this agent, corresponding ventilation images can be obtained for each perfusion image (15). Krypton-81m is relatively expensive compared to the cost of using ^{133}Xe .

Another method of evaluating ventilation is by aerosolizing liquids that contain radioactive agents (16,17). If the nebulized particles are sufficiently small, they do not settle out on the main airways and their distribution in the lung reflects ventilation (18). A multi-institutional study recently compared a radioaerosol of $^{99\text{m}}\text{Tc}$ DTPA for ventilation imaging with ^{133}Xe and $^{81\text{m}}\text{Kr}$ (18). This study found that ^{133}Xe and $^{81\text{m}}\text{Kr}$ exams were technically uninterpretable \leq to 1% of the time whereas the radioaerosol examinations had a 6% rate of technically uninterpretable exams. The final interpretations of studies using radioactive aerosols agreed fairly well with studies using ^{133}Xe or $^{81\text{m}}\text{Kr}$ ($Kappa = 0.74$ and 0.65) (18).

The most commonly used agents to evaluate perfusion are $^{99\text{m}}\text{Tc}$ -labeled macroaggregates of albumin or human albumin

microspheres. Macroaggregated albumin particles range between 20 to 50 microns in diameter whereas microspheres range from 15 to 40 microns (13). When injected intravenously, these particles mix with systemic venous return to the right heart and are distributed to the lungs in correspondence to the amount of pulmonary blood flow. The particles lodge in the capillaries and prearterioles so that an image is obtained of the pulmonary artery perfusion. The number of precapillary arterioles and capillaries that are blocked by the administration of this agent constitute $< 0.3\%$ of pulmonary circulation, and, therefore, there is no major physiologic effect to the patient (13).

ADDITIONAL RADIOACTIVE IMAGING METHODS

Another method to image PE uses thrombus-avid imaging agents. Many of these agents use various radiolabeled components of the coagulation system.

Platelets labeled with indium-111 (^{111}In) have been able to demonstrate PE in the canine model (19,20). The detection of pulmonary emboli in patients has also been reported in at least two patients (21,22). Indium-111 platelets have a relatively high radiation burden to the spleen, are somewhat difficult to prepare compared to $^{99\text{m}}\text{Tc}$ -labeled MAA, and require a longer time to complete a study. Therefore it is unlikely that this will be a routine imaging procedure to study PE.

Another group of thrombus-avid imaging agents is currently being investigated. These include radiolabeled fibronectin (23), fragment E1 (24), and plasmin (25). Monoclonal antibodies directed against moieties in the coagulation system are being investigated. These include an ^{111}In -labeled antiplatelet antibody (26) and a radioiodinated antibody specific to the NH terminal of fibrin (27). Most of these agents have shown promising results in animals, but widespread clinical trials have yet to be completed. These will be needed before the eventual utility can be determined.

ADDITIONAL RADIOGRAPHIC METHODS

Other imaging methods to detect PE include digital subtraction angiography, transmission computed tomography, magnetic resonance imaging, and pulmonary angiography. Digital subtraction angiography enhances contrast sensitivity when compared to the more conventional forms of angiography. This enhancement allows a lower concentration of intravascular contrast to be used, and permits one to inject the contrast proximal to the pulmonary arteries such as in the antecubital veins. The method is simpler to perform than conventional angiography since one does not have to traverse the right heart with a catheter. Thus, a lower complication rate is expected. Unfortunately, the method is sensitive to motion artifacts, and cooperation by the patients to hold their breath during imaging is very important.

In patient studies, digital subtraction angiography has had varying results. Reports vary from 100% accuracy (28) to 45% sensitivity with 100% specificity (29). In an ongoing study at our institution, digital subtraction angiography correlated

with angiography in 17 of 18 cases (30).

The technology of digital subtraction angiography is being improved with more rapid filming rates, cardiac gating, and improvements in the methods of analyzing images. This modality may eventually have a greater role in the workup of PE.

Transmission computed tomography has been able to detect oligemia experimentally produced in dogs (31) and identify experimentally produced emboli in lobar segmental arteries (32). The major clinical role of transmission computed tomography is in the evaluation of central pulmonary embolus prior to surgical embolectomy (33,34) since it provides a cross-sectional view of the vessels that most accurately determines the extent of occlusion of a vessel. Transmission computed tomography lacks sufficient sensitivity for a small thrombus to be useful in evaluating patients suspected of pulmonary embolism.

Magnetic resonance imaging (MRI) has been shown to image experimentally produced pulmonary emboli which have been imaged in the canine model (35). A pulmonary embolus in a 30-yr-old female patient has been detected (36).

Imaging of blood vessels with MRI does pose some difficulty. Flowing blood occasionally causes an increased signal which could be confused with thrombus (37). Also, periodic motion by patient breathing can lead to artifacts that may confound interpretation. These and other problems are currently being worked on by major research centers and manufacturers of MRI imagers. Therefore, it is difficult to determine what future role MRI will play in the diagnosis of PE.

Conventional pulmonary angiography is currently considered the gold standard for diagnosing PE. The exam is time consuming, expensive, has a somewhat high radiation burden to the patient, and has a risk of complications. In a series of 1,350 pulmonary angiograms performed over 11 years in our institution, the rate of complication was 5% with a 0.2% mortality rate (38).

Although pulmonary angiography is considered to have good diagnostic accuracy, it is not an ideal method to use as the first diagnostic modality of choice to diagnose PE due to cost, potential risk, and time. Currently, most centers first perform a ventilation/perfusion lung scan, and proceed to pulmonary angiography when the lung scan has not sufficiently raised or lowered the probability of PE enough for the physician to either treat the patient or terminate the workup. It is very important that the physician understand and properly use the ventilation/perfusion lung scan interpretation to appropriately treat patients.

INTERPRETATION OF VENTILATION/PERFUSION SCANS

The finding on a perfusion scan indicates that PE is nonperfused segments of lung. Unfortunately, many other entities such as obstructive airway disease, inflammatory disease, atelectasis, scarring, and neoplasms can also decrease perfusion. The specificity of the perfusion scan is improved by using the ventilation study.

Information from the perfusion scan, ventilation scan, and

chest radiograph must be incorporated into the interpretation of the ventilation/perfusion lung scan. Researchers have not been able to take the various complex patterns available in these three imaging modalities and reduce them to a single probability statement indicating whether or not PE is present or absent. Instead, empiric research has determined that various patterns of the ventilation-perfusion lung scan and chest radiograph are associated with various degrees of likelihood of PE (39-47). These patterns are interpreted as high probability, indeterminate or intermediate, low probability, or normal.

In the studies cited above, the patterns of ventilation and perfusion abnormalities used to categorize the scans are not identical. In general, > 2 segments of lung that show perfusion deficit without ventilation abnormality are considered high probability for pulmonary embolism. Very small perfusion defects < 25% of a segment of lung usually are considered low probability for PE. Very large portions of lung showing matched ventilation-perfusion defect due to chronic obstructive pulmonary disease, or matched ventilation-perfusion abnormality with a similar sized opacity on chest radiograph, usually are considered indeterminate for PE.

USE OF BAYES' THEOREM

The ventilation-perfusion lung scan is not a perfect test in that it does not discriminate with 100% accuracy those patients with PE from those patients without PE. In the 1700s, Rev. Thomas Bayes demonstrated this with a test that does not discriminate perfectly between the presence and absence of disease. The probability that a patient harboring disease is dependent not only on the test finding but also on the pretest probability that the patient has the disease. Mathematically, this concept is now referred to as Bayes' theorem. Hence, if a physician is to utilize properly the results from the ventilation-perfusion lung scan, he must understand how each lung scan pattern affects the pretest probability that the patient has the disease to determine the post-test probability for the presence of PE (48). The mathematical form of Bayes' theorem that is most easily understood intuitively is that of the odds-likelihood ratio equation (49). The likelihood (Li) ratio is a quotient that implies how strongly a test finding is associated with the presence of disease. The numerator of the Li ratio is the true-positive fraction or sensitivity of the test. The true-positive fraction is obtained from a study that compares the test against a "gold standard" test and is the fraction of patients with the test finding present who have the disease, divided by all those patients in the population that have the disease. The denominator of the Li ratio is the false-positive fraction, (or in a dichotomous test, 1 - specificity.). This again is derived from a study using a "gold standard" test, and is the fraction of patients with the test finding present who do not have the disease present, divided by all those patients in the population without disease. Once the Li ratio is obtained from such a study, it can be used with the Bayes' theorem to predict the likelihood that patients have the disease with the test finding given their odds of having the disease. The odds-likelihood

ratio of Bayes' theorem is stated below (49).

$$\text{Post-test odds patient has the disease} = \text{Li ratio} \times \text{Pretest odds patients has the disease}$$

Odds are merely another method of reporting probabilities. To convert probabilities into odds, the following formula is used:

$$\text{Pretest odds patient has the disease} = \frac{\text{Prevalence of disease in population (pretest probability)}}{1 - \text{Prevalence of disease in population (pretest probability)}}$$

Hence, if the pretest probability is 10%, the pretest odds are $0.10/0.90 = 1/9$ or 1 to 9.

By examining the odds-likelihood ratio formula one can see that if the true-positive fraction is very small, and the false-positive fraction is very large, the Li ratio is a small number, and the presence of this particular pattern on ventilation-perfusion lung scans would decrease the odds that the patient has PE. If the pattern is highly associated with PE, the true-positive fraction would be very large, the false-positive fraction very small, and Bayes' theorem would show that these

particular findings would markedly increase the odds that the patient has PE. If the true-positive fraction is approximately equal to the false-positive fraction, the Li ratio is approximately equal to one, and the finding does not alter the pretest odds that the patient has the disease. Scintigraphic patterns with high Li ratios can be considered high probability for PE in that they will take relatively low pretest odds that the patient has the disease and produce relatively high post-test odds. Scintigraphic patterns with very low Li ratios (much less than one) are interpreted as low probability patterns in that they markedly reduce the odds that the patient has the presence of PE. Scintigraphic patterns with Li ratios around one can be considered indeterminate in that they do not really alter the pretest likelihood for the presence of PE.

Graphic displays of Bayes' theorem for three scintigraphic categories of ventilation-perfusion lung scan from a recent report are presented (Fig. 1). These graphs are presented as probabilities instead of odds for the sake of clarity. On the ordinate, the pretest probability that the patient has the disease is found. From the graph, the post-test probability is read off of the abscissa. One can see that a low probability scan (Fig. 1A) will take a fairly high pretest probability of PE and reduce it to a small post-test probability. Hence, the patient that is

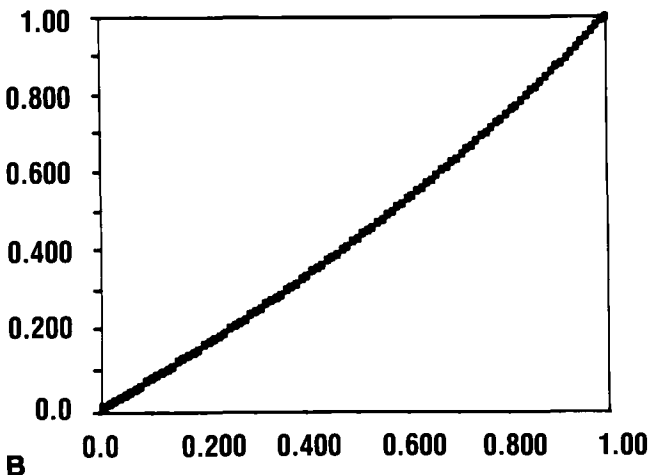
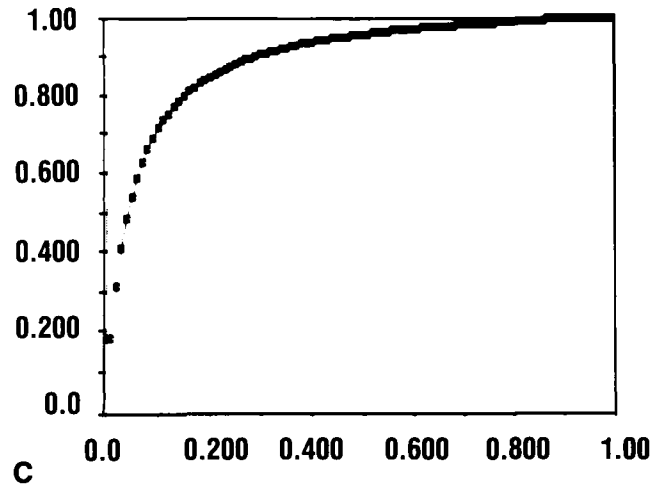
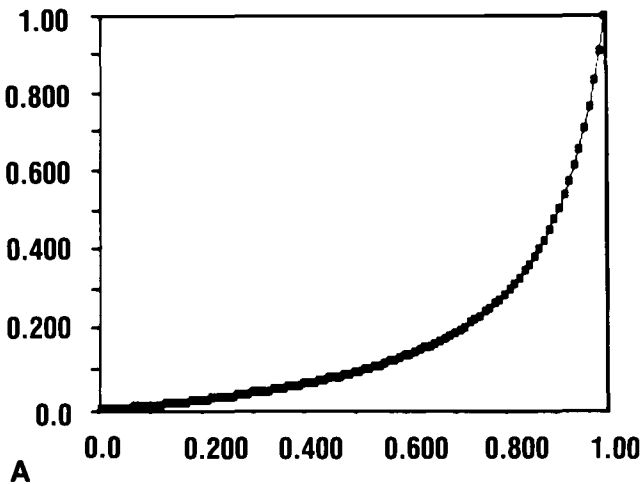


FIG. 1. Three graphs demonstrating the operational characteristics of Bayes' theorem for three different lung scan patterns: the x coordinate of the graph is the pretest probability that this patient has pulmonary embolism. The y coordinate, which is obtained from the graph, is the post-test probability of disease. (A) Probability graph for subsegmental defects on perfusion scan. The Li ratio here is 0.1, and the exam demonstrates a low probability pattern. A relatively high input probability (50%) yields a post-test probability of less than 10%. (B) Probability graph for a single defect on the perfusion scan. The Li ratio is equal to 0.75, which is near enough to 1 so that the pretest probability approximately equals the post-test probability. This might be considered an indeterminate examination since it did not markedly change the pretest probability. (C) High probability pattern, multiple segmental or greater defects that are not matched by ventilation abnormality. This pattern has an Li ratio of 22.3 and is considered high probability for pulmonary embolism. A relatively low input probability (25%) yields a greater than 85% post-test probability of pulmonary embolism with this pattern. Data derived from McNeil (43).

not highly suspected of PE may have the workup terminated when this scintigraphic finding occurs. An indeterminate Li ratio which is found with the single perfusion defect, (Fig. 1B) the pretest probability, approximately equals the post-test probability of disease. Therefore most patients should then be worked up further to determine whether or not PE is present. A high probability lung scan pattern such as multiple segmental defects without ventilation abnormality (Fig. 1C) will take a patient with a very low pretest probability of disease and produce a very high post-test probability of disease. In this setting, the workup can be terminated and the patient treated for PE unless there is contraindication to anticoagulant therapy, in which case further testing is desirable to bring the probability as close to certainty as possible before placing the patient at risk.

Unfortunately, there is no exact method to determine the pretest probability that a patient has PE. Therefore, it is unwise to assume that there is any numerical accuracy to ascribing numerical post-test probability that the patient has PE with the scintigraphic pattern. Rather the high probability, indeterminate range, and low probability scans should be viewed on how they operate on ranges of input probability. The low probability scan with low to moderate input probabilities of PE will produce a low enough post-test probability so that the workup can be terminated. If there is at all a moderate or high probability entering the examination, further workup should probably be undertaken. Again, in all but the lowest input probability to a high probability scintigraphic pattern, the post-test probability of disease is sufficiently high enough to terminate the workup in most patients.

UTILIZATION OF VENTILATION/PERFUSION SCANS

Saenger et al. (50) evaluated the use of lung scans in over 2,000 patients to determine how the lung scans influenced the referring physician's management of the patient. Logistic regression and entropy minimax pattern detection (51) were used to evaluate the data. They found that ventilation perfusion lung scan significantly influenced the referring physician's probability for PE. The lung scan results also correlated well with the therapeutic management the patient received. In a recent study in our institution (52), we studied 566 consecutive patients referred for ventilation-perfusion lung scans for suspected PE to determine how the lung scan interpretation affected the clinical management of the patient. The clinicians were asked to estimate the pretest probability of PE (low = <20%, medium = 20 - 80%, or high = >80%). We found that patients with high probability lung scans were treated for PE regardless of the clinical pretest estimate. Of interest was that low and intermediate probability lung scans resulted in most patients not being treated for PE and not referred to pulmonary angiography for further workup. Considering the post-test probability expected from indeterminate or intermediate lung scan results with moderate pretest probabilities, and the post-test probability from a low probability lung scan pattern coupled with a high pretest probability, pulmonary angiography was

probably underutilized when one considers Bayes' theorem.

On theoretical grounds, it would appear that the lung scan should be utilized as follows. Patients with moderate or high pretest probability of PE and high probability lung scans should be treated for PE unless there is contraindication to the anticoagulant therapy. Patients with low or moderately low pretest probabilities of PE and low probability lung scans should be considered not to have PE and their workup terminated. In all other settings, the post-test probability of PE may not be sufficiently high or low, and further workup should be considered. This theoretical approach is similar to the results by Hull et al. (53) in a prospective study of 305 patients evaluated for PE. They found high probability scans were strongly associated with the presence of PE, but other scintigraphic patterns still had a high association with PE. The fact that patients with low probability scans in this study still had a probability of 25%-40% for PE may reflect the high pretest probability or prevalence in their tested population.

Since it appears that many patients will progress from the lung scan to pulmonary angiography, some clinicians question whether the lung scan is useful at all. At our institution it is felt that all patients should first be studied by the ventilation-perfusion lung scan because: 1) high probability scans, low probability scans, or normal scans may terminate the workup in the appropriate clinical setting; and 2) the areas of abnormality on the lung scan can direct the angiographer as to which portions of the lungs to study by pulmonary angiography.

SUMMARY

Pulmonary embolism is still a difficult diagnosis to make clinically and by imaging procedures. New modalities and methods are currently under evaluation to detect PE, and only further work will determine how useful these will be clinically. Because of the cost, complexity, and potential risk of pulmonary angiography, it appears that the best method to evaluate PE after clinical examination is the ventilation-perfusion lung scan. Results of this study must be coupled with an approximate pretest probability to determine if further workup is needed. Unfortunately, this pretest probability is not an exact science, and, hence, it is the skill and knowledge of the referring physician that decides whether sufficient certainty regarding the presence of PE has been reached.

Russell A. Blinder, MD
Duke University Medical Center,
Durham, North Carolina

ACKNOWLEDGMENTS

This work was supported by NIH Grants HL07503, HL17670, and CA33541. The author thanks Wendy Horton for her excellent secretarial assistance in preparing this manuscript.

REFERENCES

1. Dalen JE, Alpert JS. Natural history of pulmonary embolism. *Prog Cardiovasc Dis* 1975;17:259-270.

2. Mant MJ, Thong KL, Kirtwhistle RV, et al. Hemorrhagic complications of heparin therapy. *Lancet* 1977;1:1133-1135.
3. Porter J, Jick H. Drug related deaths among medical inpatients. *JAMA* 1977, 237:879-881.
4. The urokinase pulmonary embolus trial—A national cooperative study. *Circulation* 1973;47(Supp. 2):71-86.
5. Szucs MM, Brooks HL, Grossman W, et al. Diagnostic sensitivity of laboratory findings in acute pulmonary embolism. *Ann Intern Med* 1971;74:161-166.
6. Menzoian JO, Williams LF. Is pulmonary angiography essential for the diagnosis of acute pulmonary embolism? *Amer Jour Surg* 1979;137:543-548.
7. Fischer KC, McNeil BJ. The indeterminate lung scan: Its characteristics and its association with pulmonary embolism. *Eur Jour Nucl Med* 1979;4:49-53.
8. Sasahara AA, Sharma GVRK, Barsamian EM, et al. Pulmonary thromboembolism: diagnosis and treatment. *JAMA* 1983;249:2945-2950.
9. Moses DC, Silver TM, Bookstein JJ. The complementary roles of chest radiography, lung scanning, and selective pulmonary angiography in the diagnosis of pulmonary embolism. *Circulation* 1974;49:179-188.
10. McNeil BJ, Hessel SJ, Branch WT, et al. Measures of clinical efficacy. III. The value of the lung scan in the evaluation of young patients with pleuritic chest pain. *J Nucl Med* 1976;17:163-169.
11. Evens RG, Siegel BA, Welch MJ, et al. Cost analyses of positron emission tomography for clinical use. *AJR* 1983;141:1073-1076.
12. Greenspan RH, Ravin CE, Polansky SM, et al. Accuracy of the chest radiography in diagnosis of pulmonary embolism. *Invest Radiol* 1982;17:539-543.
13. Davis MA. Particulate radiopharmaceuticals for pulmonary studies. In: Subramanian G, Rhodes BA, Cooper JF, Sodd VJ, eds. *Radiopharmaceuticals*. New York: The Society of Nuclear Medicine, 1975:267-281.
14. Ponto RA, Loken MK. Radioactive gases: Production, properties, handling, and uses. In: Subramanian G, Rhodes BA, Cooper JF, Sodd VJ, eds. *Radiopharmaceuticals*. New York: The Society of Nuclear Medicine, 1975:296.
15. Goris ML, Daspit SG, Walter JP et al. Applications of ventilation lung imaging with ^{81m}Krypton. *Radiology*, 1977;122:399-403.
16. Taplin GV, Chopra SK, MacDonald NS, et al. Imaging small pulmonary ischemic lesions after radioactive carbon monoxide inhalation. *J Nucl Med*, 1976;17:866-871.
17. Taplin GV, Poe ND. A dual lung scanning technique for evaluation of pulmonary function. *Radiology*. 1965;85:365-368.
18. Alderson PO, Biello DR, Gottschalk A, et al. Tc-99m-DTPA aerosol and radioactive gases compared as adjuncts to perfusion scintigraphy in patients with suspected pulmonary embolism. *Radiology*, 1984;153:515-521.
19. McIlmoyle G, Davis HH, Welch MJ. Scintigraphic diagnosis of experimental pulmonary embolism with In-111-labeled platelets. *J Nucl Med* 1977;18:910-914.
20. Sostman HD, Neumann RD, Zoghbi SS, et al. Experimental studies with ¹¹¹Indium-labeled platelets in pulmonary embolism. *Invest Radiol* 1982;17:367-374.
21. Ezekowitz MD, Eichner ER, Scatterday R, et al. Diagnosis of a persistent pulmonary embolus by indium-111 platelet scintigraphy with angiographic and tissue confirmation. *Am J Med* 1982;72:839-842.
22. Sostman HD, Neumann RD, Loke J, et al. Detection of pulmonary embolism in man with ¹¹¹In-labeled autologous platelets. *AJR* 1982;138:945-947.
23. Kulkarni PV, Parkhill BJ, Wilson JE, et al. Radioiodinated fibronectin: A potential thrombus localizing radiopharmaceutical. *J Nucl Med* 1982;23:26.
24. Knight LC, Maurer AH, Robbins PS, et al. Fragment E₁ labeled with I-123 in the detection of venous thrombosis. *Radiology* 1985;156:509-514.
25. Feiglin DHI, Cerone-Warbrick A, Ng IC, et al. Tc-99m plasmin: Preliminary evaluation of usefulness in the detection of deep vein thrombosis. *Radiology* 1984;153(P):149(A).
26. Oster ZH, Srivastava SC, Som P, et al. Scintigraphic detection of thrombi and intimal injury with monoclonal antiplatelet antibody in dogs. *Radiology* 1984;153(P):149(A).
27. Rosebrough SF, Kudryk B, Grossman ZD, et al. Radioimmunoimaging of venous thrombi using iodine-131 monoclonal antibody. *Radiology* 1985;156:515-517.
28. Goodman PC, Brant-Zwadzki M. Digital subtraction pulmonary angiography. *AJE* 1982;139:305-309.
29. Williams DM, Smith R, Kyang JC, et al. DSA: Role in the diagnosis of pulmonary embolism. *Radiology* 1984;153:113 (A).
30. Newman GE, Ford KK, Dunnick NR, et al. The advantages and disadvantages of digital subtraction pulmonary angiography in the diagnosis of pulmonary embolism. (Abst.) *AJR* 1985.
31. Grossman ZD, Ritter CA, Tarner RJ, et al. Successful identification of oligemic lung by transmission computer tomography after experimentally produced acute pulmonary arterial occlusion in the dog. *Invest Radiol* 1981;16:275-280.
32. Ovenfors C, Godwin JD, Brito AC. Diagnosis of peripheral pulmonary emboli by tomography in the living dog. *Radiology* 1981;141:519-523.
33. DiCarlo LA, Schiller NB, Herfkens RJ, et al. Noninvasive detection of proximal pulmonary artery thrombosis by two-dimensional echocardiography and computerized tomography. *Am Heart J* 1982;104:879-881.
34. Godwin JD, Webb WR, Gamsu, et al. Computed tomography of pulmonary embolism. *AJR* 1980;135:691-695.
35. Gamsu G, Hirji M, Moore EH, et al. Experimental pulmonary emboli detected using magnetic resonance. *Radiology* 1984;153:467-470.
36. Moore EH, Gamsu G, Webb WR, et al. Pulmonary embolus: Detection and follow-up using magnetic resonance. *Radiology* 1984;153:417-471.
37. Waluch V, Bradley WG. NMR even echo rephasing in slow laminar flow. *J Computer Assist Tomogr* 1984;8:594-598.
38. Mills SR, Jackson DC, Older RA, et al. The incidence, etiologies and avoidance of complications of pulmonary angiography in a large series. *Radiology* 1980;136:295-299.
39. Biello DR, Mattar AG, McKnight RC, et al. Ventilation-perfusion studies in suspected pulmonary embolism. *AJR* 1979;133:1033-1037.
40. Bogren HG, Berman DS, Vismara LA, et al. Lung ventilation-perfusion scintigraphy in pulmonary embolism. Diagnostic specificity compared to pulmonary angiography. *Acta Radiologica Diag* 1978;19:933-944.
41. Braun SD, Newman GE, Ford K, et al. Ventilation-perfusion scanning and pulmonary angiography: Correlation in clinical high-probability pulmonary embolism. *AJR* 1984;143:977-980.
42. Carter WD, Brady TM, Keyes JW, et al. Relative accuracy of two diagnostic schemes for detection of pulmonary embolism by ventilation-perfusion scintigraphy. *Radiology* 1982;145:447-451.
43. McNeil BJ. A diagnostic strategy using ventilation-perfusion studies in patient suspected for pulmonary embolism. *J Nucl Med* 1976;17:613-616.
44. McNeil BJ. Ventilation-perfusion studies and the diagnosis of pulmonary embolism: Concise communication. *J Nucl Med* 1980;21:319-323.
45. McNeil BJ, Holman BL, Adelstein SJ. The scintigraphic definition of pulmonary embolism. *JAMA* 1974;227:753-756.
46. Sullivan DC, Coleman RE, Mills SR, et al. Lung scan interpretation: Effect of different observers and different criteria. *Radiology* 1983;149:803-807.
47. Taplin GV, Chopra SK. Lung-perfusion-inhalation scintigraphy in obstructive airway disease and pulmonary embolism. *Radiol Clin North Am* 1978;16:491-513.
48. Vea HW, Sirota PS, Nelp WB. Ventilation-perfusion scanning for pulmonary embolism: Refinement of predictive value through Bayesian analysis. *AJR* 1985;145:967-972.
49. Weinstein ML, Fineberg HW. The use of diagnostic information to revise probabilities. In: *Clinical Decision Analysis*. Philadelphia: W.B. Saunders Company, 1980.
50. Saenger EL, Buncher CR, Specker BL, et al. Determination of clinical efficacy: Nuclear medicine as applied to lung scanning. *J Nucl Med* 1985;26:793-806.
51. Gift DA, Schonbein WR, Saenger EL, et al. Application of an information-theoretic method for efficacy assessment. *J Nucl Med* 1985;26:807-811.
52. Frankel N, Coleman RE, Pryor DB, et al. Utilization of lung scans by clinicians. *J Nucl Med* 1986;27:366-369.
53. Hull RD, Hirsh J, Carter CJ, et al. Diagnostic value of ventilation-perfusion lung scanning in patient with suspected pulmonary embolism. *Chest* 1985;88:819-828.