

Continuing Education

Thyroid Imaging Studies

Helen H. Drew, Norman D. LaFrance, and James J.S. Chen

The Johns Hopkins Medical Institutions, Baltimore, Maryland

This is the second in a series of Continuing Education articles related to functional/quantitative imaging techniques. After reading this article, the reader should be able to: 1) discuss the clinical applications of thyroid imaging; 2) understand the relationship of related thyroid tests; and 3) recognize the pitfalls and problems associated with this procedure.

Thyroid imaging has had a long run as an important nuclear medicine evaluation. Although evolved and expanded in scope, the unique functional and structural information obtained along with excellent cost effectiveness and safety has not been duplicated optimally by other nontracer modalities. Our emphasis is directed at thyroid imaging; however, a complete thyroid study requires correlation with thyroid function studies, clinical history, and physical examination. A brief basic review of the thyroid may help enhance this overview article.

The thyroid gland enjoys an important place in the history of nuclear medicine. It was among the first organs to be studied by radioactive tracers and the first to be imaged by scintillation technique after the administration of radioiodine. This was reported in 1951 in two separate articles by Allen et al. (1) and Cassen et al. (2), whose techniques by today's standards were relatively basic. Since these first reports, significant improvement has occurred in instrumentation while changes in the radiopharmaceuticals have lowered the patient's dose equivalent and have allowed for the evaluation of an even broader spectrum of thyroid disorders.

THE THYROID GLAND

Anatomy

The thyroid gland is located in the anterior neck with its two lobes extending from the thyroid cartilage to just above the suprasternal notch bilaterally. The gland consists of two lateral lobes joined by a thin band of tissue, the isthmus, inferiorly. The gland's name is derived from the Greek word

thyro, meaning shield, which is quite descriptive of the thyroid's shape. The isthmus overlies the trachea anteriorly and is located just caudal to the level of the cricoid cartilage with each thyroid lobe extending laterally. A narrow strip of thyroid tissue called the pyramidal lobe may also be seen. The pyramidal lobe extends upward from the isthmus along the thyroid cartilage. During embryonic development the thyroid is derived from endodermal tissue in the region of the first pharyngeal pouch. The median outgrowth migrates downward and bifurcates at the lower end to form the lateral lobes and isthmus. Because of this embryonic migration normal thyroid tissue may be found from the base of the tongue to the level of the diaphragm.

The thyroid's arterial blood supply arises from both the external carotids, which give off the superior thyroid arteries and the subclavian arteries, which supply the inferior thyroid arteries accounting for a highly vascularized gland.

The structural and functional unit of the thyroid gland is the thyroid follicle. Spherical in shape with an average diameter of 300 μm , the wall is composed of cuboidal epithelial cells arranged in a single layer. The thyroid follicular cells are the site of thyroid hormone synthesis, and the follicle lumen functions as a storage unit.

Physiology and Pathophysiology

The primary function of the thyroid gland is to synthesize, store, and secrete the thyroid hormones thyroxine (T_4) and triiodothyronine (T_3). Thyroid hormones exert a peripheral metabolic effect, including influence on growth and development, regulation of every organ system, and temperature homeostasis, along with carbohydrate, lipid, protein, nucleic acid, vitamin, and mineral metabolism. The principal mechanism of action appears to be mediated by a receptor localized in the cell's nucleus, which modulates DNA and RNA synthesis, which in turn influences protein synthesis. For example, when T_4 levels are increased DNA and RNA synthesis is accelerated, and therefore protein synthesis is increased (3).

The regulation of thyroid hormone synthesis and secretion is controlled by a negative feedback mechanism of thyroid hormone on the anterior pituitary and the hypothalamus.

For reprints contact: Helen Drew, Nuclear Medicine, The Johns Hopkins Hospital, 600 N. Wolfe Street, Baltimore, MD 21205.

Thyrotropin releasing factor (TRF) is secreted by the hypothalamus into the portal vessels of the pituitary stalk and is transported directly to the anterior pituitary. Thyroid stimulating hormone (TSH) synthesis by the anterior pituitary is stimulated by TRF, resulting in increased blood levels of TSH. At the level of the thyroid, TSH regulates thyroidal uptake of iodide (I^-) synthesis and release of hormone into the circulation, with increased TSH upregulating all of these thyroid actions.

Trapping. The first step in the synthesis of the thyroid hormone is the extraction of iodide from the blood by the thyroid gland. Dietary ingested iodine in the United States has greatly increased in recent years due to iodine supplementation. Ingested iodine is reduced to iodide in the upper intestine. In the first 60 min after ingestion, approximately 90% is absorbed and distributed into the vascular space. This energy-dependent iodide concentrating mechanism of the thyroid gland, referred to as the iodide trap, is linked to the Na^+ , K^+ -ATPase-dependent transport system and is carried out by the thyroid follicular cells. Thyroidal iodide concentrations normally reach levels of 25–30 times that of the plasma level (4).

Organification. The next step in thyroid hormone synthesis takes place at the surface of the thyroid follicular cells (described as the colloid aspect of the follicular cell) and is referred to as organification. The trapped iodide is oxidized to iodine catalyzed by a peroxidase and H_2O_2 mechanism. The oxidized iodide then reacts with the tyrosyl moiety of thyroglobulin to form monoiodotyrosine globulin and diiodotyrosine globulin. Thyroglobulin is a glycoprotein that contains 120 tyrosine residues and is stored in the follicular lumen.

Coupling. Coupling of two diiodotyrosine molecules forms T_4 , whereas the combination of one monoiodotyrosyl molecule and one diiodotyrosyl molecule forms T_3 . Both T_4 and T_3 are the physiologically active thyroid hormones. Thyroid hormone is then stored in the follicle bound to thyroglobulin until needed.

Release. Proteolytic enzymes release T_4 and T_3 from thyroglobulin and the free thyroxine and triiodothyronine enter the peripheral circulation (5). This release is stimulated by TSH.

Once in the peripheral circulation, T_4 and T_3 bind almost completely to a specific plasma protein, thyroxine-binding-globulin (TBG). T_4 also binds to a T_4 binding prealbumin (TBPA) and to albumin. These plasma proteins provide the transport vehicle to the peripheral tissues, and prohibit the thyroid hormones from exhibiting their metabolic effects. T_3 is principally bound by TBG, but there is much less affinity of TBG for T_3 . It is the nonbound thyroid hormone that exhibits its physiologic effects. Specifically, 99.97% of plasma T_4 and 99.7% of plasma T_3 are protein bound, and only the 0.03% free T_4 and 0.3% free T_3 are available to exert their physiologic effects. This concept becomes important in a variety of conditions because although free and total hormone values typically correlate, a number of disorders (e.g., nonthyroidal illness, drugs, etc.) can affect TBG or TBG binding sites and change total hormone levels. In this case total hormone values should be interpreted with caution since the physiologically pertinent

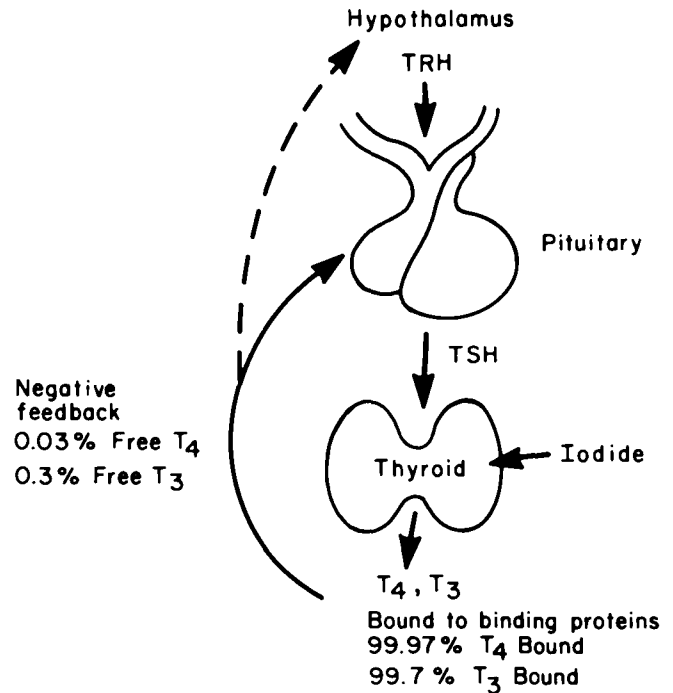


FIG. 1. Hypothalamic-pituitary-thyroid axis.

free T_3 and T_4 levels may differ from the total T_3 and T_4 values.

Currently it is believed that both free T_4 and free T_3 exert biologic activity (6), but T_3 is the more physiologically active of the two thyroid hormones in spite of its 60 times lower concentration compared to T_4 . The majority of circulating T_3 results from the 5' monodeiodination of T_4 in the peripheral tissues and is not solely derived from thyroid gland synthesis. A 5-position monodeiodination (rather than 5' as noted above) of T_4 can occur in certain clinical conditions, such as chronic illness, prolonged stress, and starvation, forming reverse T_3 . Reverse T_3 is much less metabolically active than T_3 .

An elegant negative feedback mechanism exists to control thyroid activity. The free thyroid hormone exerts a direct effect upon the pituitary by inhibiting synthesis and secretion of TSH, thereby decreasing the stimulation of the thyroid gland to make thyroid hormone. The free thyroid hormone may also directly affect the hypothalamus. Figure 1 illustrates the normal regulatory mechanism for thyroid hormone production. This mechanism is referred to as the hypothalamic-pituitary-thyroid axis. Recent studies indicate it is likely the T_3 within the pituitary, rather than the T_4 , that regulates TSH secretion. Intracellular T_3 in pituitary thyrotrophs comes from two sources. One source is the intravascular free T_3 that enters directly from the bloodstream; a more important source is the T_3 converted intracellularly from T_4 that occurs within the pituitary itself. As a result, the thyrotrophs, which possess an active T_4 5'-deiodinase, are relatively more dependent on circulating T_4 than T_3 for feedback inhibition.

Pathophysiology

Defects in thyroid hormone production can involve any of the steps mentioned above. This results in either an under- or an overproduction of thyroid hormone. This in turn influences

metabolic effects upon various organ systems and emphasizes the importance of thyroid function tests, which may need to be complemented by imaging techniques.

Hyperthyroidism. Elevated levels of plasma thyroid hormones (hyperthyroxinemia or hypertriiodothyroninemia) if accompanied by elevated free hormone levels will cause a patient to become hypermetabolic. The most common cause is Graves' disease, with a prevalence of approximately 30 out of 1,000 in the general population. It occurs four to eight times more often in women than in men, and can occur from birth to old age. Its peak incidence is in the third to fourth decades. Less common causes include toxic multinodular goiter, toxic adenoma, the hyperthyroid phase of iodine-induced hyperthyroidism, subacute thyroiditis, and factitious hyperthyroidism from clandestine use of thyroid hormone medication.

Graves' disease is an autoimmune disorder. Among the multiple antibodies endogenously produced in these patients is a thyroid stimulating immunoglobulin (TSI) directed against the TSH receptors. This immunoglobulin has the capacity to stimulate the thyroid cells to produce thyroid hormone in a similar manner as TSH. Typically the Graves' thyroid gland is diffusely enlarged and frequently will have an accompanying hypervascularity. Patients with Graves' disease may develop exophthalmopathy, a secondary manifestation of the disease on retroorbital tissue. The goal of treatment is control of the excessive thyroid hormone production, either by suppression of organification with antithyroid drugs or destruction or removal of tissue with radioactive iodine or subtotal thyroidectomy, respectively (7).

Hyperthyroidism can result from autonomous functioning tissue in a solitary toxic adenoma or toxic multinodular goiter. Despite the suppression of pituitary TSH secretion, autonomous thyroid tissue in these two diseases continues to synthesize and secrete thyroid hormones excessively. Antithyroid drugs followed by radioiodine ablation are frequently used to control this type of hyperthyroidism. Thyroidectomy is indicated when one encounters a large toxic multinodular goiter unresponsive to drugs and iodine-131 (^{131}I) ablation. Surgery is more likely to be a preferable therapy when airway compromise exists.

Transient Hyperthyroidism. In the early phase of subacute thyroiditis or in the acute phase of glandular destruction from inflammation or other etiology, transient thyrotoxicosis may occur due to leakage of preformed hormone from the follicular cells. Paradoxically, symptomatic treatment rather than definitive treatment is desirable, since when this phase passes after depletion of preformed hormone, hypothyroidism follows in 25%–50% of cases and thyroid hormone supplement rather than antithyroidal medication may ultimately become necessary.

Hypothyroidism. Decreased tissue levels of thyroid hormone cause the symptoms of hypometabolism. Patients with primary thyroid gland failure have increased serum levels of TSH and decreased serum levels of T_4 and T_3 . Pituitary or hypothalamic failure have normal or less elevated levels of TSH in the setting of decreased thyroid hormone levels. The most common cause of hypothyroidism is an autoimmune thyroiditis, referred to as Hashimoto's thyroiditis, which is an inflammatory disease

of the thyroid. Other inflammatory processes may cause thyroiditis and can be secondary to bacterial, fungal, or viral etiologies. Congenital deficiencies of specific enzymes in the biosynthetic pathway of thyroid hormone synthesis or the presence of enzymes of abnormal structure that do not function properly are found in patients with hypothyroidism and goiters. An infant born with dysgenesis or agenesis of the thyroid can suffer severe mental and physical retardation unless the abnormality is detected and treated soon after birth. This finding has resulted in the appropriate screening of all neonates for hypothyroidism. Other common causes of hypothyroidism include previous radioactive iodine therapy for hyperthyroidism, prior thyroidectomy, and radiation therapy for head or neck tumor. Less commonly, hypothyroidism results from hypothalamic-pituitary diseases, endemic iodine deficiency (rare in the United States, but more common in developing countries), or peripheral thyroid hormone resistance.

THYROID RADIOPHARMACEUTICALS

All radiopharmaceuticals used for thyroid uptake and imaging localize in the gland by the trapping mechanism of iodine. The physical characteristics of ^{123}I , 159 keV gamma emission, make this radionuclide particularly useful. The 13-hr half-life, and absence of β radiation is why the radiation dose to the gland from ^{123}I is a small fraction of that from an equivalent ^{131}I dose. All $^{124}\text{Te}(p,2n)^{123}\text{I}$ preparations are contaminated with small amounts of high energy ^{124}I , which increase with time due to the difference in $T_{1/2}$ between ^{123}I and ^{124}I . Therefore, doses should be used within 12–24 hr of calibration. An alternate method of production, $^{127}\text{I}(p,5n)^{123}\text{Xe} \rightarrow ^{123}\text{I}$ does not have ^{124}I contamination although it contains ^{125}I contamination. Although it is still used, in part because of low cost, availability, and shelf life, ^{131}I is not the most optimal radionuclide for routine diagnostic testing. It gives a higher dose equivalent to the thyroid than other radionuclides and its gamma ray spectrum is not suited for high resolution gamma camera imaging.

Technetium-99m ($^{99\text{m}}\text{Tc}$) pertechnetate is widely used for thyroid imaging studies. Its advantages over ^{123}I are its low cost, widespread availability, and lower thyroid radiation dose equivalent. Table I lists absorbed doses for the three most commonly used radiopharmaceuticals for thyroid testing (8). Technetium-99m pertechnetate works as a thyroid tracer because the pertechnetate ion is trapped by the thyroid, but not organified. Maximum $^{99\text{m}}\text{Tc}$ -pertechnetate concentration inside the thyroid gland occurs 30 to 45 min after intravenous administration. Therefore, optimum imaging times are between 20 and 30 min. After 60 min, thyroid and blood radioactivity begin to drop, causing a drop in count rate.

Technetium-99m-pertechnetate or ^{123}I are appropriately replacing ^{131}I for routine thyroid imaging. When ^{123}I became available, the question was raised as to which radionuclide should be used for routine studies. Iodine-123 has the characteristic of being physiologic in nature, that is, initial trapping and organification can be studied. Technetium-99m-pertechnetate has the advantage of a shorter test time. Both $^{99\text{m}}\text{Tc}$

TABLE 1. Absorbed Doses for Thyroid Radiopharmaceuticals in Adults

Isotope	Recommended administered activity (μCi)	Thyroid gland dose		Whole-body dose (mrad)
		(mrad/ μCi)	(total mrad)	
Uptake only				
^{123}I (Iodide)	10–20	11	110–220	0.3–0.6
^{131}I (Iodide)	6	1100	6600	2.6
Scan				
$^{99\text{m}}\text{Tc}$ (pertechnetate)	5–10 mCi	0.20	1000–2000	60–120
^{123}I (Iodide)	100–400	11	1100–4400	3–12
^{131}I	30	1100	33,000	14

uptake and scan are completed in an hour, whereas most ^{123}I studies (scan and uptake) are obtained 5–6 hr after ^{123}I administration. Follow-up 24 hr ^{123}I uptake values can be necessary.

Both $^{99\text{m}}\text{Tc}$ and ^{123}I have proven to be excellent thyroid imaging agents, by Atkins et al. in 1973 (9) and Arnold and Pinsky in 1976 (10). Both of these early studies were made up of a large population of patients with normal thyroids. The quality and clarity of images are better with ^{123}I because $^{99\text{m}}\text{Tc}$ has higher neck background activity. It is widely believed that routine thyroid scans may be acceptably performed with $^{99\text{m}}\text{Tc}$ due to the lower radiopharmaceutical costs and time saved. A repeat scan with ^{123}I may be required when the palpable nodule is found to have normal uptake on a $^{99\text{m}}\text{Tc}$ thyroid scan.

Both $^{99\text{m}}\text{Tc}$ -pertechnetate and ^{123}I scans show most palpable nodules, including benign adenomas, cysts, and carcinomas, as hypofunctioning (cold nodule). However, since $^{99\text{m}}\text{Tc}$ is only trapped by the thyroid and not organified like iodine, some thyroid carcinomas have normal $^{99\text{m}}\text{Tc}$ uptake, but appear "cold" on ^{123}I scans (11,12). If the clinical objective is to rule out thyroid cancer, a ^{123}I scan should be ordered. Alternatively, a ^{123}I scan should follow if a palpable nodule has normal uptake on the initial $^{99\text{m}}\text{Tc}$ thyroid images.

The choice of a radiotracer for thyroid uptake studies is more complicated. If only a screening evaluation is desired, $^{99\text{m}}\text{Tc}$ imaging and uptake may be adequate and, in fact, can help in diagnosing an organification defect whether it is from drugs (e.g., PTU), acquired (e.g., thyroiditis), or congenital (e.g., enzymatic defects). Other applications mandate actual organified iodine uptake (e.g., calculation of a radioiodine therapy dose) and require an iodine tracer. This is discussed in greater detail below.

THYROID UPTAKE TESTS

The measurement of radioiodine thyroid uptake was one of the earliest clinically useful procedures in nuclear medicine. The procedure involves the administration of a tracer dose of ^{123}I or ^{131}I , followed by measurement by an external gamma detector of the percentage of dose present in the gland at a

particular time. The radioiodine uptake is a measure of the amount of the extrathyroidal pool of iodide taken up and retained within the gland. The uptake reflects different aspects of thyroid iodine metabolism depending upon the time interval chosen. Thyroid clearance of iodide from the extrathyroidal pool is usually measured soon after radioiodine administration, and corrections for the extrathyroidal neck radioactivity are essential. Normally, uptake measurement from 2 to 6 hr following the dose reflect both iodide trapping and organification of iodide within the gland. Late uptake values, typically 24 or 48 hr, are influenced by the rate of loss of iodine from the gland. In hyperthyroidism, this time scale shifts to shorter intervals. This is especially true in approximately 10% of hyperthyroid patients who may have lower 24-hr uptakes than typical 6-hr uptake values. Therefore, if only one measurement is performed at 24 hr, falsely low results may be obtained (13). For this reason, thyroid uptake measurements should be performed at more than one time, at 2–4 hr and at 24 hr, or at 6 hr and 24 hr. Alternatively, an early iodine uptake time point can be performed (4 or 6 hr) and if normal, the study is completed. An elevated value would require a delayed (24-hr) value to better delineate uptake. Normal values at specific times should be established by each department for their geographic area.

Radioiodine uptakes are useful in patients with hyperthyroidism in which ^{131}I therapy is indicated, and in patients with organification defects, as can be seen with congenital organification defect, chronic lymphocytic thyroiditis, and Hashimoto's thyroiditis. Since the thyroid uptake may not be elevated in elderly patients with Graves' disease, the uptake may be the key piece of data for an accurate diagnosis.

Uptake Methods

Before dose administration, the patient should be questioned concerning prior thyroid history, medications, and recent radiographic procedures. Medications containing iodine and radiographic procedures using contrast will expand the patient's iodide pool, which can result in a falsely low uptake. Thyroid medication containing T_4 and antithyroid drugs suppress uptake and must be discontinued for at least 4 wk and

TABLE 2. Factors Influencing Thyroidal Iodine Uptake

Increased uptake
Iodine deficiency
Pregnancy (normal)
Lithium
Rebound following suppression with thyroid hormone
Rebound following cessation of antithyroid drugs
Decreased uptake
Suppression by exogenous thyroid hormone
Renal failure or severe congestive heart failure
Excess iodine (including radiographic contrast agents and iodine-containing drugs)
Other drugs including thionamides and glucocorticoids

3–5 days, respectively, before performing a study. Although beyond the scope of this article, pure T₃ thyroid medication is often substituted for T₄ before a study for 3 wk then discontinued, as its shorter pharmacological serum T_{1/2} requires only 1 wk to be essentially cleared from the circulation. Table 2 gives a partial list of factors influencing the radioactive iodine uptake. Since the route of administration of the uptake dose is oral, the patient should be instructed not to eat solid food for several hours prior to dose administration. The presence of food may impede gastric emptying and the intestinal absorption of iodide. With the encapsulation of ¹²³I inconsistent results due to incomplete dissolution of the capsule resulting in variable absorption rates compared to liquid ¹³¹I have been documented (14,15). For this reason, it has been recommended by some to use a liquid dose. The same problem would be theoretically expected with ¹³¹I in capsule form. However, because the radiation exposure to the radiopharmacy technologist may be higher using liquid radioiodine, due to iodine's volatility, capsule administration is the preferred choice unless precluded by special circumstances or gastrointestinal problems.

A standard thyroid uptake probe consists of a 2-in sodium iodide crystal with a cylindrical straight-bore collimator connected to a pulse-height analyzer (PHA) and scaler. A well stabilized, high voltage power supply is essential to limit day-to-day variations. Frequent high voltage calibration during the day to monitor variations in high voltage, and proper window selection at an appropriate gain setting for the PHA are essential (16).

Prior to dose administration, the ¹²³I capsules are placed in a neck phantom, and with the thyroid probe positioned perpendicular to each capsule, they are counted for 1 min on ¹²³I settings. This count is then used as the dose standard for the particular patient. Some laboratories use a duplicate capsule that has been compared with the capsule given to the patient. If a duplicate dose standard is used it should be counted each time the patient undergoes an uptake measurement. If the dose capsule is used as the standard, a correction factor must be applied each time a measurement is made to correct

for physical decay. A constant depth of the standard within the neck phantom for each measurement must be maintained. Since the ¹²³I photon is 159 keV, correcting for attenuation by soft tissue absorption should be considered, especially in patients with extremely large goiters or heavy necks because of variable thyroid depths (17).

Nonthyroidal background measurements are best taken over the thigh by placing the patient in a chair with the neck extended and counting for 1 min. The probe is positioned vertically over one leg with the distance marker slightly above the patient's knee. Care must be taken not to include bladder activity. For the uptake measurement the patient is supine with the probe positioned a fixed distance above the neck, with the center line of the probe between the thyroid cartilage and the suprasternal notch. The positioning must be reproduced each time the patient returns for uptake measurements. An equally effective method of estimating this nonthyroidal background is the use of a lead thyroid shield placed over the patient's neck covering the thyroid. Then a background count is taken with the probe in the uptake position. The following equation is used to calculate the uptake:

$$\text{Uptake } \% = \frac{N - T}{(S \times D_t) - B} \times 100$$

- where N = patient neck counts per minute
 T = patient background counts per minute, either over the thigh or with a lead shield over the thyroid
 S = counts per minute of dose standard
 D_t = decay factor obtained from a chart accounting for the elapsed interval between the time that the dose is counted and the time that the radioactivity in the patient is counted (if applicable)
 B = room background in counts per minute

Uptake of Technetium-99m-Per technetate. Since the per technetate ion is trapped by the thyroid's iodide trapping mechanism, the use of ^{99m}Tc-per technetate uptake was developed as an alternative method to evaluate thyroid structure and to measure trapping. In normal thyroid glands, trapping parallels organifications, so ^{99m}Tc-per technetate trapping is a good screening test for trapping. Discordances between trapping values and thyroid function tests, for example, require further evaluation and possibly an iodine uptake study.

Typically, within 20–30 min following intravenous administration of 5 mCi of ^{99m}Tc-per technetate, maximum thyroid trapping of the per technetate is reached. Per technetate trapping can be measured in an analogous manner to radioiodine uptake by counting the dose to be injected, prior to injection, for use as the standard with decay corrections applied. A standard solution counted immediately after the uptake measurement of the patient can also be used. In our laboratory, the normal range of ^{99m}Tc uptake at 20 min is approximately 0.2% to 3.0%. Hyperthyroid patients show higher values and this can serve as a rapid screening test for Graves' disease. Many nuclear medicine departments incorporate a ^{99m}Tc uptake value with a ^{99m}Tc thyroid imaging evaluation for thyroid structure.

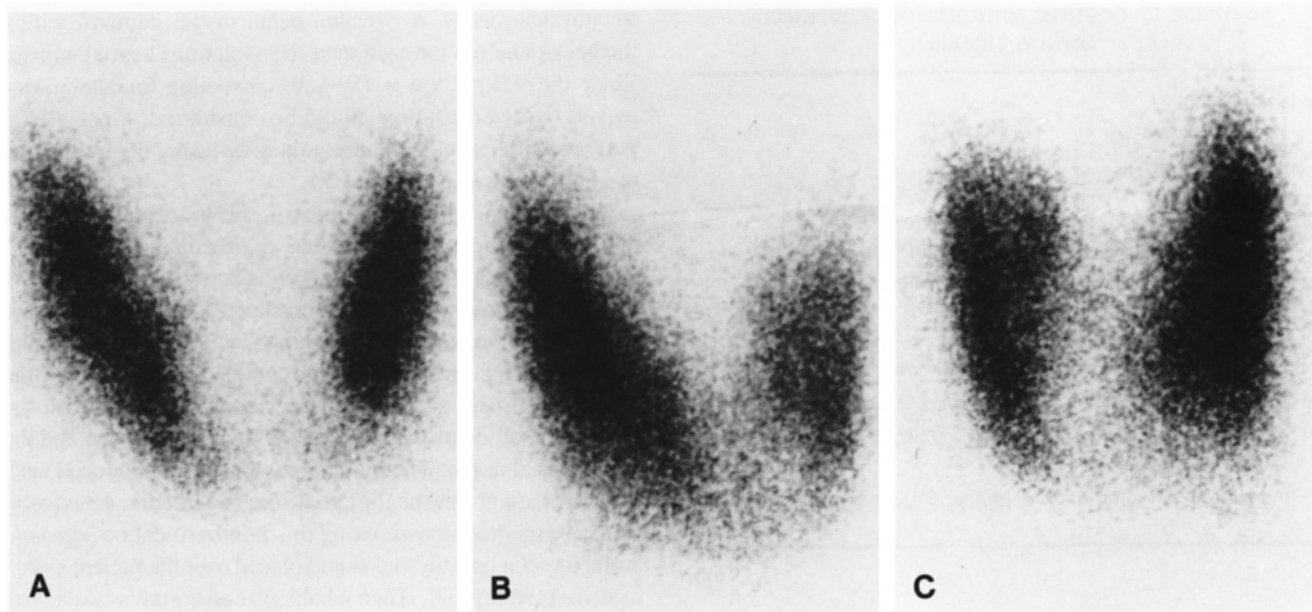


FIG. 2. A, anterior; B, right anterior oblique; and C, left anterior oblique views of a normal thyroid gland using ^{123}I .

Thyroid Imaging

The thyroid imaging study is performed to evaluate the anatomy and physiology of the thyroid gland. Current techniques permit visualization of lesions as small as 0.5 cm (18). The preferred instrumentation used is a gamma camera with a pinhole collimator. Twenty minutes after intravenous administration of 5 mCi of $^{99\text{m}}\text{Tc}$ -pertechnetate or 5–6 hr after oral administration of 400 μCi of ^{123}I , the patient lies supine under the camera with the neck hyperextended. The thyroid gland is centered using the persistence scope.

Although some laboratories obtain only an anterior view, we prefer four images, all of which are obtained with the pinhole collimator. The first image is calibrated for collimator distance to give 1:1 size representation on the film, so accurate thyroid measurement for size can be made. The distance between the face of the pinhole collimator and the patient's neck is 17 cm at our institution; however, this distance must be determined and validated by each nuclear medicine department. Next, markers are placed on the suprasternal notch and on the right lateral aspect of the neck followed by anterior, right, and left anterior oblique views to optimize structural detail. For these higher detail views the distance between the collimator and the patient's neck is decreased (usually to about 6 cm) so that the thyroid image nearly fills the field of view of the crystal, resulting in a magnified, slightly distorted gland appearance. Thyroid measurements are not valid in these views. To aid in identifying the palpable nodules, physicians should place markers as determined by physical exam to coincide with the palpable nodules. Various types of markers may be required depending on whether a nodule is hypo- or hyperfunctioning.

When ectopic thyroid tissue or substernal goiter is suspected, an anterior view of the superior mediastinum, with markers on suprasternal notch and midsternum or images of the ques-

tionable area, should be obtained. Iodine-123 or ^{131}I is preferred in this setting.

Normal Thyroid. The normal thyroid gland has a homogeneous uptake of tracer with well defined borders. Each lateral lobe is ellipsoidal in shape with lateral margins typically convex, although some borders are straighter. The isthmus is variable and typically not prominent in adults. A pyramidal lobe can be visualized in approximately one-fifth of normal patients but is seen more commonly in Graves' disease. Figure 2 shows a normal thyroid scan using $^{99\text{m}}\text{Tc}$ -pertechnetate and a pinhole collimator.

Normal variants include congenital absence of one lobe, sublingual thyroid, or substernal extension of the gland. Extra thyroidal tissue almost always fails to function in the presence of an intact normal functioning thyroid gland. If iodine uptake is demonstrated in the context of papillary or follicular thyroid carcinoma, this extra tissue is considered metastasis from the thyroid carcinoma. However, ectopic thyroid tissue can occur in nonmalignant settings. For these studies, ^{123}I is the preferred agent to evaluate for sublingual or lingual thyroid. Technetium-99m pertechnetate is not as optimal because of tracer kinetics, imaging protocols, and increased background activity in pertechnetate studies. Some investigators have stated substernal thyroid is best evaluated with ^{131}I because the higher energy will penetrate the sternum easily. However, ^{123}I is sometimes equivalent and enjoys better patient dosimetry and better imaging characteristics. Technetium-99m is not used because the intravascular activity in the heart may complicate the scan interpretation.

Thyroid Nodule. One of the most frequent indications for thyroid imaging is the evaluation of a palpable nodule or mass in the anterior neck. In the total evaluation of this problem, it is important to determine if the nodule is functioning and whether the nodule is solitary or multiple. If the nodule is

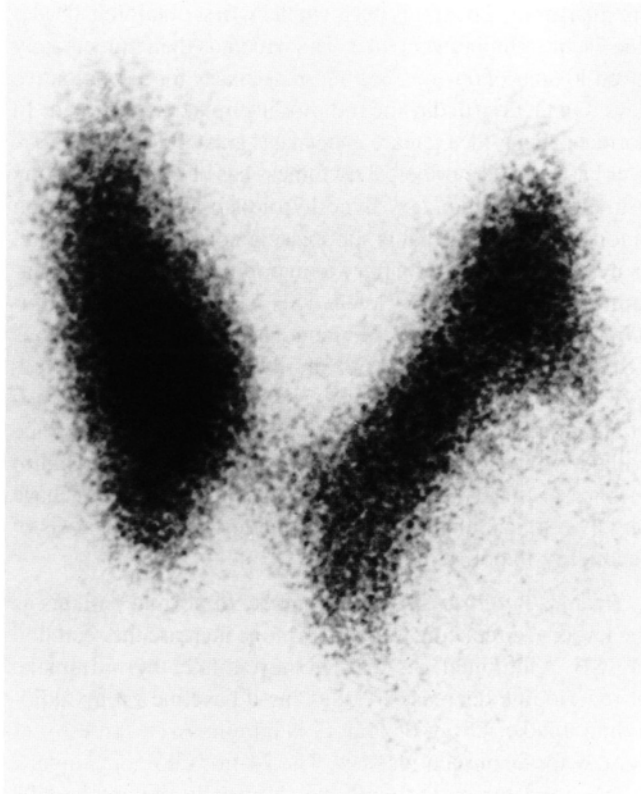


FIG. 3. Cold nodule seen on anterior view with ^{123}I , revealing decreased function (organification) in thyroxine synthesis. Needle biopsy revealed papillary carcinoma.

functioning the percentage dose uptake of $^{99\text{m}}\text{Tc}$ -pertechnetate or ^{123}I is required, and nodules that show decreased ^{123}I uptake indicate decreased function in the synthesis of thyroxine. The more common pathologic processes that show cold nodules include nonfunctioning adenoma, colloid nodule, and carcinoma. Less common causes of cold nodules are inflammatory conditions such as Hashimoto's thyroiditis in addition to non-

TABLE 3. Clinical Factors in Diagnosis of Thyroid Cancer

1.	Family history of thyroid medullary carcinoma or pheochromocytoma
2.	Age: < 20 or > 60 years
3.	Sex: males > females
4.	Childhood head and neck irradiation
5.	Rapidity of growth (usually over a period of weeks or months)
6.	Growth of nodule while on thyroid hormone suppression therapy
7.	Pain
8.	Compression symptoms: dysphagia, dysphonia, dyspnea
9.	Euthyroid clinical status
10.	Single rather than multiple nodules
11.	Fixation to surrounding tissues and hard consistency
12.	Lymphadenopathy

inflammatory causes such as cysts or hematomas.

When evaluating a thyroid scan where a single cold nodule is observed (Fig. 3) other factors must be considered. These include patient's age, sex, family history of thyroid cancer, and history of prior radiation to the head and neck. Although most solitary nodules are not carcinoma, the probability is sufficiently great in general (20%) (19) and in persons with a history of head and neck radiation (40%) (20) that thyroid carcinoma must be excluded. The above items (Table 3) influence the probability of a malignancy being present. If multiple nodules are present, the likelihood of carcinoma is decreased. If the thyroid nodule is warm or hot, indicating increased function, the probability of thyroid carcinoma is low. In the setting of multinodular goiter, a dominant or preferentially enlarging lesion becomes more suspicious for carcinoma. Fine needle biopsy aspiration has become a valuable adjunct in obtaining histologic confirmation (21).

Hot or warm (hyper- or efunctioning) nodules occur less frequently than cold lesions. Approximately 10% of abnormal scans are hot or warm nodules (22) and are generally regarded as benign. Some efunctioning (warm) nodules may actually represent hypofunctioning (cold) nodules with enough normal underlying or overlying thyroid tissue to blunt the hypofunctioning features. Benign hot nodules can be generalized into two types: autonomous adenoma and hypertrophic nodule (Fig. 4). Autonomous nodules are not under TSH control and cannot be suppressed by endogenous thyroid hormone such as T_3 . This is the rationale for a T_3 suppression test. Hypertrophy of the nodule is a TSH-mediated process. When the level of pituitary TSH rises due to defective production of thyroid hormone, areas of the thyroid capable of responding to TSH become hypertrophied, causing the relative appearance of a hyperfunctioning (hot) nodule on the thyroid scan.

Thyroid imaging can confirm the presence of goiter and allow accurate measurement. The study also allows the assessment of whether the gland enlargement is due to increased function or a compensatory goiter secondary to decreased function. Goiter with a diffuse increase in ^{123}I uptake and chemical hyperthyroidism is typical of Graves' disease.

In patients with thyroiditis or multinodular goiter, several irregular multiple cold lesions may appear in a slightly enlarged gland. The thyroid uptake usually is normal or slightly increased in patients with multinodular goiter and is usually decreased in thyroiditis.

Whole Body Metastatic Survey. If a subtotal or total thyroidectomy has been performed for thyroid cancer, the patient should be evaluated for metastatic thyroid carcinoma 4 to 6 wk after surgery (23). In the setting of a subtotal thyroidectomy considerable residual thyroid tissue remains, decreasing the sensitivity of this surgery. Therefore full ablation of thyroid provides the setting for the most optimal metastatic survey. The 4- to 6-wk waiting period allows for the clearance of endogenous T_4 and physiologic elevation of endogenous TSH levels. This TSH rise in turn stimulates ^{131}I uptake by the thyroid carcinoma enhancing its chance of detection. Serum TSH levels should be monitored until elevated. Levels exceeding $20 \mu\text{IU/ml}$ will usually ensure possible uptake by metastatic

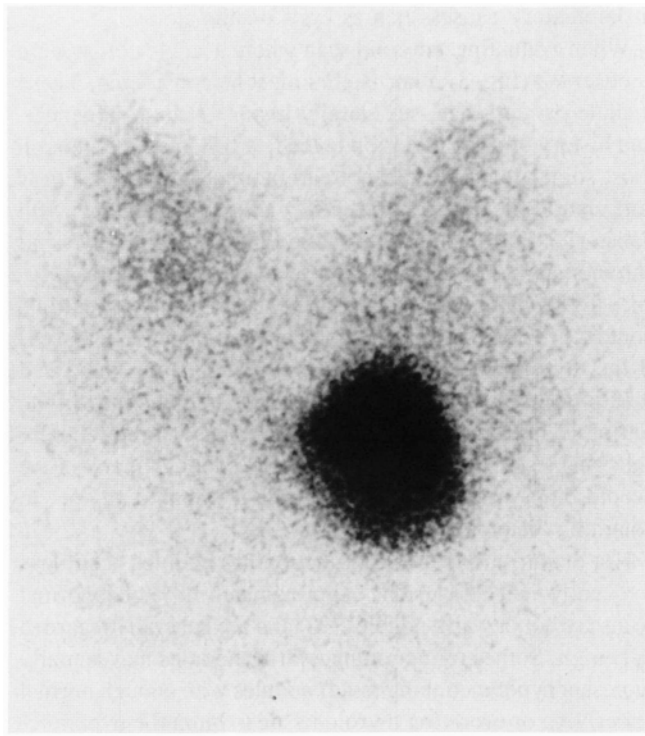


FIG. 4. Hot nodule seen on anterior view with ^{99m}Tc , which is usually considered benign.

lesion capable of utilizing iodide.

Three days after oral administration of 5 mCi ^{131}I -iodide the whole body survey is performed using a wide field of view scintillation camera with a high energy parallel hole collimator. Anterior and posterior images of the head and neck with a right lateral image of the skull and anterior and posterior image of the chest, abdomen, and pelvis are obtained. Areas of uptake outside the thyroid bed, exclusive of physiologic distribution in the gastrointestinal tract and urinary bladder, that appear during the whole body survey are strong indications of metastases. Diffuse lung activity or bone metastases, more frequently noted in the axial skeleton, will concentrate ^{131}I after thyroid ablation and are the typical sites of metastatic disease. If no functioning thyroid metastases are found, the patient is started on thyroid replacement therapy and the procedure is repeated in 1 yr, or earlier if clinical signs or symptoms develop. If areas of uptake are found, ^{131}I therapy is usually indicated.

Functional Thyroid Tests

The thyroid gland's ability to respond to stimulation or suppression measures the integrity of the gland's function and the regulating mechanisms that control it. These thyroid "stress tests" reveal the unique capability of nuclear medicine and the tracer concept to utilize physiologic parameters to add another dimension to thyroid diagnosis.

Thyroid Stimulating Hormone Stimulation Test. As discussed previously, TSH stimulates all of the thyroid enzymatic processes, from iodide trapping to hormone release. Exogenous administration of TSH can affect the thyroid gland at all of these levels. Most commonly, changes in thyroid uptake

are measured. The test is performed by first obtaining a baseline 24-hr radioiodine uptake. The patient is then immediately given 10 units of bovine TSH intramuscularly for 3 consecutive days. On the fourth day the radioiodine uptake is repeated. In normal patients the increase in uptake is greater than 20%–50% over baseline. The principal usefulness has been differentiating primary from secondary hypothyroidism and evaluating an autonomous nodule that is suppressing normal thyroid tissue. In hypothyroidism secondary to hypopituitarism or hypothalamic dysfunction, insufficient TSH is produced by the pituitary gland, but the thyroid gland can respond to exogenous TSH. In primary hypothyroidism, the thyroid gland is defective, and will not respond to exogenous TSH. In the presence of an autonomous nodule, suppressed normal thyroid tissue will be stimulated by exogenous TSH. Sensitive immunoradiometric serum TSH assays and TRH stimulation tests have largely replaced the TSH stimulation test in the diagnosis of secondary hypothyroidism.

Triiodothyronine Suppression Test. In normal patients as the levels of circulating thyroid hormone increase the secretion of TSH is inhibited. As the TSH levels fall, thyroid uptake of radioiodine decreases. Following a baseline 24-hr radioiodine uptake, 25 μg of oral T_3 is administered three times per day for 8 consecutive days. The 24-hr radioiodine uptake is then repeated on the ninth day. Normally the uptake falls more than 50% below the baseline value. In patients with borderline hyperthyroidism, the gland fails to suppress.

Perchlorate Washout Test. Although the perchlorate washout test presently is infrequently performed it was useful in studying congenital goiters and Hashimoto's thyroiditis. Perchlorate is trapped by the thyroid and displaces iodide ions that have not been organified. In organification defects, iodide that has been trapped by the thyroid will be discharged. Iodine-123 is administered orally to the patient and the uptake is measured 2 hr later. The patient is given 1 g of potassium perchlorate orally and the uptake is measured every 15 min for 90 min. Normally no change in uptake value should occur. If an organification defect is present, the uptake will fall at least 15% below the 2-hr value.

SPECT Imaging

Recently, radionuclide tomography using SPECT techniques have been developed for the imaging of the thyroid. Following the administration of ^{123}I or ^{99m}Tc , coronal, transaxial, and sagittal tomographic slices are generated after reconstruction. The tomography is able to demonstrate airway compression in patients with multinodular goiter and to further evaluate the tracer uptake of a warm nodule, which is defined as a palpable nodule with a normal ^{123}I pinhole image. In addition, the ability of measuring functional thyroid volume using SPECT provides a more accurate method to calculate the therapeutic dose of ^{131}I for radioiodine treatment of hyperthyroidism.

In conclusion, as nuclear medicine evolves in general, the strengths of thyroid imaging studies should remain as a reminder of the strengths and unique character of our specialty. Functional, metabolic, and physiologic measurements to monitor biochemical milieu are becoming increasingly recognized as

the bottom line in the evaluation of human health and disease. As a bonus we typically get adequate structural detail for a template of anatomical data; for example, imaging studies provide enough data to initially evaluate thyroid nodules. This information, along with the specificity provided by the functional portion of the study correlated with thyroid function tests and patient information, allows for an effective, safe, and accurate thyroid evaluation.

REFERENCES

1. Allen HC, Lobby RL, Cassen B. The scintillation counter in chemical studies of human thyroid physiology using I-131. *J Clin Endocrinol* 1951;11:492-511.
2. Cassen B, Curtis L, Reed C, et al. Instrumentation for I-131 use in medical studies. *Nucleonic* 1951;9:46-50.
3. Samuels HH. Molecular basis of thyroid hormone action. In: Oppenheimer JH, ed. *Thyroid today*, vol. 2. Deerfield, IL: Flint Laboratories, 1979:1-4.
4. Hays MT, Wesselosky B. Simultaneous measurement of thyroidal trapping ($^{99m}\text{TcO}_4^-$) and binding (^{131}I): Clinical and experimental studies in man. *J Nucl Med* 1973;14:785-792.
5. Rapoport B, DeGroot LJ. Current concepts of thyroid physiology. *Sem Nucl Med* 1971;1:265-286.
6. Ingbar SH. The testing tree. Deerfield, IL: Flint Laboratories, 1980: 13-16.
7. Volpe R. Treatment of Graves disease: An overview. In: Oppenheimer JH, ed. *Thyroid today*, vol. 1. Deerfield, IL: Flint Laboratories, 1977:1-6.
8. Saenger E. Evaluation of diseases of the thyroid gland with the in vivo use of radionuclides. *J Nucl Med* 1978;19:107-112.
9. Atkins HL, Klopper JF, Lambrecht RM, et al. A comparison of technetium-99m and iodine-123 for thyroid imaging. *Am J Roentgenol Radium Ther Nucl Med* 1973;117:195-201.
10. Arnold JE, Pinsky S. Comparison of Tc-99m and I-123 for thyroid imaging. *J Nucl Med* 1976;17:261-267.
11. Turner JW, Spencer RP. Thyroid carcinoma presenting as a pertechnetate "hot" nodule but without ^{131}I uptake. *J Nucl Med* 1976;17:22-25.
12. Usher MS, Arzoumanian AY. Thyroid nodule scans made with pertechnetate and iodine may give inconsistent results. *J Nucl Med* 1971;12:136-137.
13. Floyd JL, Rosen PR, Borchert RD, et al. Thyroid uptake and imaging with iodine-123 at 4-5 hours: Replacement of the 24-hour iodine-131 standard. *J Nucl Med* 1985;26:884-887.
14. Robertson JS, Verhasselt M, Wähler HW. Use of I-123 for thyroid uptake measurements and depression of I-131 thyroid uptakes by incomplete dissolution of capsule filler. *J Nucl Med* 1974;15:770-774.
15. Halpern S, Alazraki N, Littenberg R, et al. ^{131}I thyroid uptakes: Capsules versus liquid. *J Nucl Med* 1973;14:507-510.
16. Chervu S, Chervu LR, Goodwin PN, Blaufox MD. Thyroid uptake measurements with I-123: Problems and pitfalls. *J Nucl Med* 1982;23:667-670.
17. Martin PM, Rollo FD. Estimation of thyroid depth and correction of I-123 uptake measurements. *J Nucl Med* 1977;18:919-924.
18. Ryo UY, Arnold J, Coleman M, et al. Thyroid scintigram: Sensitivity with sodium pertechnetate Tc-99m and gamma camera with pinhole collimator. *JAMA* 1976;235:1235-1238.
19. Wesk EE, Vernon BM, Gonzalez JJ, et al. Cancer in thyroid nodules. *Arch Intern Med* 1984;144:474-476.
20. Refetoff S, Harrison J, Karanfilski BT, et al. Continuing occurrence of thyroid carcinoma after irradiation to the neck in infancy and childhood. *N Engl J Med* 1975;292:171-175.
21. Wong CA, Vickery AL, Maloof F. Needle biopsy of the thyroid. *Surg Gynecol Obstet* 1976;143:365-368.
22. Sisson JC, Bartold SP, Bartold SL. The dilemma of the solitary thyroid nodule: Resolution through decision analysis. *Semin Nucl Med* 1978;8:59-71.
23. Sheline GE, Miller ER. Studies with radioiodine: Evaluation of radioiodine treatment of carcinoma of the thyroid based on the experience at the University of California from 1938 to 1954. *Radiology* 1957;69:527-545.