

Prostate Cancer Metastases To Inguinal Lymph Nodes Detected By ¹¹C-Acetate PET/CTAC

Veer A Shah¹, MBChB; Allison Rixey²; Reginald Dusing¹, MD

1. Department of Radiology, University of Kansas Medical Center, Kansas City, KS
2. University of Kansas School of Medicine, Kansas City, KS

Corresponding author: Veer Shah, MBChB

Radiology Research, Department of Radiology, Mail Stop 4032

3901 Rainbow Boulevard

Kansas City, Kansas 66160-7234

Tel: 913-588-1004

Fax: 913-945-6687

Email: vshah@kumc.edu

Word count: 996

Running title: Prostate cancer inguinal metastases

Financial disclosure: none

Abstract

The inguinal lymph nodes are an unusual site of metastases for prostate adenocarcinoma. We present a case in which a 61-year-old man with biochemically recurrent prostate cancer underwent a ¹¹C-acetate Positron Emission Tomography (PET)/ Computed Tomography Attenuation Correction (CTAC) scan which demonstrated multiple foci of increased activity in the left inguinal, left iliac chain, and right inguinal regions. The CTAC scan also showed anterior wall thickening of the rectum. The imaging findings were suggestive of metastatic involvement of the rectum below the dentate line with subsequent spread to the inguinal lymph nodes.

Key Words: Prostate cancer, ¹¹C-acetate PET/CTAC, inguinal, lymph nodes

Introduction

The lymphatic spread of prostatic cancer rarely involves the inguinal region. In a patient presenting with inguinal lymphadenopathy, careful consideration of the routes of lymphatic drainage may allow the identification of sites of metastases. A variety of imaging modalities have been used with variable success to identify and localize sites of recurrence.

Case Report

A 61-year-old man with a history of prostate cancer (Gleason score 7) was found to have a prostate specific antigen (PSA) of 8.0ng/mL twenty months after brachytherapy treatment. A radionuclide bone scan was normal. A subsequent CT scan of the abdomen and pelvis noted multiple enlarged left inguinal lymph nodes, with the two largest measuring 2.3cm and 2cm respectively and several other mildly enlarged nodes measuring <1cm. Based on these results, the patient was then referred for a ¹¹C- acetate scan PET/CTAC scan.

The ^{11}C -acetate PET/CTAC scan demonstrated a focal concentration of increased metabolic activity in the posterior region of the prostate at the interface of the anterior wall of the rectum with a maximum Standard Uptake Value (SUV_{max}) of 3.92 (Figure A). Associated thickening of the anterior wall of the rectum was also demonstrated on CTAC imaging.

Extensive hypermetabolic lymphadenopathy was noted in the left inguinal region (Figure B) (SUV_{max} 2.28, 6.11, 4.51, 5.05) and external iliac chain (Figures C and D) (SUV_{max} 5.42, 2.28, and 3.39), with a smaller lymph node in the right inguinal area anterior to the femoral neurovascular bundle (SUV_{max} 1.91).

No osseous metastases were seen. The patient declined biopsy and chose to undergo intensity-modulated radiation therapy (IMRT) for salvage therapy.

Discussion

In the anal canal, the dentate line is the landmark for two different systems of lymphatic drainage; above, to the inferior mesenteric and internal iliac nodes, and below, to the superficial inguinal nodes (1). In prostate cancer, the external and internal iliac nodes, obturator, pre-sacral, and para-aortic lymph nodes are most often involved in the primary lymphatic spread (2). While inguinal lymphadenopathy is rare in prostate carcinoma, involvement of the rectum below the dentate line can be the source of metastatic disease to inguinal lymph nodes (3, 4).

Identification of the precise anatomic location of all involved lymph nodes is mandatory if salvage therapy with IMRT or surgery is to be considered. ^{11}C -acetate, like ^{11}C -choline and ^{18}F -choline, is a radioisotope that has been shown to have a strong positive correlation on PET/CTAC imaging with prostate cancer metastases. Once the patient has achieved a PSA threshold of 1.24ng/ml or a PSA doubling time of less than 6 months, the scan achieves a putative sensitivity and specificity of 86.6% and

65.8%, respectively (5). Currently, the best application of the ^{11}C -acetate PET/CTAC scan lies in the detection of prostate cancer metastasis after biochemical recurrence or in detecting extra-prostatic spread prior to surgery.

Other metabolic imaging such as FDG-PET/CTAC was not performed, as prostate cancer cells are not particularly glucose avid and studies have shown superiority of the ^{11}C -acetate PET/CTAC scan over FDG-PET/CTAC (5). Similarly, while multiparametric MRI has shown tremendous potential in detecting locally recurrent prostate cancer, further studies are needed to elucidate its usefulness in detecting lymph node metastases.

Conclusion

Prostate cancer metastases to the inguinal nodes are rare. This ^{11}C -acetate PET/CTAC scan effectively demonstrated prostate cancer recurrence with inguinal node uptake, suggestive of metastatic involvement of the rectum below the dentate line.

Disclosure: The authors report no conflict of interest.

Permissions: The institutional review board (IRB) approved this study and the requirement to obtain informed consent was waived.

References

1. Kaiser AM, Ortega AE. Anorectal anatomy. *Surgical Clinics of North America*. 2002;82:1125-1138.
2. Jackson AS, Sohaib SA, Staffurth JN, et al. Distribution of lymph nodes in men with prostatic adenocarcinoma and lymphadenopathy at presentation: a retrospective radiological review and implications for prostate and pelvis radiotherapy. *Clin Oncol (R Coll Radiol)*. 2006;18:109-116.
3. Huang E, Teh BS, Mody DR, Carpenter LS, Butler EB. Prostate adenocarcinoma presenting with inguinal lymphadenopathy. *Urology*. 2003;61:463.
4. Hamano T, Homma Y, Otsuki Y, Shimizu S, Kobayashi H, Kobayashi Y. Inguinal lymph node metastases are recognized with high frequency in rectal adenocarcinoma invading the dentate line. The histological features at the invasive front may predict inguinal lymph node metastasis. *Colorectal Disease*. 2010;12:e200-e205.
5. Dusing RW, Peng W, Lai SM, et al. Prostate-specific antigen and prostate-specific antigen velocity as threshold indicators in 11C-acetate PET/CTAC scanning for prostate cancer recurrence. *Clin Nucl Med*. 2014;39:777-783.

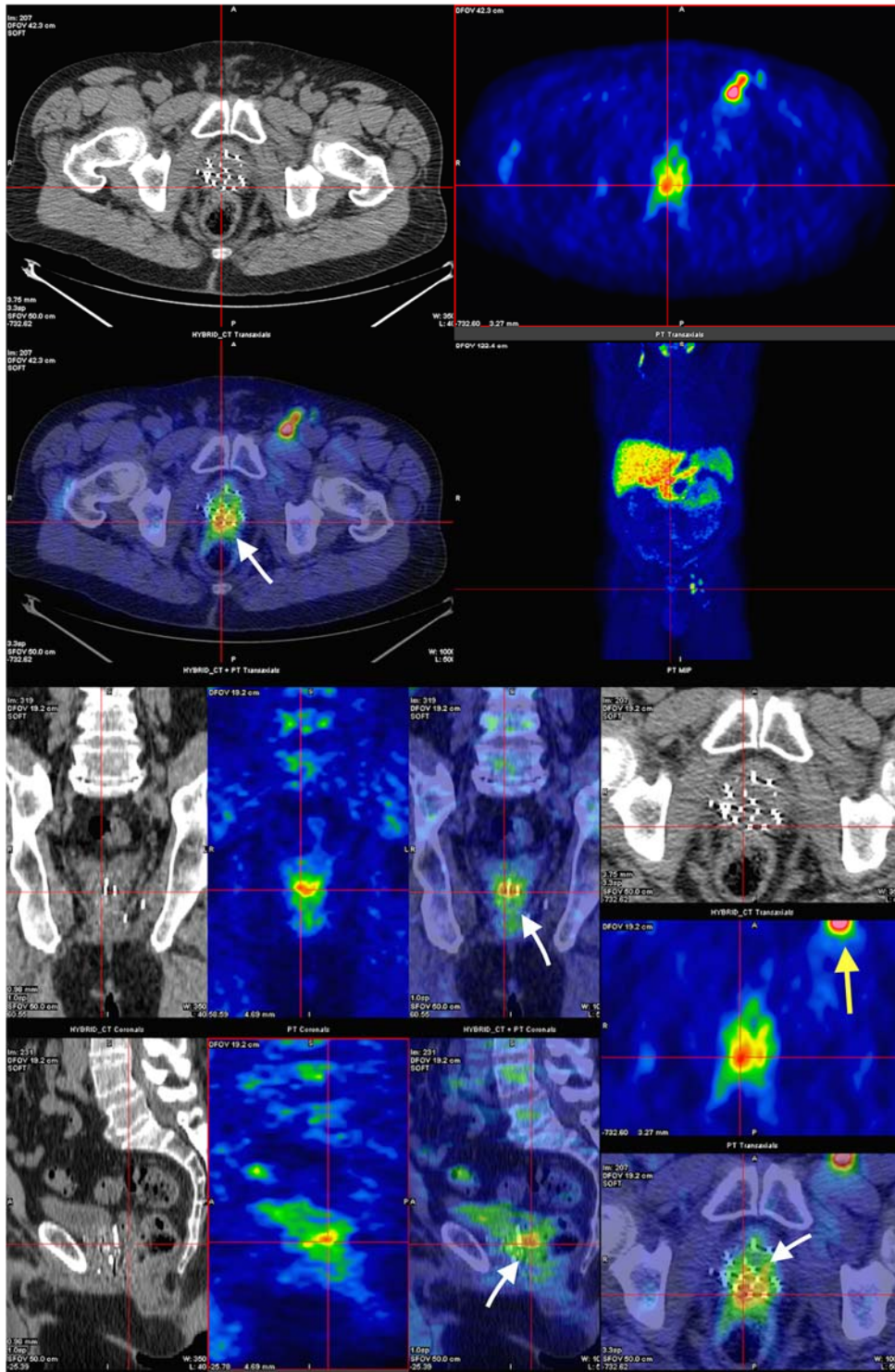


Figure 1: Fused PET/CTAC images demonstrating increased metabolic activity in the posterior region of the prostate at the interface of the anterior wall of the rectum (white arrows) (SUV_{max} 3.92), as well as spread to the left inguinal node (yellow arrow).

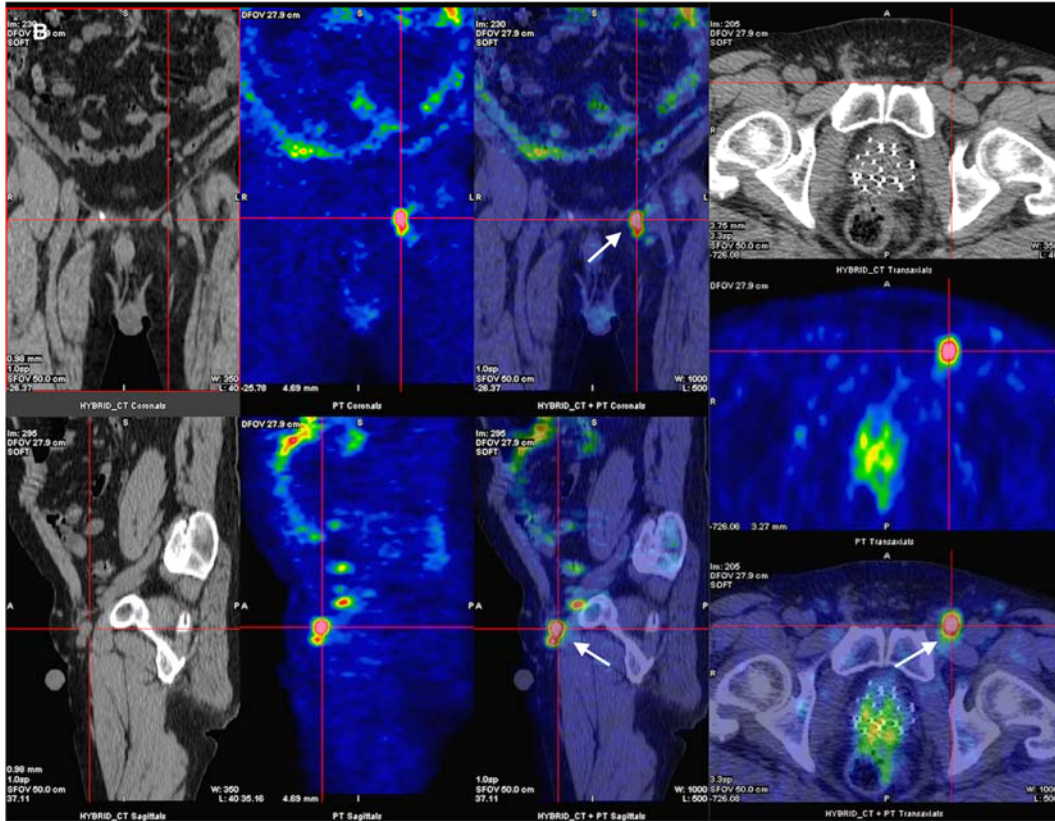


Figure 2: ^{11}C -acetate PET/CTAC fused images showing uptake within a large left inguinal lymph node (white arrows) (SUV_{max} 6.11).

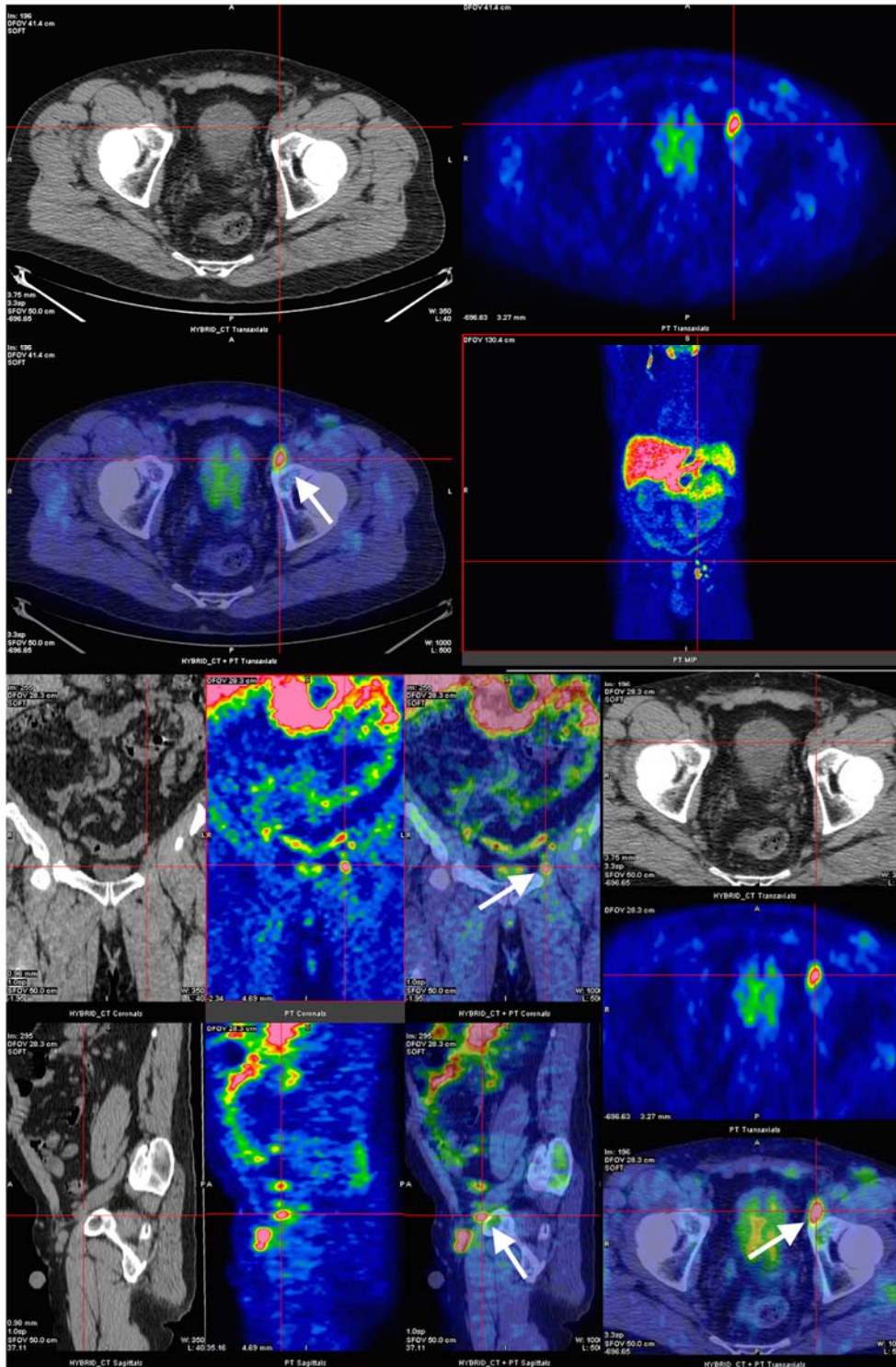


Figure 3: PET/CTAC images demonstrating increased ^{11}C -acetate uptake within the left external iliac chain in the node of Cloquet (white arrows) ($\text{SUV}_{\text{max}} 5.42$).

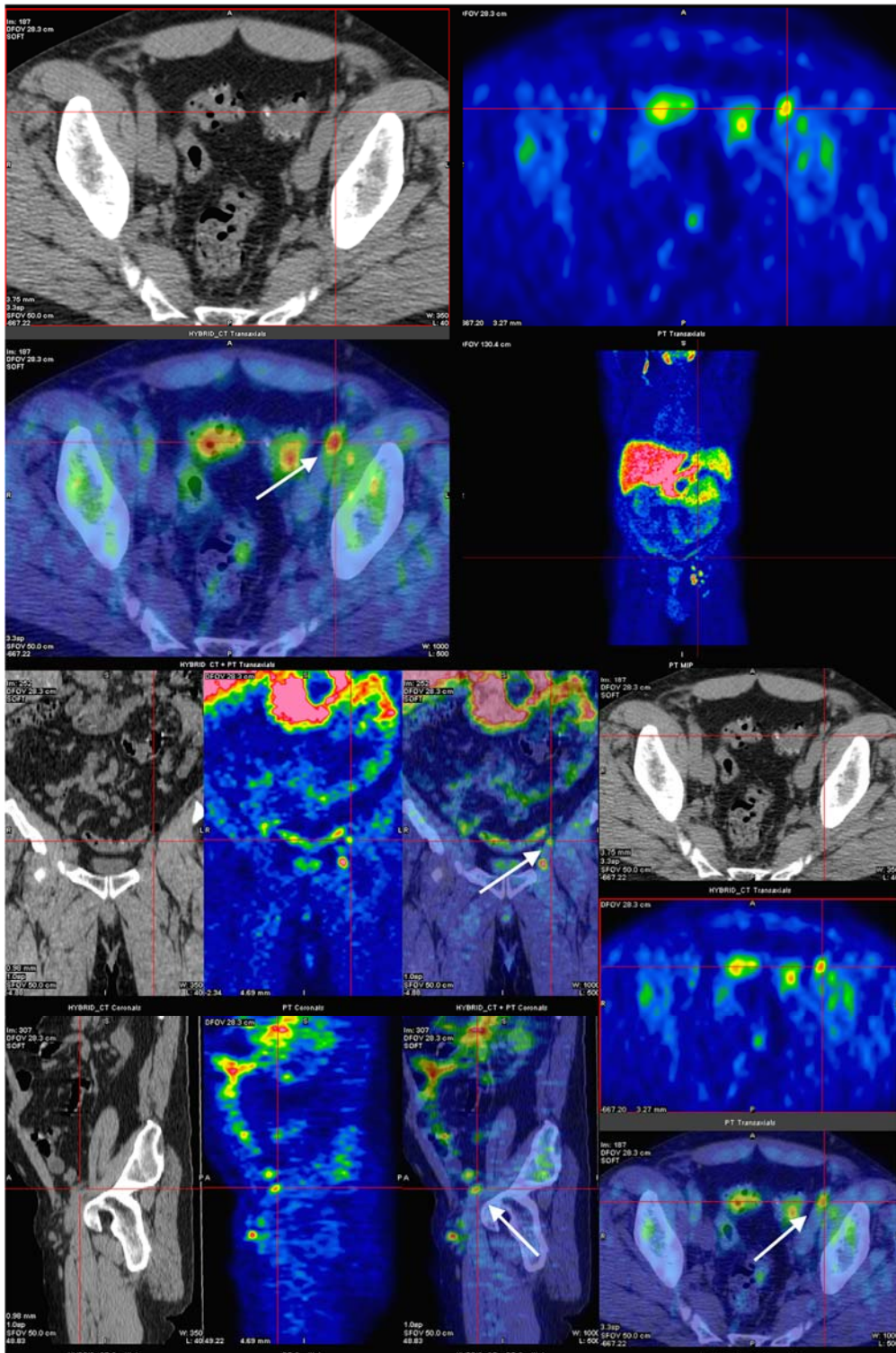


Figure 4: Fused PET/CTAC images showing ^{11}C -acetate uptake in a proximal left external iliac lymph node (white arrows) (SUV_{max} 3.39)