
Patient Preparation with Esomeprazole Is Comparable to Ranitidine in Meckel Diverticulum Scintigraphy

Tessa F. Ververs^{1,2}, Anne-Fleur H. Lobbezoo³, Monique G. Hobbelink¹, and Arthur J. Braat¹

¹Department of Radiology and Nuclear Medicine, University Medical Center Utrecht, Utrecht, The Netherlands; ²Department of Clinical Pharmacy, University Medical Centre Utrecht, Utrecht, The Netherlands; and ³Department of Clinical Pharmacy, St. Antonius Hospital, Nieuwegein, The Netherlands

To localize ectopic gastric mucosa in patients with unexplained gastrointestinal bleeding and diagnose a Meckel diverticulum, ^{99m}Tc-pertechnetate imaging is the standard procedure. H2 inhibitor pretreatment enhances the sensitivity of the scan by reducing washout of ^{99m}Tc activity from the intestinal lumen. We aim to provide evidence of the effectiveness of the proton pump inhibitor esomeprazole as an ideal substitute for ranitidine. **Methods:** The scan quality for 142 patients who underwent a Meckel scan during a period of 10 y was evaluated. The patients were pretreated with ranitidine orally or intravenously before a switch to a proton pump inhibitor after ranitidine was no longer available. Good scan quality was characterized by the absence of ^{99m}Tc-pertechnetate activity in the gastrointestinal lumen. The effectiveness of esomeprazole to diminish ^{99m}Tc-pertechnetate release was compared with the standard treatment using ranitidine. **Results:** Pretreatment with intravenous esomeprazole resulted in 48% of scans with no ^{99m}Tc-pertechnetate release, 17% with release either in the intestine or in the duodenum, and 35% with ^{99m}Tc-pertechnetate activity both in the intestine and in the duodenum. Evaluation of scans obtained after oral ranitidine and intravenous ranitidine showed absence of activity in both intestine and duodenum in 16% and 23% of the cases, respectively. The indicated time to administer esomeprazole before starting the scan procedure was 30 min, but a delay of 15 min did not negatively influence the scan quality. **Conclusion:** This study confirms that esomeprazole, 40 mg, when administered intravenously 30 min before a Meckel scan, enhances the scan quality comparably to ranitidine. This procedure can be incorporated into protocols.

Key Words: Meckel diverticulum; ^{99m}Tc-pertechnetate scintigraphy; ectopic gastric mucosa; esomeprazole; ranitidine

J Nucl Med Technol 2023; 51:211–214
DOI: 10.2967/jnmt.123.265558

Meckel diverticulum, the most common gastrointestinal congenital anomaly, is located predominantly in the lower part of the ileum. The condition occurs in 2%–3% of the population (1). Although most cases of Meckel diverticulum remain asymptomatic, 15% lead to complications

including hemorrhage, diverticulitis, obstruction, or perforation (1). Hemorrhage is usually caused by ulceration of the bowel wall because of ectopic gastric mucosa in the Meckel diverticulum and requires surgical intervention (1,2).

The specificity of a Meckel scan in detecting ectopic gastric mucosa is well established (95%–100%). Sensitivity may vary and depends partly on the amount of ectopic tissue (3). Excessive excretion of ^{99m}Tc-pertechnetate from the gastric mucosal tissue in the gastrointestinal lumen may interfere with the detection of ectopic gastric mucosa. H2 receptor antagonists increase the sensitivity of the Meckel scan by preventing release of ^{99m}Tc-pertechnetate from mucous cells in the stomach and ectopic gastric mucosa and therefore enhancing visualization of anomalies (3,4). It is thought that inhibition of acid secretion inhibits the release of radioactivity in the lumen as well, resulting in reduced risk of a false-negative or false-positive diagnosis (4). The use of H2 antagonists such as cimetidine and ranitidine was included in the Society of Nuclear Medicine and Molecular Imaging and European Association of Nuclear Medicine practice guideline for Meckel diverticulum scintigraphy (5).

However, this practice had to be altered when the supply of H2 antagonists ran dry after the recall of ranitidine from the European market in October 2019 in response to possible contamination with *N*-nitrosodimethylamine (6,7). With the assumption that any systemic antacid could serve as an alternative, proton pump inhibitors (PPIs) were proposed (5). Since esomeprazole is widely used in standard care for numerous conditions, we considered this PPI a practical alternative to ranitidine (8). Moreover its favorable pharmacokinetics and rapid onset after intravenous injection make esomeprazole an ideal candidate to replace H2 inhibitors (8–10). However, the effectiveness of esomeprazole in enhancing Meckel scan quality has yet to be established. The aim of this study was to determine whether esomeprazole is as effective as ranitidine when used in the prescan procedure.

MATERIALS AND METHODS

All patients who had a Meckel scan in our hospital between January 2012 and September 2022 were retrospectively included. Demographic data, including age at presentation and sex, were recorded, as well as details on prescan medication (time between administration of the antacid and the scan, interfering medication,

Received Feb. 10, 2023; revision accepted Apr. 20, 2023.
For correspondence or reprints, contact Tessa F. Ververs (f.f.ververs@umcutrecht.nl).
Published online Jun. 14, 2023.
COPYRIGHT © 2023 by the Society of Nuclear Medicine and Molecular Imaging.

TABLE 1
Premedication Protocols Adjusted to Age and Weight

Medication	1–12 y, <20 kg	1–12 y, >20 kg	>12 y	Administration before scan
Oral ranitidine oral	3 mg/kg	3 mg/kg; maximum, 150 mg	150 mg	Twice daily, starting 1 d before scan; last dose, morning before scan
Intravenous ranitidine	1 mg/kg	1 mg/kg; maximum, 50 mg	50 mg	15 min before scan
Intravenous esomeprazole	10 mg	20 mg	40 mg	30 min before scan

dose and administration route) and amount of ^{99m}Tc -pertechnetate activity. All positive Meckel scans were followed by surgical resection, and data on the histopathology results were collected. Patients were excluded if data on prescan medication were missing or if records mentioned antacid comedication during pretreatment. Patients who received esomeprazole in addition to PPI treatment were evaluated separately. The study was approved by the Medical Research Ethics Committee Utrecht, and the need for written informed consent was waived.

^{99m}Tc -pertechnetate scans were performed according to the practice guideline (5). The prescan procedure was performed with ranitidine twice a day orally 2 d before the scan (up till 2014), ranitidine intravenously 15 min before the scan (2014–2019), or esomeprazole intravenously 30 min before the scan (2019 till the present) (Table 1). The oral dose, 3 mg/kg, in our protocol originated from Dutch Society of Nuclear Medicine national guidelines for scintigraphy of ectopic gastric mucosa. Patients were not allowed to eat or drink 4 h before the scan. Barium contrast imaging or colonoscopy was deferred 3 d before the Meckel scan. ^{99m}Tc -pertechnetate, 20–200 MBq, was administered intravenously according to the European Association of Nuclear Medicine pediatric dosage card 2016 (11). Patients were positioned supine with the abdomen to the symphysis in the field of view. Dynamic anterior and posterior abdominal images were obtained during 45 min, as 90 frames of 30 s each. Additional static images were obtained after voiding to detect activity in a Meckel diverticulum obscured by the bladder (2 min/image). If it was difficult to distinguish activity in the ureter from a Meckel diverticulum, furosemide could be administered. A SPECT/CT scan could be added at the discretion of the nuclear medicine physician on call, to specify the anatomic localization of a Meckel diverticulum.

Scan quality was independently assessed by 2 experienced nuclear medicine physicians (each with >10 y of experience) masked to the patient's medical information. The scans were scored according to intestinal activity visualization (absence, activity in the duodenum, or activity in the intestine). The quality was considered good if no

^{99m}Tc -pertechnetate activity was seen in either the duodenal or the intestinal lumen. Interobserver agreement was calculated using the κ -score. Discrepancies between readers were highlighted, and a final score was defined during a consensus reading.

The scan quality after esomeprazole prescan treatment was compared with that after oral or intravenous ranitidine. Enhanced scan quality was reported as the absence of activity in the lumen of the intestine and duodenum. To analyze the difference in scan quality between the esomeprazole pretreated group and the 2 ranitidine groups, the χ^2 test was used, with a *P* value of less than 0.05 being considered a significant difference.

RESULTS

Between January 2012 and September 2022, 183 patients had a Meckel scan. Scans containing missing data regarding the prescan procedure were excluded (*n* = 19), as were cases for which—besides ranitidine—antacids such as PPIs were coadministered (*n* = 18). Scans from patients who received esomeprazole in addition to an oral PPI regimen were evaluated separately (*n* = 4).

Of the 142 included patients, age varied between 0.5 and 51 y (mean, 11 y); 51% were male (*n* = 72), and 49% were female (*n* = 70). Unexplained abdominal pain, lower-intestine hemorrhage, or both were indications for admission. Ranitidine as a pretreatment procedure had been received by 117 patients. Nineteen of these received a dosage of 3 mg/kg or 150 mg orally 2 times daily starting 1 d before the scan. The other 98 received 1 mg/kg or 50 mg intravenously 15 min before the scan. Twenty-five patients were pretreated with a PPI, and 23 patients were treated with 10–40 mg of esomeprazole intravenously 30 min before the scan. Two patients who were on pantoprazole did not receive additional pretreatment. Four patients received esomeprazole, 10–40 mg intravenously, in addition to

TABLE 2
Meckel Scan Quality After Antacid Pretreatment

Observed ^{99m}Tc -pertechnetate release	Oral ranitidine, 18–150 mg, <i>n</i> = 19	Intravenous ranitidine*, 5–62 mg, <i>n</i> = 98	Intravenous esomeprazole*, 10–40 mg, <i>n</i> = 23
Absent in duodenal and intestinal lumen	3	23	11
Activity in duodenal or intestinal lumen	3	13	4
Activity in both duodenal and intestinal lumen	13	62	8

*Esomeprazole resulted in significantly better scan quality than intravenous ranitidine (*P* = 0.034).

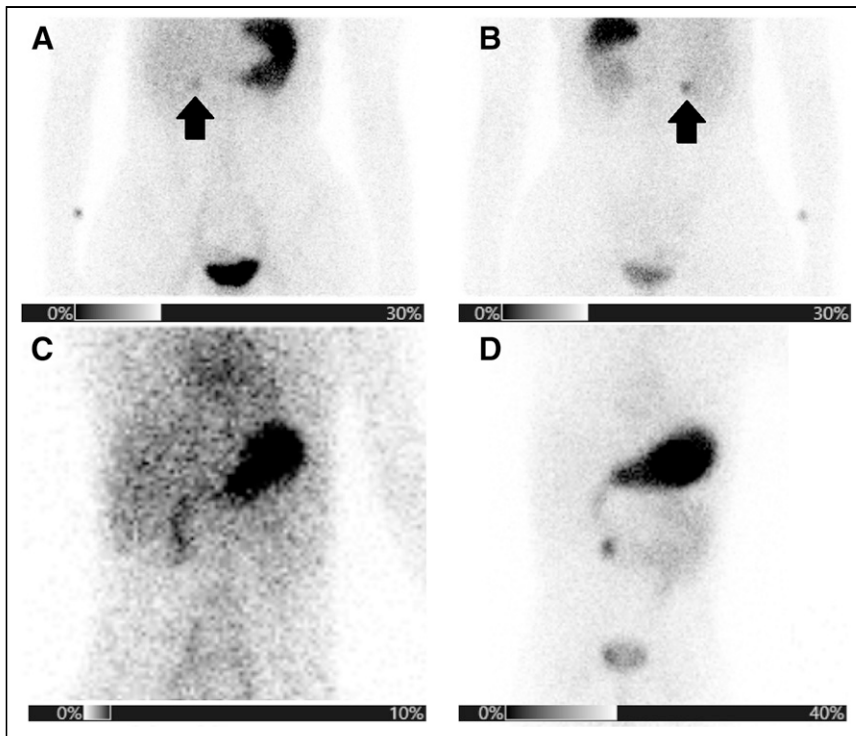


FIGURE 1. Examples of static images 30 min after injection. (A) Normal Meckel scan with adequate inhibition (arrow) of ^{99m}Tc excretion. (B) The only unexpected hot spot (arrow) in abdomen was stasis of urine in prominent renal pelvis, as confirmed on posterior static image. (C) Accumulation of ^{99m}Tc in gastric mucosa and minor excretion in duodenum. (D) Clear luminal activity in both duodenum and intestine.

oral omeprazole 20–40 mg 1–2 daily or esomeprazole 20–40 mg 1–2 daily.

Each scan was assessed for the absence or presence of activity in the duodenal lumen, in the lumen of the intestine, or both (Table 2). Interobserver agreement was 92%, with a κ of 0.83 for the assessment of intestinal ^{99m}Tc release and 0.85 for the estimation of activity in the duodenum.

After oral administration of ranitidine (18–150 mg twice daily), starting the day before the scan and ending with the last dose on the morning before the scan, ^{99m}Tc -pertechnetate release was absent in 3 of 19 (16%) patients, whereas 13 (68%) scans showed activity in both the duodenal and the intestinal lumen.

After patient preparation using intravenous ranitidine, 23 of 98 (23%) scans showed no released activity and 62 (63%) showed ^{99m}Tc activity in both the duodenum and the intestine.

Eleven of the 23 scans (48%) obtained after intravenous esomeprazole showed no activity in the intestinal lumen, and 8 scans (35%) showed activity in both the duodenal and the intestinal lumen (Fig. 1). Absence of activity was seen significantly more often after intravenous esomeprazole premedication than after intravenous ranitidine ($P = 0.034$). When absence of activity in the duodenal and intestinal lumen was compared with activity in the duodenal or intestinal lumen, esomeprazole significantly more often showed absence

of background noise caused by ^{99m}Tc -pertechnetate excretion than did oral ranitidine ($P = 0.014$) or intravenous ranitidine ($P = 0.019$).

The scans of 2 patients who received solely pantoprazole as part of their standard-care treatment (without additional intravenous esomeprazole) showed activity in both the duodenum and the intestine. No luminal ^{99m}Tc activity was observed in any of the 4 patients who received esomeprazole in addition to their standard-care PPI treatment.

The time lapse between esomeprazole administration and scan onset was recorded for 20 patients. Most frequently, pretreatment was administered 30 min before the start of scanning (48%). In another 6 patients (26%), scanning started within 45 min before administration of esomeprazole. Figure 2 shows ^{99m}Tc activity in the duodenal or intestinal lumen after esomeprazole administration in relation to the time between administration and the start of the scan. The scans of patients who were treated outside the time window of 30–45 min showed ^{99m}Tc -pertechnetate excretion in the duodenum, intestine, or both. In 9% ($n = 13$) of the patients, a Meckel diverticulum was detected. In all 13 patients, pathology confirmed the presence of ectopic gastric tissue.

DISCUSSION

After H2 blockers were recalled from the market in 2019, pretreatment with intravenous esomeprazole was implemented in our hospital because of its favorable pharmacokinetics, short time of onset, and well-established efficiency and safety in

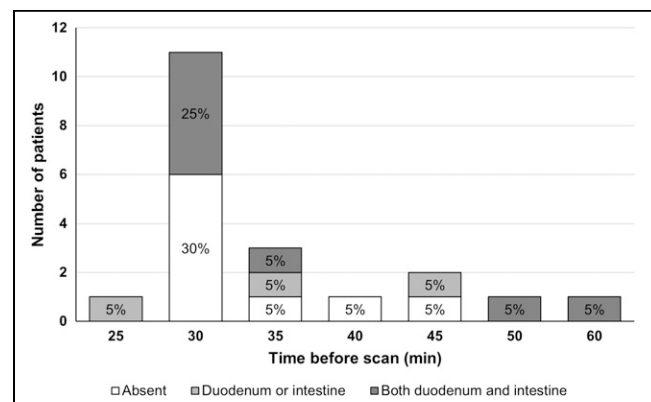


FIGURE 2. Absence of ^{99m}Tc activity release, activity detected in duodenal or intestinal lumen or both during Meckel scan, and time between esomeprazole administration and start of scan.

children (8). Our study covering 10 y of Meckel scans showed that neither ranitidine nor esomeprazole could prevent all cases of ^{99m}Tc -pertechnetate release but that esomeprazole better suppressed activity release in the duodenum and the intestine (48% vs. 23%; $P = 0.034$). Interobserver agreement was excellent. The difference in performance between the H2 blocker and the PPIs can be explained by ranitidine's lower potency as far as gastric acid inhibition is concerned (12,13). The effect of oral PPI pretreatment could not be evaluated since only one patient could be included. Moreover, an oral regimen 24–48 h before the scan may give rise to large variations, including interpatient differences in time between last administration of medication and start of scan, as well as mal-absorption or low compliance, which can be expected in small children whose caretakers are responsible for administering oral medication. Intravenous administration of esomeprazole in patients who already require an intravenous cannula for ^{99m}Tc -pertechnetate is not considered a major intervention.

The fixed time of 30 min before esomeprazole administration was chosen on theoretic grounds and available pharmacokinetic data, but our results indicate that 30–45 min may be more practical. Our findings did not support a time exceeding 50 or 60 min, nor did we find evidence that starting the scan earlier than 30 min after PPI administration will lead to a scan of sufficient quality.

The prevalence of Meckel diverticulum in our population (9%) is consistent with earlier findings with a corresponding specificity of 100% in diagnosing ectopic gastric tissue (1,14).

Because of the unavailability of ranitidine, a head-to-head study design was not opportune. Thus, the next best design was a retrospective comparative study using documented data in which scans were simultaneously reassessed by 2 independent nuclear medicine physicians. Whether an oral regimen of omeprazole or pantoprazole medication would enhance the scan quality to a comparable extent cannot be concluded from our data ($n = 2$) or from the 4 patients who received intravenous esomeprazole premedication in addition to an oral PPI. Nevertheless, until more data are available, we recommend intravenous esomeprazole premedication 30–45 min before image acquisition along with antacid comedication, as adherence to any oral regimen is difficult to confirm and, moreover, no adverse effects are expected of a 1-time doubled dose of PPI (8).

CONCLUSION

Intravenous esomeprazole pretreatment outperforms ranitidine in inhibiting gastrointestinal release of ^{99m}Tc -pertechnetate during Meckel diverticulum scintigraphy. Additionally, intravenous administration of esomeprazole holds several advantages over oral administration, such as a fast onset of effect and applicability in small children.

DISCLOSURE

No potential conflict of interest relevant to this article was reported.

KEY POINTS

QUESTION: Is pretreatment using a PPI as effective as ranitidine in inhibiting gastrointestinal ^{99m}Tc -pertechnetate release in Meckel scan scintigraphy?

PERTINENT FINDINGS: Esomeprazole was found to suppress ^{99m}Tc -pertechnetate excretion comparably to ranitidine. The scan quality was significantly more often better using esomeprazole than ranitidine.

IMPLICATIONS FOR PATIENT CARE: The current findings will enable clinicians to replace—on the basis of scientific findings rather than theoretic assumptions—intravenous esomeprazole, 30–45 min before the scan, with ranitidine in patient preparation protocols.

REFERENCES

1. Irvine I, Doherty A, Hayes R. Bleeding Meckel's diverticulum: a study of the accuracy of pertechnetate scintigraphy as a diagnostic tool. *Eur J Radiol.* 2017;96:27–30.
2. Farrell MB, Zimmerman J. Meckel's diverticulum imaging. *J Nucl Med Technol.* 2020;48:210–213.
3. Rerksupphol S, Hutson JM, Oliver MR. Ranitidine-enhanced ^{99m}Tc pertechnetate imaging in children improves the sensitivity of identifying heterotopic gastric mucosa in Meckel's diverticulum. *Pediatr Surg Int.* 2004;20:323–325.
4. Diamond RH, Rothstein RD, Alavi A. The role of cimetidine-enhanced technetium- 99m -pertechnetate imaging for visualizing Meckel's diverticulum. *J Nucl Med.* 1991;32:1422–1424.
5. Spottswood SE, Pfluger T, Bartold SP, et al. SNMMI and EANM practice guideline for Meckel diverticulum scintigraphy 2.0. *J Nucl Med Technol.* 2014;42:163–169.
6. Aschenbrenner DS. Ranitidine withdrawn from the market. *Am J Nurs.* 2020;120:23.
7. White CM. Understanding and preventing (N-nitrosodimethylamine) NDMA contamination of medications. *Ann Pharmacother.* 2020;54:611–614.
8. Ward RM, Kearns GL. Proton pump inhibitors in pediatrics: mechanism of action, pharmacokinetics, pharmacogenetics, and pharmacodynamics. *Paediatr Drugs.* 2013;15:119–131.
9. Metz DC, Fulda GJ, Olsen KM, Monyak JT, Simonson SG, Sostek MB. Intravenous esomeprazole pharmacodynamics in critically ill patients. *Curr Med Res Opin.* 2010;26:1141–1148.
10. Wilder-Smith C, Röhss K, Bondarov P, et al. Intravenous esomeprazole 40mg is effective for the control of intragastric acid levels whether given as a 3-minute injection or a 30-minute infusion. *Clin Drug Investig.* 2005;25:517–525.
11. Lassmann M, Treves ST. Paediatric radiopharmaceutical administration: harmonization of the 2007 EANM paediatric dosage card (version 1.5.2008) and the 2010 North American consensus guidelines. *Eur J Nucl Med Mol Imaging.* 2014;41:1036–1041.
12. Ruth M, Enbom H, Lundell L, Lönnroth H, Sandberg N, Sandmark S. The effect of omeprazole or ranitidine treatment on 24-hour esophageal acidity in patients with reflux esophagitis. *Scand J Gastroenterol.* 1988;23:1141–1146.
13. Hirschowitz BI, Keeling D, Lewin M, et al. Pharmacological aspects of acid secretion. *Dig Dis Sci.* 1995;40(suppl):3S–23S.
14. Jaramillo C, Jensen MK, McClain A, Stoddard G, Barnhart D, Ermarth AK. Clinical diagnostic predictive score for Meckel diverticulum. *J Pediatr Surg.* 2021;56:1673–1677.